

Baló's concentric sclerosis presenting as a stroke-like syndrome

Ellen M Mowry, John H Woo and Beau M Ances*

SUMMARY

Background A 37-year-old woman without important previous medical history presented to an emergency room with acute onset of left-sided weakness and numbness. Examination revealed left-sided hemiparesis (in the arm greater than in the leg) and hypoesthesia.

Investigations Routine laboratory testing, lumbar puncture, dynamic susceptibility contrast perfusion study, longitudinal brain MRI, and magnetic resonance spectroscopy were performed.

Diagnosis Baló's concentric sclerosis.

Management Intravenous methylprednisolone followed by oral steroid taper.

KEYWORDS Baló's concentric sclerosis, magnetic resonance spectroscopy, MRI, multiple sclerosis

CME

Vanderbilt Continuing Medical Education online

This article offers the opportunity to earn one Category 1 credit toward the AMA Physician's Recognition Award.

THE CASE

A 37-year-old woman with a previous medical history of migraine presented to the emergency room of a community hospital with acute onset of left-sided weakness and numbness. The patient did not complain of fever, chills, night sweats, or changes in bowel patterns preceding the onset of this illness. The examination was notable for considerable left-sided hemiparesis affecting the arm (severity 0 out of 5 on the Medical Research Council [MRC] scale)¹ more than the leg (2 out of 5 on the MRC scale), as well as left-sided hypoesthesia. The patient was admitted with the presumptive diagnosis of an ischemic stroke. Brain MRI obtained 3 days later demonstrated a circular area of abnormal signal intensity in the white matter adjacent to the right lateral ventricle on both T2-weighted and fluid-attenuated inversion recovery (FLAIR) images (Figure 1A,B). No meaningful mass effect was observed, but faint hyperintensities were seen both before and after administration of contrast (Figure 1C). Diffusion-weighted imaging, performed in three orthogonal directions, and reconstructed trace images, showed circular rings of hyperintensity, similar to the T2-weighted images. Apparent diffusion coefficient (ADC) maps generated off line demonstrated a donut-shaped zone of slow diffusion around a central nidus of facilitated diffusion. A trans-thoracic echocardiogram was normal. The possibility that the lesion could be a metastasis led to a CT scan of the abdomen and pelvis being performed to rule out a primary neoplasm. The CT scan was normal. The following laboratory tests had normal results: Lyme serology; HIV; lupus anticoagulant; Sjögren's antibodies; homocysteine; anti-scleroderma 70, anti-Smith, anti-Jo-1, and anticardiolipin antibodies; erythrocyte sedimentation rate; and blood cultures.

EM Mowry is a Neurology Resident in the Department of Neurology and JH Woo is an Assistant Professor in the Department of Radiology, both at the University of Pennsylvania, Philadelphia, PA, and BM Ances is a Clinical Instructor in the Departments of Neuroscience and Radiology and a NeuroAIDS Fellow at the University of California San Diego, San Diego, CA, USA.

Correspondence

*HIV Neurobehavioral Research Center, 150 West Washington Street, Second Floor, San Diego, CA 92103, USA
bances@ucsd.edu

Received 22 January 2007 Accepted 23 March 2007

www.nature.com/clinicalpractice
doi:10.1038/ncpneuro0522

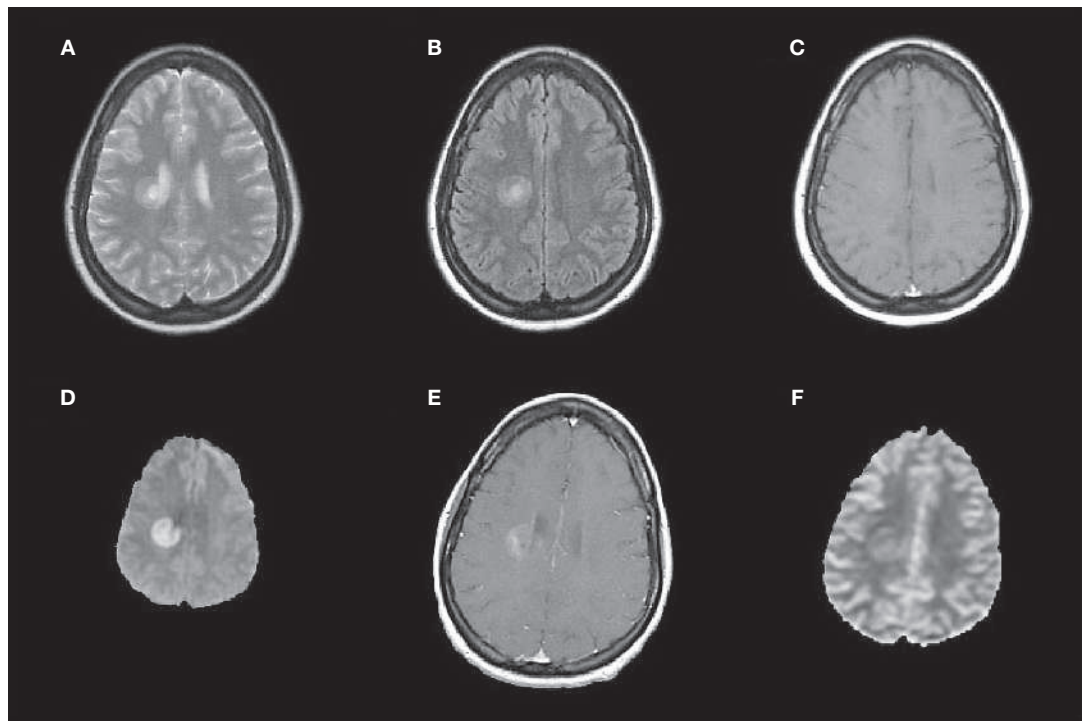


Figure 1 MRI scan of a patient with Baló's concentric sclerosis. (**A–C**) Three days after onset of symptoms. (A) T2-weighted image (TR/TE=4,000/90 ms) and (B) fluid-attenuated inversion recovery image (TR/TE/TI=9,000/105/2,300 ms) show a right periventricular lesion with concentric bands of variable hyperintensity. (C) T1-weighted image (TR/TE=650/15 ms) after administration of intravenous contrast shows subtle hyperintensity without marked enhancement. (**D–F**) Twelve days after onset of symptoms. (D) Diffusion-weighted image ($b = 1,000 \text{ s/mm}^2$) shows restricted diffusion in a concentric band surrounding a central nidus of facilitated diffusion. (E) Post-contrast T1-weighted image (TR/TE=567/20 ms) shows faint, patchy enhancement. (F) Cerebral blood volume map (spin-echo echo-planar technique) shows the following four distinct zones of regional perfusion: a central hyperintensity, surrounded by isointensity, surrounded by another zone of hyperintensity, then an outer zone of hypointensity. Abbreviations: *b*, diffusion gradient strength; TE, echo time; TI, inversion time; TR, repetition time.

Cytomegalovirus antibodies and IgG antibodies to Epstein–Barr virus were present, indicating previous exposure. Lumbar puncture revealed no red blood cells per mm^3 , one white blood cell per mm^3 ($1 \times 10^6/\text{l}$; normal range 0–5 cells per mm^3 [$1\text{--}5 \times 10^6/\text{l}$]), glucose 132 mg/dl (7.3 mmol/l), and protein 37 mg/dl (0.37 g/l; normal range 15–45 mg/dl [$0.15\text{--}0.45 \text{ g/l}$]). Myelin basic protein levels were elevated at 9 ng/ml (normal range 0–4 ng/ml), but IgG synthesis rate was normal and oligoclonal bands were absent. The patient was started on high-dose intravenous methylprednisolone, because of the suspicion of an inflammatory process, but had only minimal improvement; she was transferred to a tertiary care center 12 days after the onset of symptoms for additional evaluation and management.

On examination at the time of transfer, the patient had 0 out of 5 strength in the left upper

extremity and 2 out of 5 strength in the left lower extremity (both on MRC scale). A repeat brain MRI scan performed approximately 2 weeks after the onset of symptoms revealed few changes in the right periventricular lesion, with concentric rings of hyperintensity observed on both T2-weighted and FLAIR imaging. Diffusion-weighted images and ADC maps were both similar to previous studies, with a band of slow diffusion surrounding a central nidus of facilitated diffusion (Figure 1D). A post-contrast T1-weighted image showed patchy enhancement (Figure 1E). A dynamic susceptibility contrast perfusion study demonstrated increased cerebral blood volume (CBV) within the central nidus as well as near the periphery of the lesion, with relatively normal CBV in the corresponding band of slow diffusion. A vague area of reduced CBV could be discerned in a ring immediately outside

of the lesion (Figure 1F). Single-voxel magnetic resonance spectroscopy (MRS) showed a normal choline peak, a decreased *N*-acetylaspartate (NAA) peak (reflective of neuronal loss), and an elevated lactate doublet peak (consistent with impaired aerobic metabolism) within the lesion (Figure 2A), compared with a corresponding region within the contralateral hemisphere (Figure 2B). Visual evoked potentials were normal. The presentation and neuroimaging findings were most consistent with a diagnosis of Baló's concentric sclerosis (BCS). Steroid treatment was continued, and the patient experienced an improvement in her symptoms during the next few days. Approximately 2.5 weeks after her initial presentation, she was discharged for rehabilitation on an oral steroid taper treatment regimen.

The patient showed a considerable improvement in her deficits at a follow-up visit 3 weeks after the onset of symptoms, with 3 out of 5 proximal and 1 out of 5 distal left upper extremity strength (MRC scale). The left lower extremity had 3 out of 5 proximal strength, with 2 out of 5 dorsiflexion and 4 out of 5 plantarflexion (MRC scale). The patient completed a steroid taper regimen and had repeat neuroimaging approximately 3 months after her initial presentation. MRI of the cervical and thoracic spine was normal. On brain MRI, the T2-weighted image showed interval evolution of the periventricular lesion, with disorganization of the concentric ring appearance and a new area of edema surrounding the original lesion (Figure 3A). The post-contrast T1-weighted image (Figure 3B) demonstrated slightly less patchy enhancement than the images taken before treatment. The previous band-like area of slow diffusion now showed facilitated diffusion, except at the periphery of the original lesion, where a thin rim of hypointensity could still be discerned on an ADC map (Figure 3C,D). There was no clinical decline associated with these new imaging findings, despite the fact that the patient was no longer taking steroids.

Approximately 5 months after presentation the patient's weakness had continued to improve, with 4+ out of 5 strength in the left upper and lower extremities (MRC scale). Her recovery was complicated by paroxysmal tonic spasms of the left upper extremity, occasional headaches, and fatigue. Brain MRI demonstrated a reduction in the size of the lesion on T2-weighted and FLAIR images, no diffusion restriction, and

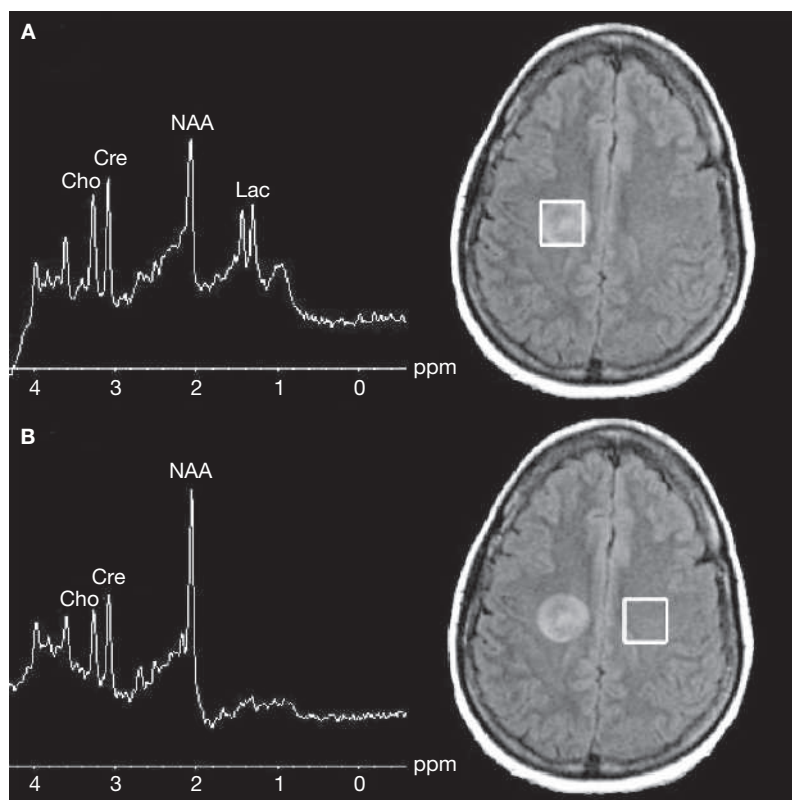


Figure 2 Magnetic resonance spectroscopy imaging of a patient with Baló's concentric sclerosis, 12 days after onset of symptoms. **(A)** Single-voxel spectroscopy of the lesion (TR/TE=2,000/35 ms) shows an elevated lactate doublet peak and a mildly decreased *N*-acetylaspartate peak, compared with the contralateral side **(B)**; TR/TE=2,000/35 ms). Abbreviations: Cho, choline; Cre, creatinine; Lac, lactate; NAA, *N*-acetylaspartate; ppm, parts per million; TE, echo time; TR, repetition time.

a further reduction in enhancement. Repeat MRS showed a continued reduction in the NAA peak, a less-prominent lactate doublet peak, and mild elevation of the choline peak (consistent with increased lipid membrane turnover, and perhaps with continued inflammation or gliosis, or both), compared with previous imaging.

The patient had not experienced any important clinical changes or new symptoms at nearly 7 months after presentation. An MRI scan continued to show progressive evolution of the right periventricular lesion on FLAIR and T2-weighted imaging. MRS using a multivoxel technique showed a decrease in the NAA peak and a slight increase in the choline peak. A small lactate peak was still present. Repeated physical examination of the patient at 1, 2, and 3 years after her initial presentation demonstrated almost complete resolution of the neurological

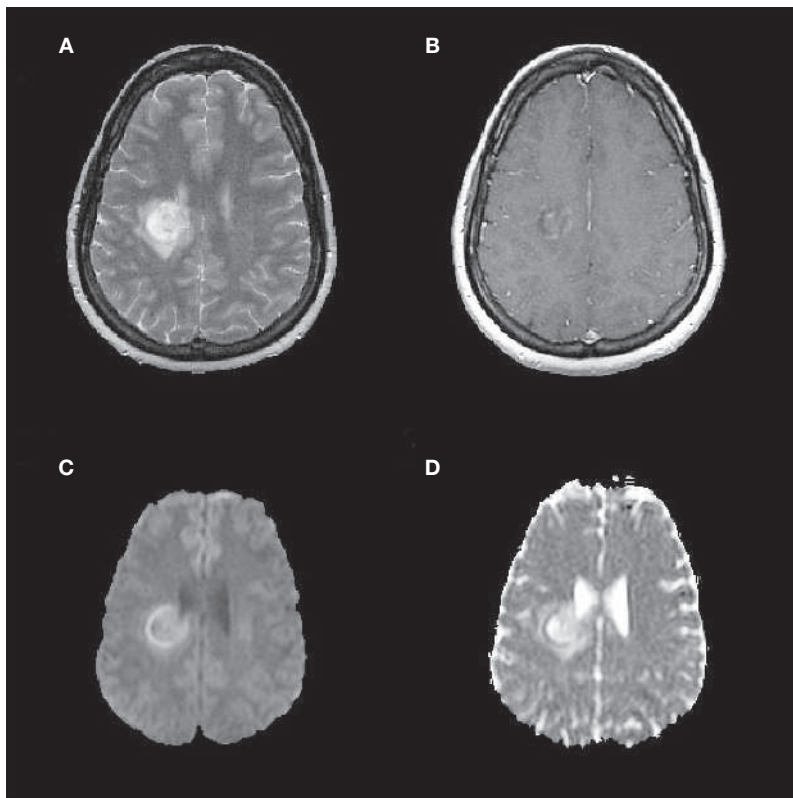


Figure 3 MRI scan of a patient with Baló's concentric sclerosis, 3 months after initial presentation. **(A)** T2-weighted image (TR/TE=2,500/109 ms) shows disorganization of the concentric ring appearance, and a new area of edema surrounding the original lesion. **(B)** Post-contrast T1-weighted image (TR/TE=600/17 ms) shows patchy enhancement, although slightly less than was seen 12 days after symptom onset. **(C)** Trace diffusion-weighted image ($b=1,000$ s/mm²) and **(D)** apparent diffusion coefficient map show only a thin rim of restricted diffusion at the outer rim of the original lesion, with facilitated diffusion centrally and at the outer edema. Abbreviations: *b*, diffusion gradient strength; TE, echo time; TR, repetition time.

deficits; only mild spasticity and hyperreflexia in the left upper extremity were still present at the last follow-up. The patient has not experienced additional flares and has not been started on immunomodulatory medications. Neuroimaging studies performed during the 4 years following initial presentation have demonstrated no additional lesions.

DISCUSSION OF DIAGNOSIS

BCS, which is considered a rare variant of multiple sclerosis (MS), is characterized by a lesion consisting of rings of demyelination alternating with rings of intact myelin. Lesions have been observed in the spinal cord, cerebellum, brain stem, optic chiasm, and cerebral hemispheres.² BCS is thought to be slightly more prevalent among males than among females,

and to be particularly prevalent among younger men.³ Traditionally, BCS has been considered to be a rapidly fatal disease. With the advent of MRI, patients like the individual described in this Case Study have been diagnosed early, received treatment, and survived for months or years. These results imply that some cases of BCS might have a mild course, and cases that could have been effectively treated but previously remained unrecognized are now being discovered. A classification scheme for BCS has been proposed that defines the disease into the following three subtypes: a self-limited, monophasic illness; relapsing–remitting demyelination; and the classically described, primary rapidly progressive course (Table 1).⁴

The pathogenesis of BCS remains unknown, but current theories are discussed in an accompanying Review article in this issue.⁵ The basic pathology of BCS is distinguished by the presence of lamellar rings within the lesion that can often be detected on MRI. Various theories have been advanced to explain this peculiar band pattern. Since Baló described the lesion,⁶ hypotheses of its mode of generation have included physiochemical or cytotoxic etiologies and, more recently, the concept of protective ischemic preconditioning.⁷

BCS can affect any area of the brain, optic chiasm, or spinal cord, so it could potentially cause almost any neurological symptom. Typical events attributable to BCS can include episodes of numbness, weakness, or loss of coordination, affecting an arm, a leg, or both. Brainstem involvement can present as diplopia, altered sensation in the face, or ataxia. BCS affecting the optic chiasm can present as blurry vision with painful eye movements. Disease localized to the spinal cord can cause sensory or motor changes involving one side of the body, or below a certain spinal cord level. Cerebral BCS lesions, as seen in this case, might present as weakness or numbness, and in rare cases cause aphasia or other types of cortical dysfunction. The diagnosis is usually made by observing a concentric ring pattern on MRI; laboratory studies might help to exclude other etiologies. In uncertain cases, a biopsy can be performed to confirm the diagnosis of BCS.

DIFFERENTIAL DIAGNOSIS

The patient in this Case Study presented with acute weakness accompanied by symptoms suggestive of prominent right hemispheric

Table 1 Proposed classification scheme for Baló's concentric sclerosis.

Type	Characteristics
Single, self-limited event	Monophasic event with no further clinical relapses after onset
Relapsing–remitting	Repeated, clearly defined exacerbations consisting of an acute worsening of neurological function followed by a partial or complete recovery
Primary progressive	Slow and continuous worsening of symptoms from onset with no distinct relapses or remissions

involvement (i.e. left-sided hemiparesis, hypoaesthesia, and hyperreflexia). Although the patient had initially been diagnosed with a possible ischemic stroke, subsequent neuroimaging results were more consistent with an inflammatory process. In particular, the concentric appearance of the lesion on T2-weighted, FLAIR, and diffusion-weighted images was not consistent with an ischemic stroke image pattern, ruling out this diagnosis. The circular shape of the lesion, lack of marked mass effect, and absence of an increased choline peak on MRS made tumor an unlikely diagnosis. The patient was afebrile, and blood cultures and echocardiogram were normal, making an abscess unlikely. Neuroimaging results were also inconsistent with an abscess—the concentric appearance and periventricular location of the lesion, lack of prominent peripheral ring enhancement, and absence of central restricted diffusion all made this diagnosis improbable.

Other diseases in the clinical differential diagnosis of BCS include acute disseminated encephalomyelitis (ADEM) and MS. ADEM is clinically differentiated from MS on the basis of more-frequent occurrence of convulsions, vertigo, bilateral optic neuritis, meningismus, fever, nausea, aphasia, dysphagia, confusion, and altered level of consciousness.^{8,9} The cerebrospinal fluid in patients with ADEM is more likely to be marked by pleocytosis and elevated protein levels, whereas oligoclonal bands are more often seen in patients with MS. The spectrum of neurological sequelae that can accompany BCS can make it difficult to clinically distinguish from MS or ADEM. Some patients with BCS present with symptoms more typical of MS, such as isolated hemiparesis, whereas others present with confusion, seizures, vertigo, diplopia, or cortical signs, all of which are more commonly associated with ADEM (see online Supplementary Table 1).⁵ Furthermore, as can occur in both MS and ADEM, patients with BCS

can present with a single event or with repeated flares (Table 1).

The advent of MRI has vastly improved our ability to distinguish between these three disease entities. MS lesions are generally smaller and more sharply demarcated than either ADEM or BCS lesions,¹⁰ whereas ADEM lesions tend to be more extensive and show enhancement.^{8–10} The multiple rings of demyelination and intact myelin seen in BCS are radiologically distinct from both MS and ADEM lesions. MRI and, in some cases, laboratory studies, are necessary to correctly establish a diagnosis of BCS and initiate appropriate therapy. The typical concentric ring pattern initially seen on T2-weighted and FLAIR images in the present case was highly suggestive of BCS (Figure 1).

TREATMENT AND MANAGEMENT

Owing to the rarity of BCS, no clinical trials have been performed specifically to determine the optimum treatment for the condition. Most cases reported in the literature have used intravenous or oral steroids, or both, with varying dose and duration of treatment (see online Supplementary Table 1).⁵ Two case reports have illustrated the successful use of mitoxantrone to treat BCS.^{11,12} One of the patients in these case reports received mitoxantrone treatment only after her condition failed to improve with 8 days of high-dose intravenous steroid therapy.¹¹ Another patient whose condition was refractory to intravenous steroid treatment derived a mild clinical benefit from intravenous immunoglobulin therapy.¹³ An additional patient who did not respond to an initial combined treatment of intravenous steroids and intravenous immunoglobulin was subsequently treated with azathioprine and high-dose intravenous methylprednisolone, from which he derived a mild, but temporary, benefit.¹⁴ Plasmapheresis produced a dramatic clinical response in two patients who were refractory to steroid treatment.^{15,16}

Acknowledgments

The patient and her family are thanked for their full cooperation at all stages of the assessment and treatment. The authors would like to thank Dr Steven Galetta and Dr Dina Jacobs for their helpful comments and suggestions. This work was supported by a University-wide AIDS Research Program Grant (CF05-SD-301) and an American Foundation for AIDS Research Grant (106729-40-RFRL), both awarded to BM Ances.

Competing interests

The authors declared they have no competing interests.

The question of whether disease-modifying therapies commonly used in MS have a role in the treatment of BCS has not been explored. The patient in this Case Study was treated with intravenous steroids followed by an oral prednisone taper, and she experienced considerable improvement in her symptoms. The patient has remained stable and has not required immunomodulatory therapy in the 4 years since initial presentation.

CONCLUSIONS

The clinical presentation of weakness and numbness in the present case led to the initial diagnosis of an ischemic stroke. Subsequent MRI studies showed a brain lesion with a pattern of concentric rings of demyelination alternating with rings of intact myelin, confirming a diagnosis of BCS.

BCS is a heterogeneous disease with a variable clinical course. Patients can have a few relapses and then remain clinically stable for many decades, recover without developing further symptoms, or progress rapidly to death over several months. Furthermore, BCS-like lesions have been observed in certain subtypes of MS.¹⁷ Although there are clearly patients in whom BCS remains benign, it is difficult to predict which patients eventually will follow this disease course.

BCS is rare, but improved clinical awareness and the use of advanced neuroimaging techniques can lead to accurate diagnosis and treatment. Intravenous steroids have typically been used in the acute management of BCS, but further studies are required to assess the efficacy of such a regimen.

Supplementary information in the form of a table is available on the *Nature Clinical Practice Neurology* website.

References

- 1 Medical Research Council (1943) Aids to the investigation of peripheral nerve injuries. In *Medical Research Council War Memorandum*, 11–46. London, UK: His Majesty's Stationery Office
- 2 Karaarslan E *et al.* (2001) Baló's concentric sclerosis: clinical and radiologic features of five cases. *AJNR Am J Neuroradiol* **22**: 1362–1367
- 3 Ng SH *et al.* (1999) MRI features of Baló's concentric sclerosis. *Br J Radiol* **72**: 400–403
- 4 Ansel DJ (2006) Reply to the paper by Wiendl *et al.*: diffusion abnormality in Baló's concentric sclerosis: clues for the pathogenesis. *Eur Neurol* **55**: 111–112
- 5 Mowry EM *et al.* (2007) Technology Insight: can neuroimaging provide insights into the role of ischemia in Baló's concentric sclerosis? *Nat Clin Pract Neurol* **3**: 341–348
- 6 Baló J (1928) Encephalitis periaxialis concentrica. *Arch Neurol Psychiatry* **19**: 242–264
- 7 Stadelmann C *et al.* (2005) Tissue preconditioning may explain concentric lesions in Baló's type of multiple sclerosis. *Brain* **128**: 979–987
- 8 Brinar VV (2004) Non-MS recurrent demyelinating diseases. *Clin Neurol Neurosurg* **106**: 197–210
- 9 Brinar VV and Poser CM (2006) The spectrum of disseminated encephalomyelitis. *Clin Neurol Neurosurg* **108**: 295–310
- 10 Poser CM and Brinar VV (2004) The nature of multiple sclerosis. *Clin Neurol Neurosurg* **106**: 159–171
- 11 Hanemann CO *et al.* (1993) Baló's concentric sclerosis followed by MRI and positron emission tomography. *Neuroradiology* **35**: 578–580
- 12 Manelfe C *et al.* (1999) Case no 1 diagnosis: Baló concentric sclerosis [French]. *J Radiol* **80**: 1700–1702
- 13 Pohl D *et al.* (2005) Baló's concentric sclerosis associated with human herpesvirus 6 infection. *J Neurol Neurosurg Psychiatry* **76**: 1723–1725
- 14 Singh S *et al.* (1999) Baló's concentric sclerosis: value of magnetic resonance imaging in diagnosis. *Australas Radiol* **43**: 400–404
- 15 Sekijima Y *et al.* (1997) Serial magnetic resonance imaging (MRI) study of a patient with Baló's concentric sclerosis treated with immunoabsorption plasmapheresis. *Mult Scler* **2**: 291–294
- 16 Airas L *et al.* (2005) Successful pregnancy of a patient with Baló's concentric sclerosis. *Mult Scler* **11**: 346–348
- 17 Lucchinetti C *et al.* (2000) Heterogeneity of multiple sclerosis lesions: implications for the pathogenesis of demyelination. *Ann Neurol* **47**: 707–717