

Severe Bleeding Complications during Antiepileptic Treatment with Valproic Acid in Children*

Author

E. Cannizzaro, M. Albisetti, G. Wohlrab, M. Schmugge

Affiliation

Division of Haematology and Neurology, University Children's Hospital, Zurich, Switzerland

Key words

- Epilepsy
- valproic acid
- von Willebrand factor
- platelets
- coagulation

Abstract

Valproic acid (VPA) is an antiepileptic drug frequently used in children. Although VPA can cause a variety of laboratory abnormalities affecting haemostasis, controversy exists about the clinical relevance of such haematological abnormalities.

We report on 4 children with severe bleeding complications while on VPA therapy; two presented with intracranial bleeding, while two suffered from severe bleeding postoperatively. Diagnostic and therapeutic measures are discussed that help to avoid severe bleeding complications in children with VPA treatment.

Abbreviations

| | |
|------|---------------------------------------|
| aPTT | activated partial thromboplastin time |
| INR | international normalized ratio |
| VPA | valproic acid |
| VWD | von Willebrand's disease |
| VWF | von Willebrand factor |

tions related to the administration of VPA have been reported in 2 children and 2 adults, of whom only 1 patient suffered from an intracranial bleed after lobectomy [8,14,15,16]. This report describes 4 children with severe bleeding complications during VPA therapy.

Introduction

Valproic acid (VPA) is frequently used in children for the prevention and treatment of generalised and focal epilepsy. Side effects of VPA include teratogenicity, weight gain, amenorrhoea, hair loss, nausea, tremor, increased bone turnover and, on rare occasions, severe liver toxicity and pancreatitis [12, 13]. More commonly, a variety of haematological laboratory abnormalities including thrombocytopenia, impaired platelet aggregation with agonists like ADP and collagen, prolongation of the bleeding time and the PFA-100 closure times, and decreased plasma concentrations of fibrinogen, von Willebrand factor (VWF) and factor XIII have been observed [3, 5, 6, 9, 14, 17, 18]. Although haemostatic abnormalities during VPA therapy have been described in many studies, the clinical relevance of these abnormalities is still debated. So far, significant bleeding complica-

Case Reports

For this case series, clinical records were reviewed retrospectively. None of the 4 children had a significant family history of bleeding, and none had experienced abnormal bleeding episodes prior to the onset of VPA. The patients had not received acetylsalicylic acid or non-steroidal anti-inflammatory drugs or other medication known to interfere with platelet function or VWF synthesis, aside from VPA. Treatment duration until the bleeding complication occurred ranged from 7 days to 9 years. Laboratory studies at the time of bleeding in the 4 patients are presented in **Table 1**.

Patient 1

This boy suffered from a hypoxic-ischaemic encephalopathy with brain atrophy. At the age of 4 months, he was started on VPA therapy at a dose of 30 mg/kg/day due to epilepsy with tonic complex partial seizures. One year after initiation of VPA therapy, the boy developed a spontaneous subdural haematoma (**Fig. 1**). Laboratory studies at the time of bleeding revealed a pro-

received 9.11.2006
accepted 27.3.2007

Bibliography

DOI 10.1055/s-2007-981448
Neuropediatrics 2007;
38: 42–45
© Georg Thieme Verlag KG
Stuttgart · New York
ISSN 0174-304X

Correspondence

M. Schmugge
Division of Haematology
University Children's
Hospital Zürich
Steinwiesstrasse 75
8032 Zürich
Switzerland
Tel.: +41/44/266 71 11
Fax: +41/44/266 71 71
markus.schmugge@kispi.
unizh.ch

* Presented in part at the 47nd annual meeting of the American Society of Haematology, Atlanta, Georgia, December 2005.

Table 1 Laboratory studies at the time of bleeding in the four reported patients

| Test | Patient 1 | Patient 2 | Patient 3 | Patient 4 |
|--|-----------|-----------|-----------|-----------|
| INR | 1.15 | 1.1 | 1.15 | 1.2 |
| aPTT (sec) | 34 | 28 | 33 | 36 |
| Fibrinogen (mg/L) | 2.2 | 4.4 | ND | 2.3 |
| PFA 100 COL/EPI (sec)** | ND | >230† | ND | 205† |
| PFA 100 COL/ADP (sec)*** | ND | 80 | ND | 76 |
| von Willebrand factor RiCo (%) ⁺ | 20↓ | ND | 135 | 111 |
| von Willebrand factor AG (%) ⁺ | 38↓ | ND | 105 | 135 |
| Factor VIII (%) ⁺ | 61 | ND | 77 | ND |
| Platelets (10 ⁹ /L) ⁺⁺ | 688 | 406 | 47↓ | 186 |
| Haemoglobin (g/L) | 95 | 98 | 127 | 104 |
| Haematocrit (L/L) | 0.31 | 0.28 | 0.37 | 0.32 |

†Indicate abnormal results.

Abbreviations: sec = seconds, RiCo = ristocetin cofactor, AG = antigen, ND = not done

Normal range: **85–165 sec; ***71–118 sec; *50–200%, ++ > 150 × 10⁹/L.

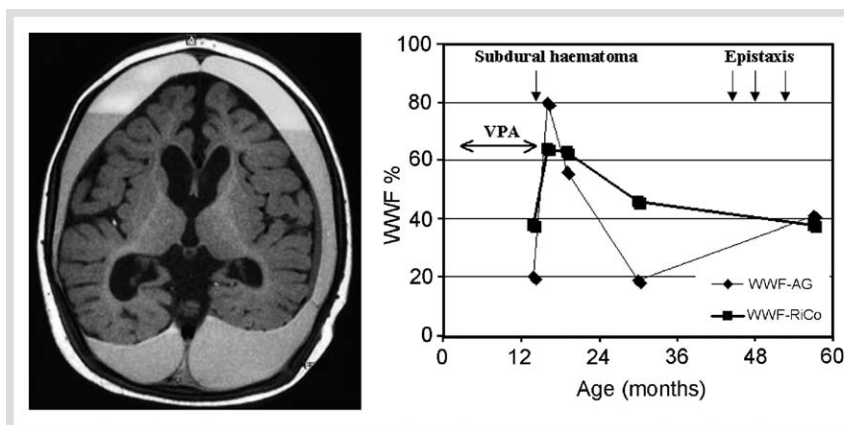


Fig. 1 MRI and laboratory studies of a 14-month-old boy (patient 1) who suffered from an intracranial bleed during treatment with valproic acid (VPA). The MRI on the left shows the large subdural haematoma and the pre-existing brain atrophy. The graph on the right documents the course of VWF antigen level (VWF-AG) and VWF ristocetin cofactor activity (VWF-RiCo) during and after VPA treatment. Note the increase of VWF levels after VPA treatment had been stopped.

longed bleeding time (16 min) and decreased VWF levels (VWF RiCo 20%, VWF Ag 38%). In addition, abnormal platelet aggregation with ADP and arachidonic acid was detected. The boy was treated with VWF-containing factor concentrate and VPA was discontinued. Shortly after, an increase in VWF levels was observed (VWF RiCo 80%, VWF 64%). However, repeated measurements later on revealed decreased VWF levels, suggesting the presence of a congenital von Willebrand's disease (VWD) type I. Clinically, even after VPA was stopped, the boy suffered from repeated episodes of severe epistaxis. (● Fig. 1).

Patient 2

This 4-year-old boy was referred to our intensive care unit because of a herpes simplex virus encephalitis. Ten days after admission, the boy developed generalised seizures and an intravenous VPA therapy at a dose of 30 mg/kg was started. Thirteen days after admission the diagnosis of herpes simplex virus encephalitis was confirmed by a second lumbar puncture with a positive finding of herpes simplex virus PCR (polymerase chain reaction) in the cerebral spinal fluid. An intravenous acyclovir therapy was started. Seven days after starting VPA therapy and four days after initiation of acyclovir therapy, the boy died from a severe intraparenchymal cerebral bleeding.

Laboratory studies at the time of bleeding revealed a prolonged PFA 100 collagen/epinephrine closure time that may be indicative of a mild platelet function defect and/or reduced VWF. Unfortunately, no further studies (i.e., VWF Ag, VWF RiCo) could be obtained.

Patient 3

This boy with a severe development retardation and epilepsy had been treated at another institution with VPA at a dose of 70 mg/kg/day since the age of 1 year for myoclonic astatic seizures. At the age of 5 years, the boy underwent tonsillectomy due to recurrent otitis and tonsillitis. The boy did not receive any antibiotics before tonsillectomy. Intra- and postoperatively he developed severe diffuse oropharyngeal haemorrhage requiring red cell transfusion and admission to the intensive care unit.

In this patient, thrombocytopenia of $47 \times 10^9/L$ was first detected at the time of bleeding because no platelet count had been obtained preoperatively. Due to the low platelet count no platelet function test could be performed. VWF levels were found to be normal shortly after the bleeding. Despite an increased VPA dose (70 mg/kg) before surgery; the VPA serum level obtained postoperatively showed levels in the therapeutic range. One week after reduction of the VPA dose (50 mg/kg), the laboratory studies demonstrated thrombocytosis of $922 \times 10^9/L$ that normalised within the following 2 weeks.

Patient 4

This 13-year-old boy with severe mental retardation due to an unclear congenital encephalopathy had been treated with VPA for tonic clonic seizures since the age of 4 years. When he was admitted for urological surgery to remove a syringocele and a stricture of the urethra, preoperative laboratory studies for the presence of haematological side effects of VPA revealed normal VWF but a prolonged PFA 100 collagen/epinephrine closure

time, that indicates a mild platelet function disorder. Because of his epilepsy, DDAVP was not given and as laboratory results for VWF were still unavailable at the time of surgery, the boy was treated with a VWF-containing factor concentrate preoperatively. He underwent surgery without any bleeding complication and further doses of factor concentrate were not administered. On the second postoperative day, the boy developed a large epidural haematoma at the site of an epidural catheter inserted for anaesthesia. After administration of a second dose of VWF-containing factor concentrate and removal of the epidural catheter the patient recovered completely without any residuals.

Discussion

VPA is a commonly used antiepileptic drug that can cause a variety of different haematological side effects. The molecular mechanisms causing the haemostatic laboratory abnormalities are currently unknown; recent studies using VPA for the treatment of patients with myelodysplastic syndrome have demonstrated that VPA increases histone acetylation and increases apoptosis in haematopoietic cells [10]. Controversy exists about the clinical relevance of the haemostatic abnormalities seen in patients under VPA therapy and the risk for significant bleeding complications. While some authors have reported on increased blood losses and transfusion requirements during orthopaedic surgery, others have described mild postoperative bleeding, i.e., mucocutaneous haemorrhage, only [1,4]. Considering that VPA is a frequently used antiepileptic drug, a direct cause-effect relationship between VPA therapy and haematological abnormalities and/or bleeding complications would imply a higher incidence of these abnormalities. However, such a higher incidence has not been described. Here we report on four paediatric patients with different underlying diseases developing severe bleeding complications during VPA therapy. In all children haemostatic laboratory abnormalities, including reduced VWF levels, thrombocytopenia and abnormal *in vitro* bleeding time (PFA 100 closure time), indicating impaired platelet function or VWD, were found at the time of bleeding.

From this series we may conclude that in patients treated with VPA and with haematological laboratory abnormalities, severe bleeding could be triggered in the presence of additional risk factors. The clinical conditions encountered with the four patients would, in fact, not explain sufficiently the type of bleeding described in our patients, without the presence of VPA-induced haemostatic abnormalities. While VWD type 1, diagnosed in patient 1, typically causes mucocutaneous bleeding, spontaneous intracranial haemorrhages are usually not seen. A herpes simplex encephalitis, as seen in patient 2, can potentially cause intracranial bleeding which, however, usually occurs at the initial state of the disease, and mostly affects neonates [2]. Patient 2 developed intraparenchymal cerebral bleeding 17 days after admission and 7 days after VPA was started. However, the recent finding by Larkin et al. of acyclovir causing inhibition of platelet function suggests that the bleeding complication in our patient 2 may not be related to VPA therapy alone but to the combination of both drugs, VPA and acyclovir [11]. As regards patients 3 and 4, the type of surgery and the anaesthesiological management they were exposed to do not usually cause severe intra- or postoperative haemorrhage with-

out a pre-existing bleeding disorder. With hindsight, more accurate monitoring may have avoided the bleeding complications. Some limitations regarding the interpretation of laboratory results in our patients need to be considered. First, as the data were collected retrospectively and haematologists were sometimes involved only after the bleeding event, no baseline work-up was available. Second, only the first patient had been studied by platelet aggregometry around the acute bleeding event. This is indeed a more specific laboratory test for platelet function than the PFA 100 closure time. Third, the PFA 100 closure time can be prolonged in patients with anaemia ($< 100\text{ g/L}$), haematocrit $< 0.3\text{ L/L}$, and thrombocytopenia ($< 100 \times 10^9/\text{L}$), as it might have influenced the results in patient 2 [7]. Finally no testing excluding acquired dysfibrinogenemia in our patients was performed.

In the light of these considerations and in accordance to recent findings by Gerstner et al, some conclusions can be drawn [5]. Before starting VPA therapy, patients should be evaluated for the presence of congenital bleeding disorders (i.e., VWD, platelet function disorders, mild haemophilia). This should be done based on a patient's personal history and family history. Prior to surgical interventions, testing for VPA-induced abnormalities of the platelet count, plasmatic haemostasis (INR, aPTT, fibrinogen, VWF) and platelet function (PFA 100 and/or platelet aggregometry) should be considered. Since we do not know how fast haemostatic abnormalities can develop, intravenous VPA has to be used cautiously in severely ill children and intensive care patients at increased risk for bleeding. Finally, the benefit or necessity of any surgical or anaesthesiological procedures (i.e., insertion of epidural catheters or removal of drainages) has to be evaluated and weighted against the risk for bleeding. Among our patients, the duration of VPA treatment varied widely, and plasma levels of VPA were within the normal therapeutic range at the time of bleeding. Although a correlation between VPA dose and haemostatic abnormalities has been reported, the findings in our patients indicate that laboratory abnormalities and bleeding complications occur independently of both plasma level of VPA and treatment duration [6]. So far, the duration of haemostatic abnormalities after withdrawing VPA is unknown.

In conclusion, the reported cases suggest that VPA therapy may cause haematological abnormalities that may lead to severe bleeding complications. Paediatricians, anesthesiologists and neurologists should be aware of the possible haemostatic side effects and the potential risk of bleeding in patients under VPA therapy. Further prospective studies are required to clarify the clinical relevance of these haemostatic abnormalities in a larger cohort of patients, and to assess the incidence of severe bleeding complications during VPA therapy.

References

- 1 Anderson GD, Temkin NR, Chandler WL, Winn HR. Effect of valproate on haemostatic function in patients with traumatic brain injury. *Epilepsy research* 2003; 57: 111–119
- 2 Argyriou AA, Tsota I, Solomou E, Marangos M, Kalogeropoulou C, Petsas T et al. Intracerebral haemorrhage as a rare complication of HSV-1 meningoencephalitis: Case report and review of the literature. *Scand J Infect Dis* 2006; 38: 63–66
- 3 Banerjee MC, Diener W, Kutschke G, Schneble HJ, Korinthenberg R, Sutor AH. Pro- and anticoagulatory factors under sodium valproate therapy in children. *Neuropediatrics* 2002; 33: 215–220
- 4 Chambers HG, Weinstein CH, Mubarak SJ, Wenger DR, Silva PD. The effect of valproic acid on blood loss in patients with cerebral palsy. *J Paediatr Orthop* 1999; 19: 792–795

- 5 Gerstner T, Teich M, Bell N, Longin E, Dempfle C, Brand J et al. Valproate-associated coagulopathies are frequent and variable in children. *Epilepsia* 2006; 47: 1136–1143
- 6 Gidal B, Spencer N, Maly M, Pitterle M, Williams E, Collins M et al. Valproate-mediated disturbances of haemostasis. *Neurology* 1994; 44: 1418–1422
- 7 Harrison P. The role of PFA-100 testing in the investigation and management of haemostatic defects in children and adults. *B J Haematol* 2005; 130: 3–10
- 8 Konig S, Scheffner D, Rauterberg-Ruland I, Kochen W, Hofmann WJ, Wokittel E et al. Fatal hepatic failure in a normally developed 5-year-old boy by VPA monotherapy. *Monatsschr Kinderheilkd* 1987; 135: 310–313
- 9 Kreuz W, Linde R, Funk M, Meyer-Schrod R, Föll E, Nowak-Göttl U et al. Valproate therapy induces von Willebrand disease type I. *Epilepsia* 1992; 33: 178–184
- 10 Kuendgen A, Strupp C, Aivado M, Bernhardt A, Hildebrandt B, Haas R et al. Treatment of myelodysplastic syndromes with valproic acid alone or in combination with all-*trans*-retinoic acid. *Blood* 2004; 104: 1266–1269
- 11 Larkin D, Murphy D, Reilly DF, Cahill M, Sattler E, Harriott P et al. ICln, a novel integrin $\alpha_{IIb}\beta_3$ -associated protein, functionally regulates platelet activation. *J Biol Chem* 2004; 279: 27286–27293
- 12 Perucca E. Pharmacological and therapeutic properties of valproate: a summary after 35 years of clinical experience. *CNS Drugs* 2002; 16: 695–714
- 13 Peterson GM, Naunton M. Valproate: a simple chemical with so much to offer. *J Clinical Pharmacy and Therapeutics* 2005; 30: 417–421
- 14 Pohlmann-Eden B, Peters CAN, Wennberg R, Dempfle CE. Valproate induces reversible factor XIII deficiency with risk of perioperative bleeding. *Acta Neurol Scand* 2003; 108: 142–145
- 15 Rosenberg HK, Ortega W. Haemorrhagic pancreatitis in a young child following valproic acid therapy. Clinical and ultrasonic assessment. *Clin Paediatr (Phila)* 1987; 26: 98–101
- 16 Sleiman C, Raffy O, Roué C, Mal H. Fatal pulmonary haemorrhage during high-dose valproate monotherapy [letter]. *Chest* 2000; 117: 613
- 17 Verrotti A, Greco R, Matera V, Altobelli E, Morgese G, Chiarelli F. Platelet count and function in children receiving sodium valproate. *Paediatr Neurol* 1999; 21: 611–614
- 18 Zeller JA, Schlesinger S, Runge U, Kessler C. Influence of valproate monotherapy on platelet activation and hematologic values. *Epilepsia* 1999; 40: 186–189