

Arterial Ischemic Stroke in a Child With β -Thalassemia Trait and Methylentetrahydrofolate Reductase Mutation

Vesna Brankovic-Sreckovic, MD, Vedrana Milic Rasic, MD, PhD,
Valentina Djordjevic, MSc, Milos Kuzmanovic, MD, and Sonja Pavlovic, PhD

Genetic and acquired disorders that foster a procoagulable state represent risk factors for stroke in childhood. Although an increased incidence of thromboembolic complications has been reported in patients with thalassemia, severe cerebral thromboembolism has rarely been observed in patients with β -thalassemia minor. This article describes a case study of a 1-year-old boy who presented with left-sided hemiparesis, seizures, microcytic anemia, and recent infection with reactive thrombocytosis. Ischemic infarction in the territory of the right middle cerebral artery was confirmed by magnetic

resonance imaging and magnetic resonance angiography. Genetic tests showed that the patient was heterozygous for the β^0 -thalassemia IVS-1-1 mutation and homozygous for the methylentetrahydrofolate reductase C677T mutation. Based on these findings, it was concluded that the synergistic effects of multiple, genetic, and acquired prothrombotic risk factors brought about the hypercoagulable state that resulted in overt stroke in a thalassemic patient in early childhood.

Keywords: stroke; β -thalassemia trait; MTHFR mutation

Many recognized medical conditions and multiple risk factor interactions predispose to stroke in childhood.^{1,2} Genetically defined hematological disorders such as hemoglobinopathies, which are characterized by either acute or chronic hypercoagulable states, can lead to cerebrovascular complications.³ After sickle-cell disease, β -thalassemia is the most frequently occurring genetic disease that is found in specific parts of the world and that leads to anemia in early childhood. Stroke is the major cause of morbidity in children with sickle-cell disease, and repeated blood transfusions significantly reduce its recurrence.⁴ Cerebral thromboembolic events have been reported in patients with thalassemia major and thalassemia intermedia.^{5,6} However, clearly defined overt stroke has rarely been described in thalassemia minor.⁷ In contrast, silent brain infarctions, as observed by magnetic resonance imaging (MRI), occur in up to

37% of patients with β -thalassemia.^{8,9} These findings could be explained by the persistent hypercoagulable state that is established in patients with thalassemia at a very early age, suggesting that thrombosis is for the most part a subclinical process.^{3,10} Conditions that temporarily activate hemostasis could further complicate the continuing hypercoagulability and contribute to clinically symptomatic thromboembolism.

In this article, we present the case of a male infant, heterozygous for β^0 -thalassemia and homozygous for the C677T mutation in the methylentetrahydrofolate reductase (MTHFR) gene, with recent infection and reactive thrombocytosis that resulted in clinical phenotype of acute arterial ischemic cerebral infarction.

Case Report

A 12-month-old boy was admitted to the Department of Child Neurology after a sudden onset of left-sided weakness. The patient had an upper respiratory tract infection 5 days prior to the onset of irritability, reduced speech, and diminished use of left extremities. On admission, he was afebrile and euvoletic. The patient's family history is noteworthy insofar as the mother presented with refractory anemia that was treated by blood transfusion during pregnancy. She had a miscarriage in the second trimester of the next pregnancy. On admission, neurological exam-

From the Clinic for Child Neurology and Psychiatry, Medical Faculty, University of Belgrade, Serbia (VB-S, VMR); the Institute of Molecular Genetics and Genetic Engineering, Belgrade, Serbia (VD, SP); and the Mother and Child Health Institute of Serbia Dr Vukan Cupic, Belgrade, Serbia (MK).

Address correspondence to: Vesna Brankovic-Sreckovic, MD, Clinic for Child Neurology and Psychiatry, Medical Faculty, University of Belgrade, Dr Subotica 6a, Belgrade 11 000, Serbia; e-mail: vladas@infosky.net.

Brankovic-Sreckovic V, Milic Rasic V, Djordjevic V, Kuzmanovic M, Pavlovic S. Arterial ischemic stroke in a child with β -thalassemia trait and methylentetrahydrofolate reductase mutation. *J Child Neurol*. 2007;22:208-210.

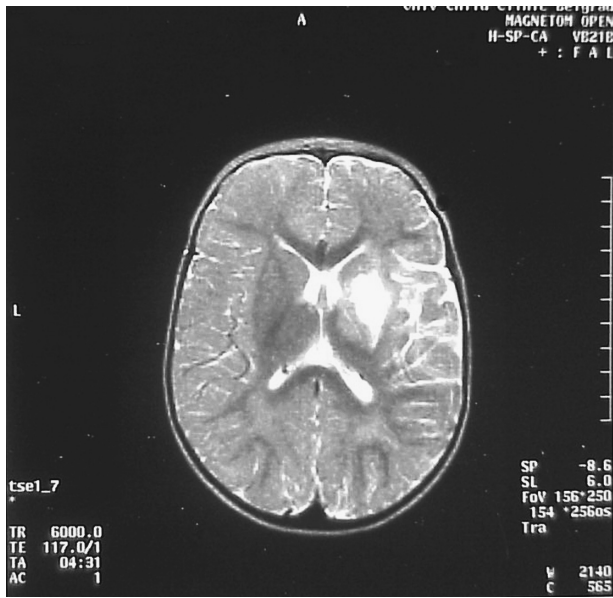


Figure 1. Axial T2-weighted magnetic resonance imaging showing ischemic infarction in the right internal capsule, putamen, and thalamus.

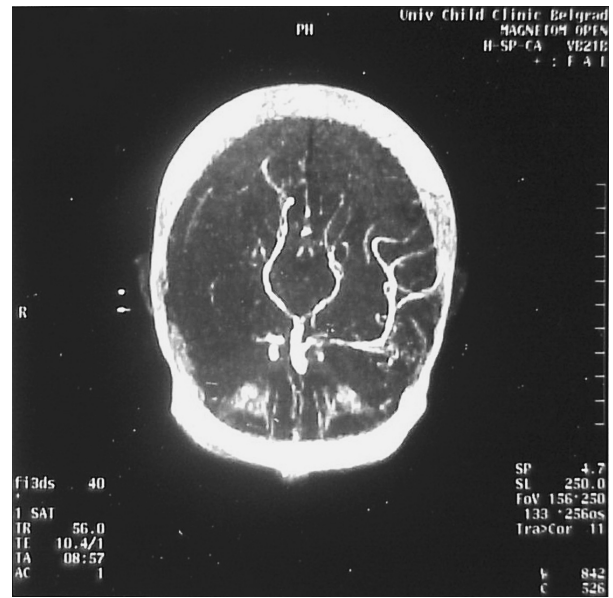


Figure 2. Magnetic resonance angiography showing occlusion of the M1 segment of the right middle cerebral artery.

ination of the child revealed a severe flaccid left-sided hemiparesis that was worse in the arm than in the leg, weakness in the left side of the face, and aphasia. Consequently, partial motor seizures of the left extremities were observed after 4 days. An initial contrast computed tomography scan revealed a hypodense area in the right thalamic region. An MRI of the brain confirmed infarction in the right thalamic region, putamen, and internal capsule (Figure 1). Magnetic resonance angiography revealed stenosis of the proximal segment of the right middle cerebral artery (Figure 2).

Routine hematological evaluation on admission revealed (1) microcytic anemia (hemoglobin concentration, 97 g/L; red blood cell count, $5.55 \times 10^{12}/L$; mean corpuscular volume, 58.2 fL; mean corpuscular hemoglobin, 19.7 pg) and (2) thrombocytosis (platelet count, $723 \times 10^9/L$; white blood cell count, $11.9 \times 10^9/L$). A peripheral blood smear revealed slight morphological changes of red blood cells (hypochromia and anisopoikilocytosis). Screening for pathological hemoglobin fractions by cellulose acetate electrophoresis displayed an increase of the A_2 fraction, as well as an increased fetal hemoglobin level of 4.96%. The heat test result for unstable hemoglobin fraction detection was negative. The serum iron concentration was 17.4 $\mu\text{mol}/L$. Activated protein C resistance, antithrombin III, proteins C and S, and anticardiolipin antibodies and lupus anticoagulant were within physiological limits. The lipid status (high-density lipoprotein, low-density lipoprotein, apolipoprotein A, and apolipoprotein B) was normal. Subsequent measurement of the total plasma homocysteine concentration 1 year after the stroke revealed that its concentration had not

increased. By amplification refractory mutation system genotyping,¹¹ it was established that the patient was heterozygous for the β -thalassemia mutation IVS-I-1. The mutation, a G \rightarrow C change in the AG dinucleotide that is required for normal splicing, completely prevents splicing; hence, no normal mRNA is formed. The mutation is responsible for the β^0 -type thalassemia syndrome. The patient's mother had similar hematological parameters, and DNA analysis confirmed the presence of the same mutation, whereas the patient's father tested negative. Polymerase chain reaction analysis for thrombophilia risk factors, factor V Leiden, factor II G20210A, MTHFR C677T, PAI-1 4G/5G, and ACE I/D revealed a homozygous state for the MTHFR C677T in the patient and both parents.

Repeated hematological evaluation of the patient during the follow-up period showed an unchanged status and normal platelet count. Total bilirubin and transaminases were not elevated. The results of clinical and ultrasound examinations of the liver and heart were normal. The neurological deficit improved significantly to a moderate residual hemiparesis after rehabilitation therapy. The recurring partial motor epileptic seizures were effectively controlled with valproic acid. Folate repletion was initiated. During the follow-up period, neither recurrent strokes nor silent infarcts were observed by brain MRI.

Discussion

The hypercoagulable state is a risk factor for stroke in childhood. Although the markers of hypercoagulability

such as chronic platelet activation, altered red blood cell properties, and endothelial injury are present from very early childhood in patients with thalassemia, thromboembolic events have rarely been observed at that age.¹⁰

The clinical manifestations of β -thalassemia are diverse, ranging from asymptomatic hypochromia and microcytosis (thalassemic trait) to severe anemia (thalassemia major). Heterozygous β -thalassemia is not usually associated with any clinical manifestation except during periods of stress, such as infections in early childhood and during pregnancy. However, many genetic factors (modifier genes) could contribute to the observed clinical heterogeneity. Complications such as arterial and venous thromboembolic events are well documented in patients in sickle-cell disease, and focal narrowing of the distal internal carotid artery or the proximal middle cerebral artery usually precedes strokes in these children. Such complications have also been described in adults and older children with thalassemia,⁵ but to our knowledge, they have not been reported in an infant—the herein presented case at the time of the stroke.

Heterozygous β^0 -thalassemia was diagnosed in our patient; however, it is unlikely that this condition by itself could have caused such a severe cerebral thromboembolism in a 1-year-old child. Thus, several genetic risk factors for thrombophilia were also investigated. The patient was found to be a homozygous carrier of the MTHFR C677T mutation. Several studies^{12,13} have underlined that the homozygosity for the MTHFR C677T mutation is an important risk factor for cerebrovascular disease and stroke in children, probable due to hyperhomocysteinemia, although the exact mechanism of its activity is not fully elucidated. On the other hand, the MTHFR C677T mutation was not overrepresented in the group of patients with sickle-cell disease and stroke.¹⁴ Also, neither an increased incidence of the MTHFR C677T mutation¹⁰ nor elevated plasma homocysteine levels were found in patients with β -thalassemia major.¹⁵ Nevertheless, the frequency of the MTHFR C677T mutation varies in different ethnic groups. In addition, the concentration of plasma homocysteine could vary under certain conditions, such as during infection. Recurrent central nervous system thrombotic events have also been reported in a patient affected with Sabine hemoglobinopathy who was a heterozygous carrier of the MTHFR C677T mutation.¹⁶

The severe cerebral thromboembolic complication was observed in our patient at the first year of life. It is possible that reactive thrombocytosis¹⁷ that resulted from acute infection contributed to the ongoing hemostatic abnormalities at the time of stroke. Therefore, we suggest that the synergistic effect of inherited (β -thalassemia trait, homozygosity for the MTHFR) and acquired (recent infection with accompanying thrombocytosis) prothrombotic risk factors was involved in the pathogenesis of arterial ischemic stroke in this child. Bearing this in mind, screening for inherited thrombophilia in patients with the β -thalassemia trait and symptomatic thromboembolism is advised. Also, this could have a therapeutic implication in these patients, such as

indication for low molecular heparin prophylaxis during severe infection or major surgery.

Acknowledgment

Part of this work was supported by grant 143051 from the Ministry of Science and Environment Protection of Serbia.

References

1. Kirkham FJ, Hogan AM. Risk factors for arterial ischemic stroke in childhood. *CNS Spectr*. 2004;9:451-464.
2. deVeber G, Monagle P, Chan A, et al. Prothrombotic disorders in infants and children with cerebral thromboembolism. *Arch Neurol*. 1998;55:1539-1543.
3. Eldor A, Rachmilewitz EA. The hypercoagulable state in thalassemia. *Blood*. 2002;99:36-43.
4. Adams RJ. Lesions from the Stroke Prevention Trial in Sickle Cell Disease (STOP) study. *J Child Neurol*. 2000;15:344-349.
5. Borgna-Pignati C, Carnelli V, Caruso V. Thromboembolic events in beta thalassemia major: an Italian multicenter study. *Acta Haematol*. 1998;99:76-79.
6. Paolino E, Monetti VC, Granieri E, Boldrini P. Acute cerebrovascular insults in homozygous beta-thalassemia: a case report. *J Neurol*. 1983;230:37-41.
7. Engelborghs S, Pickut BA, De Deyn PP. Recurrent transient ischemic attacks in a 15-year-old boy with beta-thalassemia minor and thrombophilia: contribution of perfusion SPECT to clinical diagnosis. *Acta Neurol Belg*. 2003;103:99-102.
8. Manfre L, Giarrano E, Maggio A, et al. MR imaging of the brain: findings in asymptomatic patients with thalassemia intermedia and sickle cell-thalassemia disease. *Am J Roentgenol*. 1999;173:1477-1480.
9. Zafeiriou DI, Prengler M, Gombakis N, et al. Central nervous system abnormalities in asymptomatic young patient with S β -thalassemia. *Ann Neurol*. 2004;55:835-839.
10. Eldor A, Durst R, Hy-Am E, et al. A chronic hypercoagulable state in patient with β -thalassemia major is already present in childhood. *Br J Haematol*. 1999;107:739-746.
11. Old JM, Varawalla NY, Weatherall DJ. Rapid detection and prenatal diagnosis of β -thalassemia: studies in Indian and Cypriot populations in the UK. *Lancet*. 1990;33:834-837.
12. Nowak-Gottl U, Strater R, Heinecke A, et al. Lipoprotein (a) and genetic polymorphisms of clotting factor V, prothrombin, and methylenetetrahydrofolate reductase are risk factor of spontaneous ischemic stroke in childhood. *Blood*. 1999;94:3678-3682.
13. Prengler M, Sturt N, Krywawych S, et al. Homozygous thermolabile variant of the methylenetetrahydrofolate reductase gene: a potential risk factor for hyperhomocysteinemia, CVD, and stroke in childhood. *Dev Med Child Neurol*. 2001;43:220-225.
14. Zimmerman S, Ware R. Inherited DNA mutations contributing to thrombotic complications in patients with sickle cell disease. *Am J Hematol*. 1998;59:267-272.
15. Barrano B, Bertrano G, Isaja T, et al. Plasma homocysteine is not involved in the thrombotic risk of β -thalassemia major patients. *Acta Haematol*. 2000;104:148-150.
16. Pavlovic S, Kuzmanovic M, Urosevic J, et al. Severe central nervous system thrombotic events in hemoglobin Sabine patient. *Eur J Haematol*. 2004;72:67-70.
17. Schafer AI. Thrombocytosis. *N Engl J Med*. 2004;350:1211-1219.