

Acute Midbrain Infarction in a Child With Intracranial Carotid Artery Hypoplasia and Aberrant Cerebral Vasculature: A Case Report

Ming-Ju Tsai, MD, Wei-Chen Lin, MD, Chang-Hung Kuo, MD, Hsiao-Feng Chou, MD, and Rei-Cheng Yang, MD, PhD

Strokes identified in older children typically present with sudden hemiparesis, frequent association with seizures, and occasional accompaniment of hemisensory signs or visual field defects. In this case of a left cerebral peduncle infarction, initially the patient was not found with evident right-side hemiparesis but with right-side paresthesia and mild worsening of her underlying left-side weakness, including weakness of left facial expression and left ptosis. Her right limbs became gradually weaker in the first 2 days. These bizarre clinical presentations, the mild worsening of the underlying left-side weakness, and the delayed presentation of right-side hemiparesis added to the difficulty of making a diagnosis and of the

initial localization. In addition, the magnetic resonance angiography incidentally found an abnormal vessel, which was additional and serpiginous to the right posterior fossa. The right internal carotid artery was markedly smaller than the left one, and a defect was seen around the area of the presumed distal right internal carotid artery. The abnormal cerebral vasculature might be the cause of the unique clinical presentation and might be the contributing factor to the recurrence of her stroke. In conclusion, the authors report a special case of recurrent stroke on the basis of aberrant cerebral vasculature.

Keywords: stroke; arteriovenous fistula

Stroke is defined as “the rapid developing clinical signs of focal (or global) disturbance of cerebral function, with symptoms lasting 24 hours or longer or leading to death with no apparent cause other than of vascular origin.”^{1,2} The definition includes ischemic infarction, hemorrhagic infarction, intracerebral hemorrhage, and subarachnoid hemorrhage.¹ Although stroke in children is more common than once suspected, the incidence is still much lower than that of adult stroke; it is even rarer in the brainstem.^{1,3,4} International incidence rates for childhood stroke (ie, from 30 days to 18 years of age) have ranged from 1.3 to 13 per 100 000 children.^{1,3-9} The incidence of stroke found among Chinese children is slightly lower than that in Europe or North America. The etiologic patterns between Asian and white children are

different according to a cohort study. Childhood stroke in Asian children was much less likely to be associated with sickle cell anemia, thrombophilia, or sinovenous thrombosis. Despite these differences, however, the mortality and rate of long-term neurological deficit are similar.⁷

Case Presentation

This 11-year-old girl had been well in her general status except for clumsy movements of her left limbs since childhood, which were not carefully noticed and attended by her parents due to the lack of significant disability in her daily performance. Nonetheless, this time, she was brought to our hospital because of the sudden onset of numbness over her right face and right upper limb, followed by unsteady gait tilting to her right side the next morning.

In the evening before her admission day, she went to a hair salon and had her hair done in a hyperextended posture of the neck for about 30 minutes. She felt uncomfortable in that posture, and she had noticed paresthesia (tightness sensation) of her scalp after the hairstyling process. When arriving home (about 10 minutes later), she noted the sensation of numbness over her right face and right upper limb. The symptom could not be readily relieved by loosening the hair

From the Faculty of Medicine, Medical College (M-JT), and the Department of Medical Imaging (W-CL), and Department of Pediatrics (C-HK, H-FC, R-CY), Kaohsiung Medical University Hospital, Kaohsiung, Taiwan.

Address correspondence to: Rei-Cheng Yang, MD, PhD, Department of Pediatrics, Kaohsiung Medical University Hospital, 100 Tzyou 1st Road, Kaohsiung 807, Taiwan; e-mail: rechya@kmu.edu.tw.

Tsai M-J, Lin W-C, Kuo C-H, Chou H-F, Yang R-C. Acute midbrain infarction in a child with intracranial carotid artery hypoplasia and aberrant cerebral vasculature: a case report. *J Child Neurol*. 2007;22:465-470.

rubber band. However, nothing particular happened in that night. Waking up the next morning, she had difficulty in standing, unsteady gait with mild tilting to the right side, and dysarthria. Therefore, she visited a local clinic for help and was soon referred to our hospital owing to additional mild left ptosis found there. She denied any symptom of conscious disturbance, blurred vision, double vision, headache, nausea, or vomiting.

Her birth history was as follows: she was a full-term baby delivered via cesarean section due to her cephalopelvic disproportion and her mother's previous history of cesarean section delivery. Regarding her development history, she was able to crawl around 9 months of age and able to walk around 14 months of age. However, clumsy movement of left limbs had been noticed ever since she was about 2 years old. No particular attention was paid by her parents due to the lack of definite handicap. Her school performance fluctuated but usually was below the average; no IQ evaluation had been performed because her parents did not really care. She denied any history of systemic disease, seizure, or recent head trauma. Vaccinations were completed as scheduled. Her family history is noncontributory.

Upon admission, she looked fatigued with mild ptosis of her left eye. Her vital signs were quite stable, except for a high blood pressure of 144/83 mm Hg. This rising blood pressure could not be attributed to the white-coat effect. She was alert and cooperative. Slurred speech was noticed. Her head circumference was 54 cm, which was between the 75th and 90th percentiles. Examinations on the cranial nerves showed an asymmetric facial expression with mild difficulty in opening her left eye. She was unable to fully abduct her left eye on attempted lateral gaze to the left side. Weakness and hypotrophy of left limbs were found, whereas the muscle power of her right limbs remained intact despite clinical presentation of unsteady gait tilting mildly to the right side. In addition, hyperreflexia, positive Babinski sign, and weakness of the left lower limb were obvious. Furthermore, she complained about paresthesia (numbness) of the right face and right limbs (upper greater than lower). The finger-nose-finger test showed bilateral intention tremor. Meningeal signs were negative. Other findings from the physical examination and neurological examination remained unremarkable.

A possible lesion in her brain was suspected, so computed tomography (CT) of the brain was arranged on the admission day, and it showed the following (Figure 1): (1) abnormal calcification along an abnormal vessel adjacent to the right uncus and in the ambient cistern; (2) lacunar infarct in the right thalamus with presumed Wallerian degeneration of the right cerebral peduncle; (3) asymmetric bilateral heads of caudate nuclei, with an overt atrophic right one; (4) asymmetric bilateral frontal horns of the lateral ventricles, with dilation of the right one; and (5) asymmetric middle cerebral arteries, with the right one being overtly small calibrated and showing an irregular contour.

Thereafter, magnetic resonance imaging and magnetic resonance angiography of the head were arranged on the next day for further evaluation, which showed the following (Figures 2 and 3): (1) acute infarction in the left cerebral peduncle, (2) old infarct in the right thalamus with presumed Wallerian degeneration of the right cerebral peduncle, (3) atrophy at the right aspect of the midbrain, (4) markedly smaller right internal carotid artery when compared with the left one, (5) a defect seen around the area of the presumed distal right internal carotid artery, and (6) an abnormal vessel that could have been an arteriovenous fistula connecting the right posterior communicating artery.

Electroencephalography was performed on the fourth day to survey her brain activity, and it showed focal intermittent mild voltage suppression on the right centroparietal area, indicating focal cortical dysfunction.

During her first 2 hospital days, weakness of the right limbs and dysarthria were noted and then became more and more apparent. However, her vital signs were generally stable, and her consciousness was clear, although her mood was a little depressed. The numbness over her right face and upper limb, poor facial expression, and left ptosis had been improving very slowly since the fourth hospital day. She was sleepy for both the third and fourth days. She could not control her urinary bladder completely from the fourth to the eighth days. Hoffman reflex and Babinski sign were positive on the left side throughout her hospitalization.

Since the third day, she had been given pentoxifylline to decrease blood viscosity and enhance brain perfusion. A rehabilitation program was started on the seventh day. Due to the stable general status, she was discharged after 10 days of hospitalization. After follow-up in the clinic of pediatric neurology in our hospital for 9 months, progressive partial recovery of the muscle power and nearly complete recovery of facial expression were noted. The result of the Full-Scale IQ, tested with the Wechsler Intelligence Scale for Children—Third Edition, which was done around the eighth month after admission, was 80.

Discussion

Because stroke is rare in children, it is often overlooked by pediatricians. The clinical presentations of stroke in children vary according to their age and the locations of the stroke.⁸ The presentations of pediatric stroke in the emergency department do not differ greatly from that of adults, although the incidence of posterior circulation ischemia is less common, and neurological findings may be more difficult to recognize.¹⁰ Strokes identified in older children are typically presented as sudden hemiparesis, often associated with seizures and sometimes accompanied by hemisensory signs or visual field defects.^{3,11} However, if an underlying central nervous system abnormality is present, achieving a diagnosis becomes more difficult.

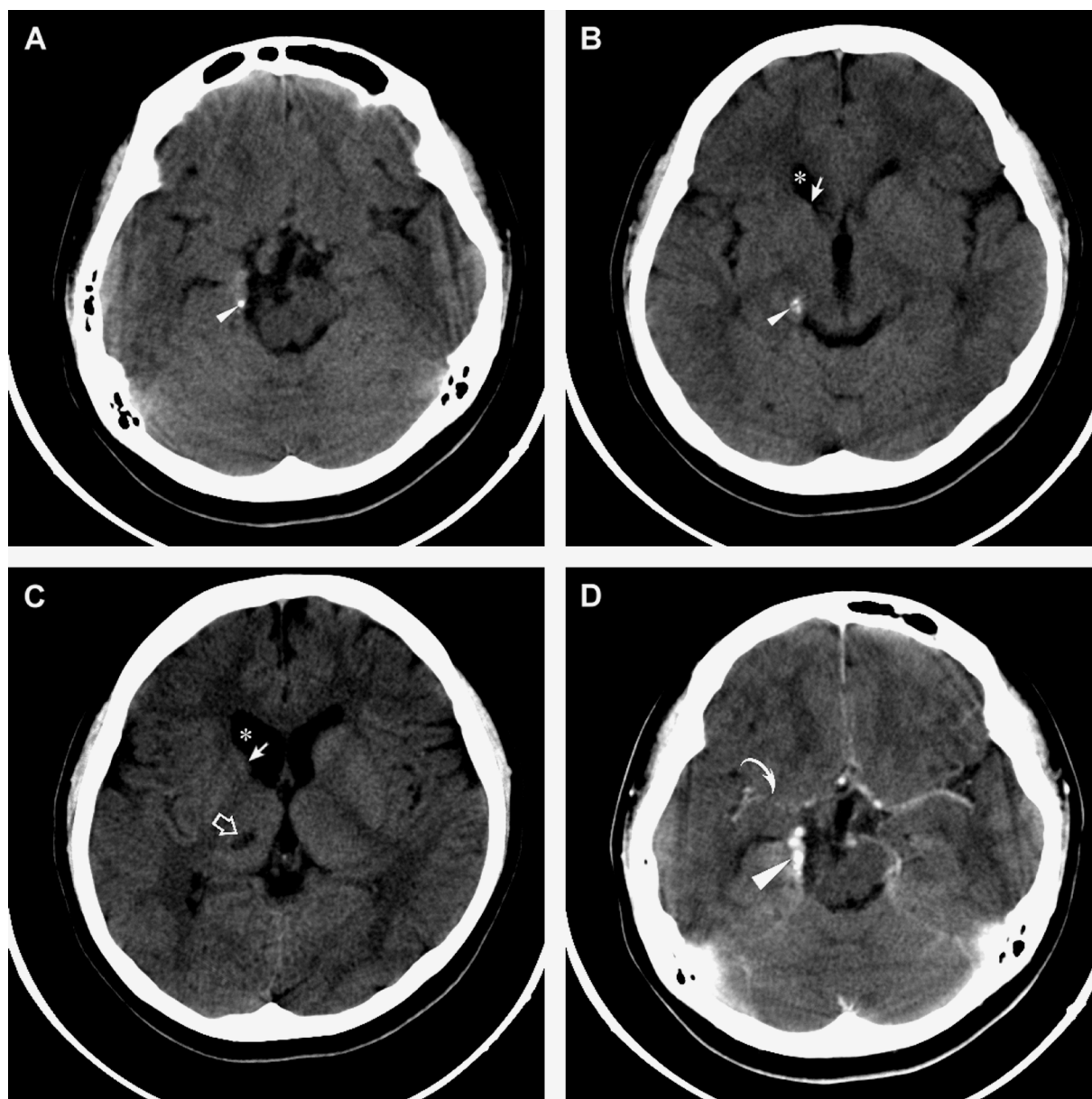


Figure 1. Noncontrast axial computed tomography (CT) images of the brain (A-C) revealed (1) abnormal calcification (small arrowheads) adjacent to the right uncus and in the ambient cistern; (2) lacunar infarct (open arrow) in the right thalamus with presumed Wallerian degeneration of the right cerebral peduncle; (3) asymmetric bilateral heads of caudate nuclei, with an overt atrophic right one (arrows); and (4) asymmetric bilateral frontal horns of the lateral ventricles, with dilation of the right one (*). Contrast-enhanced axial CT images of the brain (D) revealed that the abnormal calcification is along an abnormal vessel (large arrowhead), the middle cerebral arteries are asymmetric, and the right middle cerebral artery (curved arrow) is overtly small calibrated and shows irregular contour.

In this case of left cerebral peduncle infarction, the presentation of right-side hemiparesis was not obvious on the day of the admission; she initially displayed the clinical pictures of right-side paresthesia and mild worsening of underlying left-side weakness, including weakness of left facial expression and left eye ptosis. The bizarre clinical presentation was not easy for the initial localization. Her right limbs became gradually weaker in the first 2 days. The mild worsening of the underlying left-side weakness and the

delayed presentation of right-side hemiparesis made the process of diagnosis much more challenging.

Radiological study was of diagnostic values. Computed tomography showed a small hypodense lesion in the right thalamus, suggesting old infarct in the right thalamus. The head of the right caudate nucleus and the right aspect of the brainstem were relatively smaller in size. Magnetic resonance imaging confirmed the above findings. Electroencephalography also suggested focal cortical dysfunction on

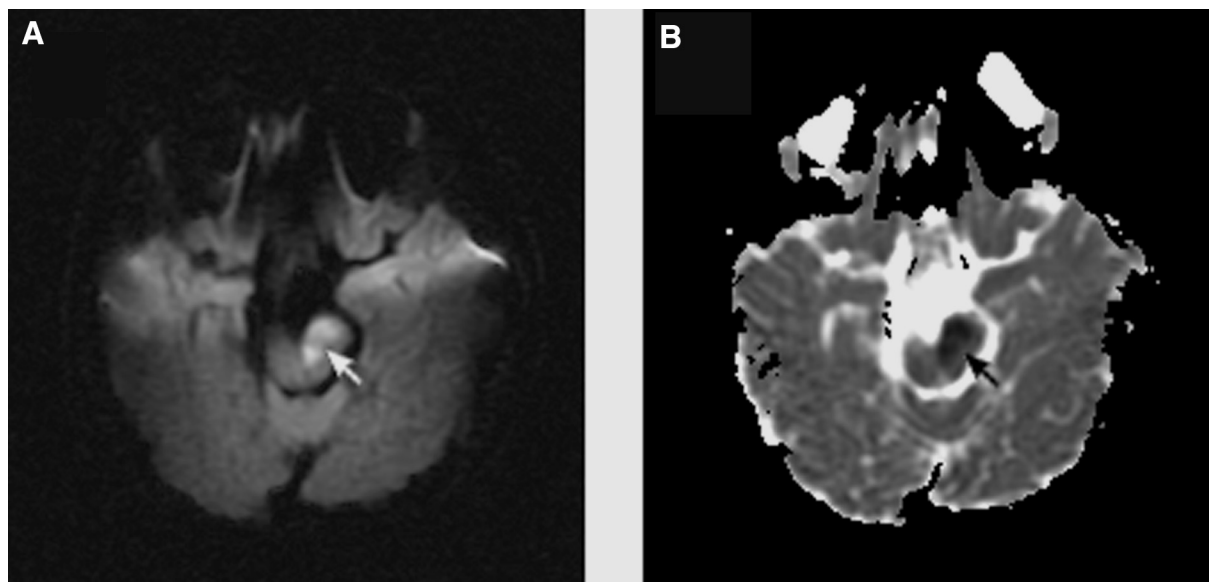


Figure 2. Diffusion-weighted axial magnetic resonance image (DWI, repetition time = 8000 ms, echo time = 71.7 ms, $b = 1000$) (A) and apparent diffusion coefficient (ADC) map (B) showed acute infarct in the left cerebral peduncle (arrows) with characteristic hyperintensity on DWI and hypointensity on the ADC map.

the right side. Therefore, it is not surprising that she has had left-side weakness for a long time. These images and electroencephalographic findings of the old lesions correlated well with her clinical manifestations but did not show any evidence of an acute stroke.

Although multiparametric stroke CT (combining non-contrast-enhanced CT, perfusion CT, and CT angiography) can give nearly equivalent information when stroke magnetic resonance imaging is not available, diffusion-weighted magnetic resonance imaging is still more sensitive than CT for early detection of acute ischemia.¹²⁻¹⁴ In our case, a lesion in the left cerebral peduncle, with high signal intensity on the diffusion-weighted image, exponential apparent diffusion coefficient map, and T2-weighted image, and with low signal intensity on the apparent diffusion coefficient map, which are typical image findings of an acute stroke, suggested an infarction in the left cerebral peduncle. The image findings correlated well with clinical symptoms and signs, which were numbness over the right face and the right limbs and mild left ptosis followed by right-side hemiparesis.

Accidentally, an abnormal vessel, which is additional and serpiginous to the right posterior fossa, was noted on magnetic resonance angiography. The arteriovenous fistula connecting the right posterior communicating artery was impressed. The right internal carotid artery was markedly smaller than the left one, and a defect was seen around the area of the presumed distal right internal carotid artery. Cerebral blood flow feeding from the left side to the right side was highly suspected. Although magnetic resonance

angiography is a noninvasive yet sensitive enough modality to provide an adequate initial evaluation of arterial brain disease in childhood, further catheter angiography is still indicated in this case for further definitive diagnosis.^{15,16} Computed tomography angiography is relatively noninvasive and is able to provide a 3D reconstruction image with very high resolution, but it cannot provide the information about the direction of the blood flow, and thus the hemodynamics cannot be confirmed. Comparatively, catheter angiography is relatively invasive, but it can provide the real-time information about the blood flow.

The abnormal cerebral vasculature may give us a clue for explaining the unique clinical presentation of our case. In our opinion, the right side of her brain was partially supplied by the cross-feeding blood flow from the left side, which was vulnerable to a decrease in the blood flow. Therefore, the initial presentation of mild worsening of the underlying left-side weakness preceding the development of the right-side weakness may have resulted from a decrease in the cerebral cross-feeding blood flow from the left side to right side.

When compared with adults, the pediatric population has a much more diverse group of risk factors, and although numerous rare congenital disorders have to be taken into consideration, most known etiologies are cardiac, vascular, or hematologic.¹⁰ Although many different causes and potential risk factors for childhood stroke have been described, ischemic stroke in children frequently results from cardiac embolism, nonatherosclerotic vasculopathies, or prothrombotic states.¹ Some physicians also

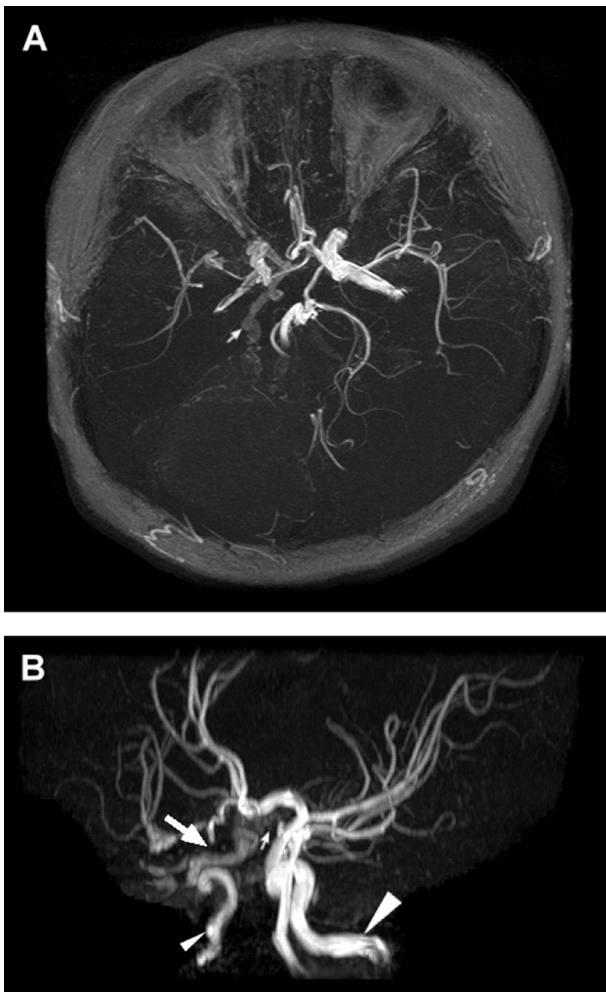


Figure 3. Collapsed view of 3D time-of-flight magnetic resonance angiography (A) and maximum intensity projection image of magnetic resonance angiography (B) showed (1) the right internal carotid artery (small arrowhead), which is markedly smaller than the left one (large arrowhead); (2) a defect (large arrow) seen around the area of the presumed distal internal carotid artery; and (3) an abnormal vasculature (small arrows) that may be an arteriovenous fistula connecting the right posterior communicating artery.

have described some other causes for strokes in children, including chiropractic manipulation of the cervical spine, hypertriglyceridemia, idiopathy, and so on.¹⁷⁻¹⁹ Moreover, recurrent strokes are significantly more frequent in children with multiple risk factors, including those with demonstrable vascular abnormalities.¹⁶ Nonetheless, in our case, there was no significant abnormality of her coagulation profile; therefore, it was highly suspected that the hyperextension posture as well as the underlining cerebral vascular abnormality might be the contributing factor to the recurrence of her stroke.

There are no randomized clinical trials for primary prevention, short-term treatment, or secondary prevention of

pediatric ischemic stroke. Current recommendations for treatment are based on small case series or case reports and mainly have been adapted from studies of adult stroke.²⁰ Given the causes and outcomes of stroke in children, this age group might benefit from thrombolysis and neuroprotective therapy, yet the long delay in diagnosis in this age group due to the rarity of stroke, the low sensitivity of CT for diagnosing an acute infarction, and the wide difference in the presentation in this age group exclude most cases from being considered for such treatments.^{3,21} In addition, intravascular thrombolysis is controversial, and the efficacy has not yet been established for pediatric patients.¹ Aspirin appears to be associated with a modest improvement in the outcome in 2 very large controlled trials in adults, but further studies in children would be needed in view of the additional risk of Reye syndrome.³ Therefore, conservative treatment was adapted in our case. The outcome was satisfying.

Although the prognosis of pediatric stroke is better than that of adult stroke, neurological and especially neuropsychological long-term problems significantly influence the lives of these children.^{22,23} Recurrence occurs in about 20% of the children.^{1,24-26} Raised lipoprotein (a), protein C deficiency, and stroke of vascular origin are the risk factors for recurrent arterial ischemic stroke in children.²⁷ For ischemic stroke, long-term prevention for recurrence is a controversial issue.³ Appropriate screening for modifiable risk factors may lead to the initiation of preventative steps for recurrence in some patients.²³ For patients with cerebrovascular disease, low-dose aspirin is probably justified, but the question of the risk of Reye syndrome is important in children. In our case, pentoxifylline was prescribed to decrease the blood viscosity and enhance the brain perfusion, but the effect still needs to be determined.

Stroke in children is rarely diagnosed in the time frame between 3 to 6 hours.²¹ The current situation of delay in diagnosis should encourage attempts to increase public and professional awareness of stroke in children, as well as the potential value of early diagnosis and treatment, preferably by broadening current educational efforts to all age groups.²¹ In the long term, an understanding of the multiple etiologies of childhood cerebrovascular disease and ischemic stroke may lead to primary prevention in this age group and perhaps in adults.²³ In conclusion, we report a special case of recurrent stroke on the basis of aberrant cerebral vasculature. Through a literature review, no similar case was reported before. Stroke in the midbrain should be considered in the differential diagnosis of sudden-onset paresthesia or weakness, even in a child.

Acknowledgment

We express our appreciation to Dr Joanna Ying-Jiin Chen for her assistance in editing this article.

References

1. Carvalho KS, Garg BP. Arterial strokes in children. *Neurol Clin N Am*. 2002;20:1079-1110.
2. Thorvaldsen P, Asplund K, Kuulusmaa K, et al. Stroke incidence, case fatality, and mortality in the WHO MONICA Project. World Health Organization Monitoring Trends and Determinants in Cardiovascular Disease. *Stroke*. 1995;26:361-367.
3. Kirkham FJ. Stroke in childhood. *Arch Dis Child*. 1999;81:85-89.
4. Cheng WW, Ko CH, Chan AK. Paediatric stroke: case series. *Hong Kong Med J*. 2002;8:216-220.
5. Broderick J, Talbot T, Prenger E, et al. Stroke in children within a major metropolitan area: the surprising importance of intracerebral hemorrhage. *J Child Neurol*. 1993;8:250-255.
6. Schoenberg BS, Mellingier JF, Shoenberg DG. Cerebrovascular disease in infants and children: a study of incidence, clinical features and survival. *Neurol*. 1978;28:763-768.
7. Chung B, Wong V. Pediatric stroke among Hong Kong Chinese subjects. *Pediatrics*. 2004;114:e206-e212.
8. Lynch JK. Cerebrovascular disorders in children. *Curr Neurol Neurosci Rep*. 2004;4:129-138.
9. deVeber G. Arterial ischemic strokes in infants and children: an overview of current approaches. *Semin Thromb Hemost*. 2003;29:567-573.
10. Calder K, Kokorowski P, Tran T, Henderson S. Emergency department presentation of pediatric stroke. *Pediatr Emerg Care*. 2003;19:320-328.
11. Lanska MJ, Lanska DJ, Horwitz SJ, Aram DM. Presentation, clinical course, and outcome of childhood stroke. *Pediatr Neurol*. 1991;7:333-341.
12. Schramm P. CT diagnosis in acute cerebral ischemia [in German]. *Radiologe*. 2005;45:420, 422-429.
13. Gonzalez RG, Schaefer PW, Buonanno FS, et al. Diffusion-weighted MR imaging: diagnostic accuracy in patients imaged within 6 hours of stroke symptom onset. *Radiology*. 1999;210:155.
14. Oliveira-Filho J, Koroshetz WJ. Neuroimaging of acute ischemic stroke. In: Rose BD, ed. *UpToDate*. Waltham, Mass: UpToDate; 2005.
15. Husson B, Rodesch G, Lasjaunias P, et al. Magnetic resonance angiography in childhood arterial brain infarcts: a comparative study with contrast angiography. *Stroke*. 2002;33:1280-1285.
16. Husson B, Lasjaunias P. Radiological approach to disorders of arterial brain vessels associated with childhood arterial stroke: a comparison between MRA and contrast angiography. *Pediatr Radiol*. 2004;34:10-15.
17. Braun IF, Pinto RS, De Filipp GJ, et al. Brain stem infarction due to chiropractic manipulation of the cervical spine. *South Med J*. 1983;76:1199-1201.
18. Yamanouchi H, Seki Y, Yanagisawa T, et al. Two cases of brain infarction associated with hypertriglyceridemia [in Japanese]. *No To Hattatsu*. 1990;4:364-368.
19. Curless RG. Idiopathic ischemic infarction of the brain stem in children. *Childs Nerv Syst*. 1991;7:305-308.
20. Nowak-Gottl U, Straeter R, Sebire G, Kirkham F. Antithrombotic drug treatment of pediatric patients with ischemic stroke. *Paediatr Drugs*. 2003;5:167-175.
21. Gabis LV, Yangala R, Lenn NJ. Time lag to diagnosis of stroke in children. *Pediatrics*. 2002;110:924-928.
22. Steinlin M, Roellin K, Schroth G. Long-term follow-up after stroke in childhood. *Eur J Pediatr*. 2004;163:245-250.
23. De Schryver EL, Kappelle LJ, Jennekens-Schinkel A, Boudewyn Peters AC. Prognosis of ischemic stroke in childhood: a long-term follow-up study. *Dev Med Child Neurol*. 2000;42:313-318.
24. Bjornstad A, Skjeldal OH. Ischemic stroke in children: a diagnostic challenge [in Norwegian]. *Tidsskr Nor Laegeforen*. 2001;121:1826-1828.
25. Ganesan V, Chong WK, Cox TC, et al. Posterior circulation stroke in childhood: risk factors and recurrence. *Neurology*. 2002;59:1552-1556.
26. Kirkham FJ, Prengler M, Hewes DK, Ganesan V. Risk factors for arterial ischemic stroke in children. *J Child Neurol*. 2000;15:299-307.
27. Strater R, Becker S, von Eckardstein A, et al. Prospective assessment of risk factors for recurrent stroke during childhood: a 5-year follow-up study. *Lancet*. 2002;360:1540-1545.