

Ischemia of the Internal Capsule due to Mild Head Injury in a Child

S. Nabika K. Kiya H. Satoh T. Mizoue J. Oshita H. Kondo

Department of Neurosurgery, Hiroshima Prefectural Hospital, Hiroshima, Japan

Key Words

Hemiparesis · Internal capsule ischemia · Mild head injury · Susceptibility-weighted imaging · Vasospasm

Abstract

We encountered an instructive case of repetitive reversible severe neurological deficit due to ischemia of the internal capsule after mild head injury. A 1-year-old boy fell and hit his head on the floor without losing consciousness. Intermittent episodes of left hemiparesis lasting from 30 s to 30 min developed 4 h later. Magnetic resonance (MR) imaging revealed acute infarction in the left internal capsule and corona radiata on diffusion-weighted imaging, and no microbleeding on susceptibility-weighted imaging. MR angiography of the intracranial and cervical vessels showed no obstruction of the large cerebral arteries. Motor impairment began to improve the next day with conservative therapy. Neurological deficit gradually resolved over the course of 1 month. This tiny lesion of the internal capsule and corona radiata may have represented a small infarction caused by mechanical vasospasm of the perforating vessels branching from the middle cerebral artery after minor injury. Even mild head injuries may cause infarction of the internal capsule, although minor head injuries are common accidents in childhood and usually do not result in severe complications.

Copyright © 2007 S. Karger AG, Basel

Introduction

Mild head injuries, mostly presenting as brain concussion, are common accidents and usually do not result in severe complications. However, infarction of the internal capsule after mild head injury has rarely been described in children [1–5]. We encountered an instructive case involving repetitive reversible severe neurological deficit after mild head injury, arising from ischemia of the internal capsule.

Case Report

A 1-year-old boy at kindergarten tripped over a baseball and lost his balance. He hit his left temporal side slightly at the right angle with the carpeted floor. The accident was an acceleration injury. The child did not lose consciousness following the accident, but as of 4 h later developed intermittent episodes of left-sided weakness involving the leg and arm lasting for 30 s to 30 min. Consciousness was unimpaired during these episodes, and he appeared well between episodes. He was transferred from another hospital to our hospital 10 h after the accident for further investigations. Computed tomography revealed only thin acute epidural hematoma in the posterior fossa. Repeated episodes of left-sided hemiparesis were still occurring at this stage. Magnetic resonance (MR) imaging revealed acute infarction of the left internal capsule and corona radiata on diffusion-weighted (DW) and susceptibility-weighted (SW) imaging (fig. 1, 2). MR angiography of the intracranial and cervical vessels failed to demonstrate either obliteration or stenosis of the large cerebral arteries (fig. 3). Conservative therapy resulted in symptomatic improve-

Fig. 1. MR imaging revealed acute infarction of the left basal ganglia and corona radiata on DW imaging.

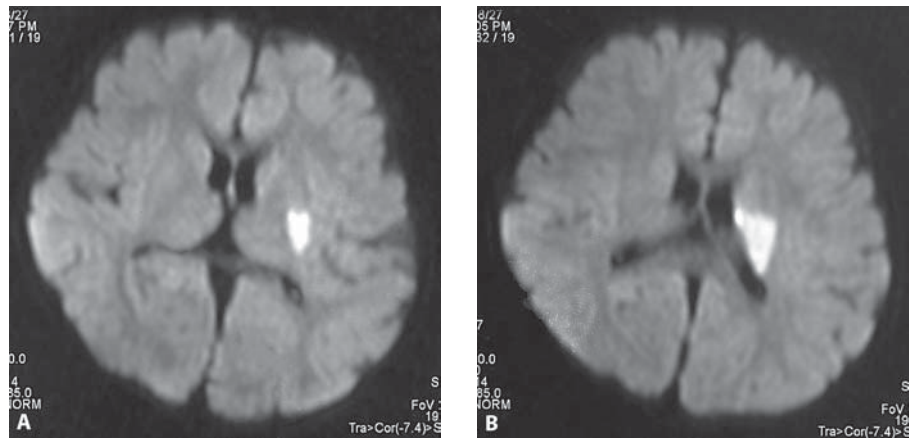


Fig. 2. MR imaging revealed no microbleeding on SW imaging.

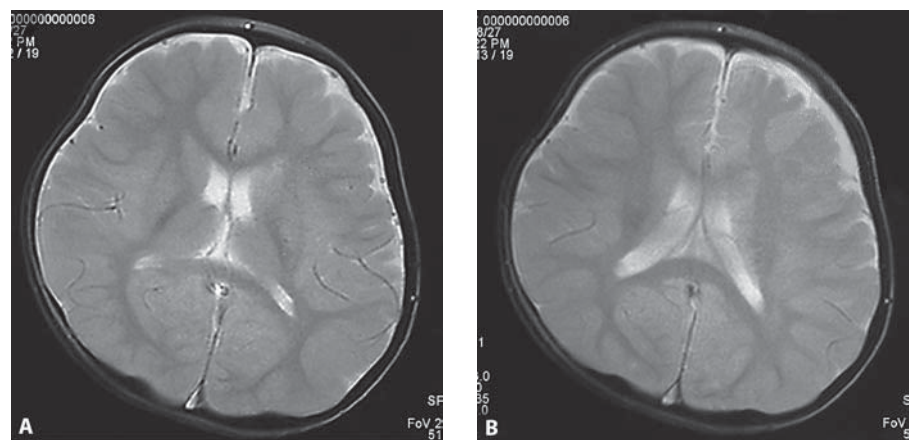


Fig. 3. Head MR angiography revealed neither obliteration nor stenosis of the large cerebral arteries.

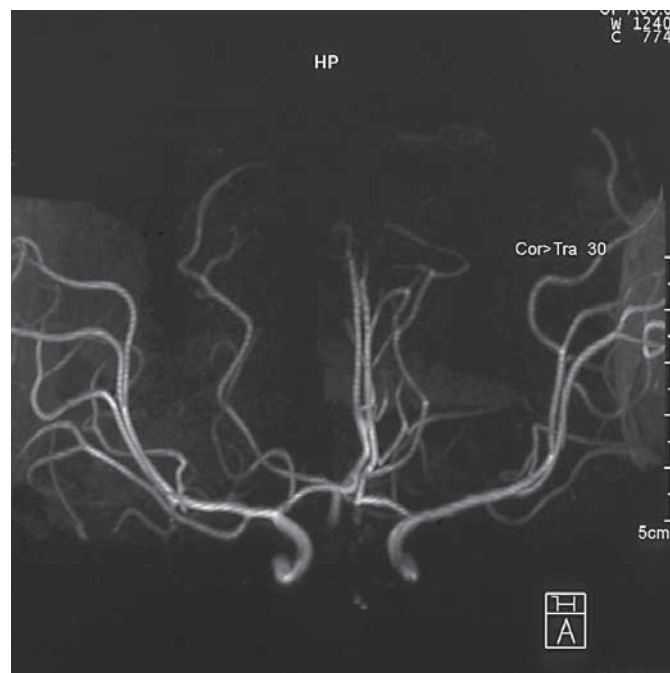


Fig. 4. MR imaging performed 2 weeks after the accident revealed complete infarction of the left basal ganglia and corona radiata on fluid-attenuated inversion recovery imaging.

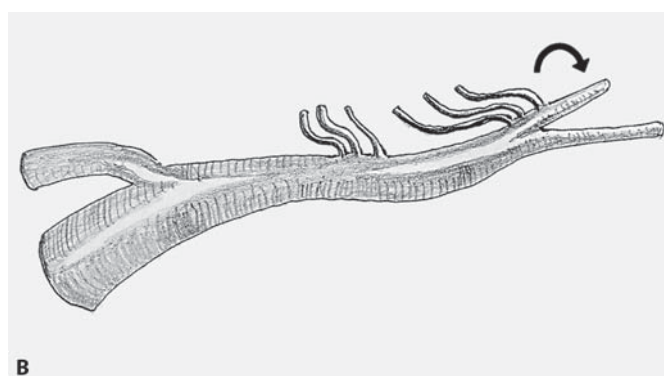
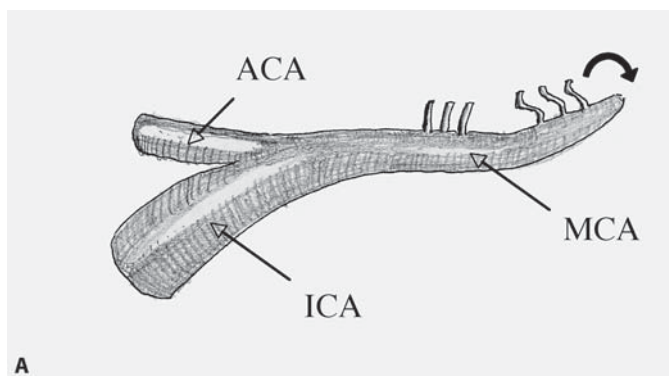
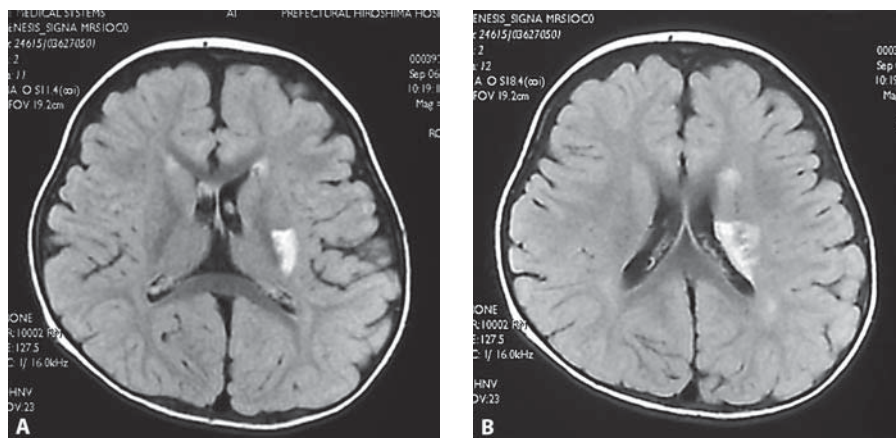


Fig. 5. The divergence angle with the anatomical trunk of the middle cerebral artery and lenticulostriate branches is more acute in a child (A) than in an adult (B), and the length of these extracerebral segments also tends to be shorter in a child than in an adult. ICA = Internal carotid artery; ACA = anterior cerebral artery; MCA = middle cerebral artery.

ments starting from the next day, and a full recovery was made within 1 month. MR imaging 2 weeks after the accident revealed complete infarction of the left internal capsule and corona radiata on fluid-attenuated inversion recovery imaging (fig. 4).

Discussion

The Mild Traumatic Brain Injury Interdisciplinary Special Interest Group of the American Congress of Rehabilitation Medicine defined mild traumatic brain injury using the following criteria: (1) loss of consciousness should not exceed 30 min; (2) after 30 min the initial Glasgow Coma Scale score should be between 13 and 15, and (3) posttraumatic amnesia should not exceed 24 h [6]. Mild head injury can sometimes cause diffuse axonal injury (DAI). DW imaging has proven to be highly sensi-

tive to detecting early cytotoxic edema against a background of acute stroke [5], and has recently allowed identification of DAI [7]. SW imaging is also useful in detecting hemorrhagic lesions, which occur in 10–30% of patients with DAI [8–10]. In the present case, initial MR imaging revealed areas of hyperintensity in the internal capsule on DW imaging, but no abnormal changes on SW imaging. This finding suggests the lesion represents non-hemorrhagic DAI or cerebral infarction. Considering the repetitive transient hemiparesis without any disturbance of consciousness, the lesion may represent a small infarction resulting from injury to the perforating branch of the middle cerebral artery or transient edema, rather than DAI.

This syndrome appears to be confined to young children for various reasons. For a start, the basal ganglia and

internal capsule are supplied by the lenticulostriate branches of the middle cerebral artery. The anatomical relationship between the lenticulostriate arteries and the trunk of the middle cerebral artery changes from fetal life, through childhood to adulthood. The angle between the main middle cerebral artery and the lenticulostriate arteries is more acute, the length of these extracerebral segments also tends to be shorter in younger individuals (fig. 5) [11, 12], and these arteries are functional end arteries. The territory of this branch is thus mechanically vulnerable to ischemia as a result of vascular occlusion or mechanical spasm following arterial disruption, even following mild head injury [1, 3, 13–15]. In the present case, recurrent episodes of transient but reversible hemiparesis would be consistent with intermittent arterial spasm.

In previous reports, most children who experienced infarction after mild head injury recovered completely

following conservative therapy [1, 3, 9]. Neuronal plasticity during childhood, the theory describing the cellular potential for damaged neurons to recover and healthy neurons to reorganize, can account for dramatic recovery following brain injuries. Research supports the theory of plasticity and reorganization and demonstrates the remarkable potential for recovery of functioning following focal lesions such as in the motor cortex and auditory cortex [16–19]. Immediate restoration of circulation, which occurs after vasogenic edema is reduced, may explain the early and usually complete recovery, despite the development of persistent infarction.

Minor head injuries may cause cerebral infarction at the internal capsule due to mechanical vasospasm of the perforating vessels, although ischemic symptoms are not so severe and tend to disappear in the early period.

References

- 1 Dharker SR, Mittal RS, Bhargava N: Ischemic lesion in basal ganglia in children after minor head injury. *Neurosurgery* 1993;33:863–865.
- 2 Kieslich M, Fiedler A, Heller C, Kreuz W, Jacobi G: Minor head injury as cause and cofactor in the aetiology of stroke in childhood: a report of eight cases. *J Neurol Neurosurg Psychiatry* 2002;73:13–16.
- 3 Kuroiwa T, Tanabe H, Takatsuka H, Arai M, Ozaki T, Nagasawa S, Ohta T: Paramedian thalamic infarction following blunt head injury. *Neurol Med Chir (Tokyo)* 1994;34:20–22.
- 4 Muthukumar N: Basal ganglia-internal capsule low density lesions in children with mild head injury. *Br J Neurosurg* 1996;10:391–393.
- 5 Provenzale JM, Sorensen AG: Diffusion-weighted MR imaging in acute stroke: theoretical considerations and clinical applications. *AJR Am J Roentgenol* 1999;173:1459–1467.
- 6 Mild Traumatic Brain Injury Committee of the Head Injury Interdisciplinary Special Interest Group of the American Congress of Rehabilitation Medicine: Definition of mild traumatic brain injury. *J Head Trauma Rehabil* 1993;8:86–87.
- 7 Schaefer PW, Sorensen AG, Gonzales RG, Schwamm LH: Diffusion-weighted MR imaging in closed head injury: high correlation with initial Glasgow coma scale score and score on modified Rankin scale at discharge. *Radiology* 2004;233:58–66.
- 8 Fiebich JB, Schellinger PD, Grass A, Kucinski T, Siebler M, Villringer A, Olkers P, Hirsch JG, Heiland S, Wilde P, Jansen O, Rother J, Hacke W, Sartor K, for the Kompetenznetzwerk Schlaganfall B5: Stroke magnetic resonance imaging is accurate in hyperacute intracerebral hemorrhage: a multicenter study on the validity of stroke imaging. *Stroke* 2004;35:502–507.
- 9 Hermier M, Nighoghossian N: Contribution of susceptibility-weighted imaging to acute stroke assessment. *Stroke* 2004;35:1989–1994.
- 10 Lin DD, Filippi CG, Steever AB, Zimmerman RD: Detection of intracranial hemorrhage: comparison between gradient-echo images and b(0) images obtained from diffusion-weighted echo-planar sequences. *AJNR Am J Neuroradiol* 2001;22:1275–1281.
- 11 Kodama N, Suzuki J: Cerebrovascular moyamoya disease. 3. The study of aging of the perforating branches and the possibility of collateral pathways. *Neurol Med Chir (Tokyo)* 1974;14:55–57.
- 12 Umansky F, Gomes FB, Dujovny M, Diaz FG, Ausman JI, Mirchandani HG, Berman SK: The perforating branches of the middle cerebral artery. A microanatomical study. *J Neurosurg* 1985;62:261–268.
- 13 Brett EM, Hoare RD: Progressive hemidystonia due to focal basal ganglia lesion after mild head trauma. *J Neurol Neurosurg Psychiatry* 1981;44:460.
- 14 Krauss JK, Mohadjer M, Braus DF, Wakhloo AK, Nobbe F, Mundinger F: Dystonia following head trauma: a report of nine patients and review of the literature. *Mov Disord* 1992;7:263–272.
- 15 Shaffer L, Rich PM, Pohl KR, Ganesan V: Can mild head injury cause ischemic stroke? *Arch Dis Child* 2003;88:267–269.
- 16 Elbert T, Pantev C, Wienbruch C, Rockstroh B, Traub E: Increased cortical representation of the fingers of the left hand in string players. *Science* 1995;270:305–307.
- 17 Johnston MV, Nishimura A, Harum K, Pekar J, Blue ME: Sculpting the developing brain. *Adv Pediatr* 2001;48:1–38.
- 18 Sharma A, Dorman MF, Spahr AJ: A sensitive period for the development of the central auditory system in children with cochlear implants: implications for age of implantation. *Ear Hear* 2002;23:532–539.
- 19 You SH, Jang SH, Kim YH, Kwon YH, Barrow I, Hallett M: Cortical reorganization induced by virtual reality therapy in a child with hemiparetic cerebral palsy. *Dev Med Child Neurol* 2005;47:628–635.

Copyright: S. Karger AG, Basel 2007. Reproduced with the permission of S. Karger AG, Basel.
Further reproduction or distribution (electronic or otherwise) is prohibited without permission
from the copyright holder.