

Spontaneous Thrombosis of a Venous Malformation Leading to Intracerebral Hemorrhage

—Case Report—

Yukio SEKI and Yoshiyuki SAHARA

Department of Neurosurgery, Chubu Rosai Hospital, Nagoya

Abstract

A 33-year-old man presented with consciousness disturbance (Glasgow Coma Scale score 7) and right hemiplegia after suffering headache persisting for 10 days. Head computed tomography revealed an irregular intracerebral hematoma in the left temporoparietal region, associated with a tubular high density area compatible with a thrombosed transcerebral vein in the left temporal lobe. The patient was free of coagulopathy. Craniectomy was performed to remove the intracerebral hematoma and venous thrombosis was confirmed. Postoperative cerebral angiography demonstrated extensive venous malformation in the left parietal and occipital lobes. Multiple transcerebral draining veins converged in the vein of Galen associated with a varix. Segmental narrowing of the straight sinus was suggestive of congestion in the venous anomaly. The patient showed progressive recovery following surgery, and was discharged with moderate aphasia, mild right hemiparesis, and right homonymous hemianopsia 1 month later. Venous malformations are usually silent, but occasionally become symptomatic due to thrombosis of the draining vein. The presence of stenosis in the draining route may lead to venous congestion, thrombus formation, and catastrophic hemorrhagic venous infarct.

Key words: intracerebral hemorrhage, venous malformation, venous thrombosis

Introduction

Venous malformations consist of a series of small deep medullary vessels that converge into an enlarged central venous channel. Venous malformations are the most common type of cerebrovascular malformations, and are formed by the persistence of the early embryological pattern of venous drainage.^{15,17)} Clinically, venous malformations are only rarely associated with hemorrhage, seizures, and transient focal neurological deficits, so are recognized as relatively benign.^{3,14,15)} Venous malformations occasionally become symptomatic due to thrombosis of the draining vein. The cause of such venous thrombosis is not fully understood.

We describe a case of extensive venous malformation complicated by hemorrhagic venous infarct.

Case Report

A 33-year-old man presented with consciousness

disturbance after suffering headache persisting for 10 days. His initial Glasgow Coma Scale score was 7 (E1V1M5). He had right hemiplegia and his left pupil was dilated. Head computed tomography (CT) showed an irregular intracerebral hematoma in the left temporoparietal region causing marked midline shift to the right, and a tubular high density area in the left temporal lobe (Fig. 1A). CT with contrast medium showed no arteriovenous malformation. The configuration of the tubular high density lesion on coronal and sagittal reconstruction images was suggestive of a thrombosed draining vein of a venous malformation (Fig. 1B, C).

Emergency craniectomy was performed to remove the intracerebral hematoma. Venous thrombosis suggested by CT was confirmed at surgery leading to a diagnosis of hemorrhagic venous infarct (Fig. 2). The patient did not suffer from coagulopathy, and routine laboratory tests, including hematology and coagulation studies, found no abnormalities. He remained confused and restless for 1 week, but then showed progressive recovery in consciousness level as well as motor and verbal functions.

Received November 1, 2006; Accepted April 6, 2007

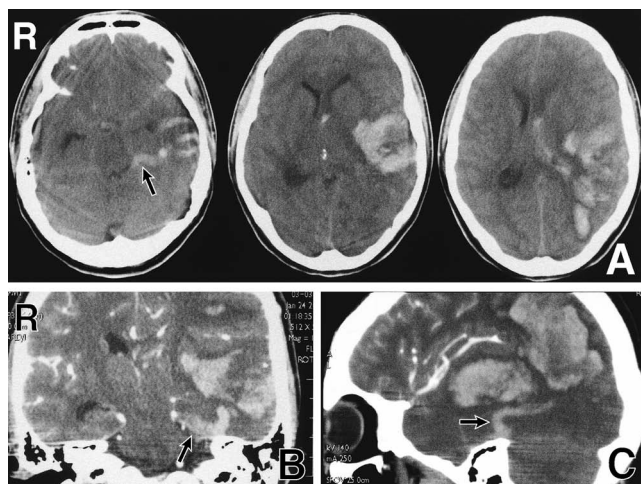


Fig. 1 Computed tomography (CT) scans on admission (A) showing an irregular high density area compatible with hemorrhagic infarction in the left temporoparietal region associated with midline shift to the right, and a tubular high density area in the temporal lobe indicating vessel thrombosis (arrow). Coronal (B) and sagittal (C) reconstruction CT scans with contrast medium showing the three-dimensional configuration (arrow) of the tubular high density area indicative of a transcerebral draining vein of a venous malformation.

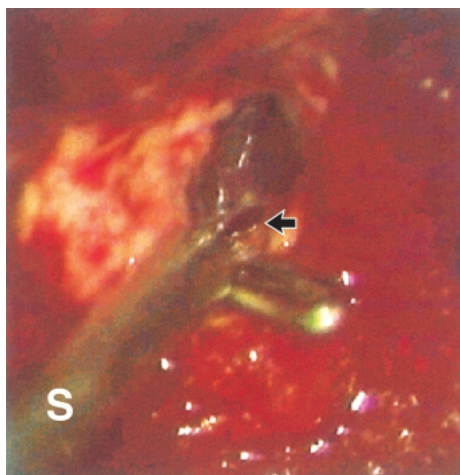


Fig. 2 Intraoperative photograph showing venous thrombosis. The venous wall was opened and thrombus was confirmed (arrow). S: suction tube.

Digital subtraction angiography was performed on Day 14. Left carotid angiography demonstrated the typical “caput medusae” appearance of a venous

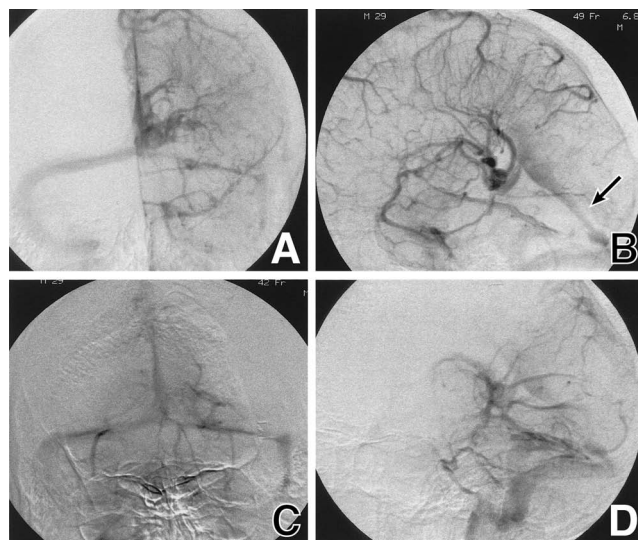


Fig. 3 Left carotid angiograms on Day 14, anteroposterior (A) and lateral (B) projections in the venous phase, showing the typical “caput medusae” appearance of a venous malformation in the left parietal region and draining into the vein of Galen associated with a varix, with segmental narrowing of the straight sinus in its posterior portion (arrow). Left vertebral angiograms, anteroposterior (C) and lateral (D) projections in the venous phase, showing multiple transcerebral veins in the left occipital lobe coursing toward the vein of Galen. The medullary veins are less prominent in this region.

malformation in the parietal lobe, which drained into the vein of Galen associated with a varix. Vertebral angiography also demonstrated multiple transcerebral draining veins coursing toward the vein of Galen. The anterior one third of the straight sinus was dilated and the remainder showed narrowing (Fig. 3). The arterial phases showed no abnormality. Following cranioplasty, he was discharged with moderate aphasia, mild right hemiparesis, and right homonymous hemianopsia 1 month later.

Discussion

Coexisting cavernous malformations rather than venous malformations have been suggested as the cause of intracerebral hemorrhage.¹⁴⁾ However, the present case shows that venous malformation can cause bleeding in the form of hemorrhagic venous infarct. The clinical history of headache persisting for 10 days prior to the ictus suggested the progression of venous thrombosis.

Table 1 Reported cases of venous malformations complicated by thrombosis of the draining vein

Author (Year)	Age (yrs)/ Sex	Location of venous malformations	Intra-cerebral hemorrhage
Bouchacourt et al. (1986) ¹⁾	37/F	lt frontal	–
Yamamoto et al. (1989) ¹⁶⁾	26/F	rt parietal	+
Field and Russell (1995) ²⁾	34/F	rt temporal	+
Kim et al. (1996) ⁶⁾	13/M	rt temporal	+
Merten et al. (1998) ¹¹⁾	50/F	lt para-ventricular	+
Konan et al. (1999) ⁷⁾	31/M	bil cerebellum	–
Lai et al. (1999) ⁸⁾	56/M	rt parietal	–
Herbreteau et al. (1999) ⁵⁾	45/M	lt parietal	–
Thobois et al. (1999) ¹³⁾	25/F	rt parietal	–
Masson et al. (2000) ¹⁰⁾	43/M 68/M	lt parietal lt frontal	– –
Hammoud et al. (2002) ⁴⁾	26/F	lt fronto-parietal	–
Peltier et al. (2004) ¹²⁾	32/M	lt cerebellum	–
Present case	33/M	lt temporo-parieto-occipital	+

Venous malformations complicated by thrombosis of the draining vein occur mainly in young and middle-aged adults (Table 1).^{1,2,4-8,10-13,16)} Anticoagulation has resulted in good clinical outcomes.^{10,11,13)} However, the cause of the venous thrombosis is not fully understood. Focal stenosis of the draining vein might be responsible for the venous thrombosis.^{1,15)} In the present case, any presence of stenosis in the thrombosed vein was not known. On the other hand, cerebral angiography demonstrated stenosis in the posterior two thirds of the straight sinus. The straight sinus was the main draining route of the extensive venous malformation, so appeared too small to drain the venous blood smoothly. The presence of a venous varix in conjunction with the vein of Galen also suggests increased venous pressure caused by this stenosis.⁹⁾ Turbulent and restricted flow in the varix might have predisposed the converging transcerebral veins to formation of thrombosis. The cause of this stenosis is unclear. Coexisting dilation of the anterior part of the straight sinus may suggest congenital origin of the stenosis.

Venous malformations occasionally give rise to significant symptoms due to thrombosis of the draining vein. The presence of a stenosis in the draining route may be a predisposing factor.

Acknowledgments

We thank Mr. Hiromitsu Ukai for his help in figure preparation.

References

- 1) Bouchacourt E, Carpena JP, Bories J, Koussa A, Chiras J: [Ischemic accident caused by thrombosis of a venous angioma. Apropos of a case]. *J Radiol* 67: 631-635, 1986 (Fre, with Eng abstract)
- 2) Field LR, Russell EJ: Spontaneous hemorrhage from a cerebral venous malformation related to thrombosis of the central draining vein: demonstration with angiography and serial MR. *AJNR Am J Neuroradiol* 16: 1885-1888, 1995
- 3) Garner TB, Del Curling O, Kelly DL, Laster DW: The natural history of intracranial venous angiomas. *J Neurosurg* 75: 715-722, 1991
- 4) Hammoud D, Beauchamp N, Wityk R, Yousem D: Ischemic complication of a cerebral developmental venous anomaly: case report and review of the literature. *J Comput Assist Tomogr* 26: 633-636, 2002
- 5) Herbreteau O, Auffray-Calvier E, Desal H, Freund P, De Kersaint-Gilly A: [Symptomatic venous angioma. Report of a case]. *J Neuroradiol* 26: 126-131, 1999 (Fre, with Eng abstract)
- 6) Kim P, Castellani R, Tresser N: Cerebral venous malformation complicated by spontaneous thrombosis. *Childs Nerv Syst* 12: 172-175, 1996
- 7) Konan AV, Raymond J, Bourgouin P, Lesage J, Milot G, Roy D: Cerebellar infarct caused by spontaneous thrombosis of a developmental venous anomaly of the posterior fossa. *AJNR Am J Neuroradiol* 20: 256-258, 1999
- 8) Lai PH, Chen PC, Pan HB, Yang CF: Venous infarction from a venous angioma occurring after thrombosis of a draining vein. *AJR Am J Roentgenol* 172: 1698-1699, 1999
- 9) Lasjaunias P, Burrows P, Planet C: Developmental venous anomalies (DVA): the so-called venous angioma. *Neurosurg Rev* 9: 233-242, 1986
- 10) Masson C, Godefroy O, Leclerc X, Colombani JM, Leys D: Cerebral venous infarction following thrombosis of the draining vein of a venous angioma (developmental abnormality). *Cerebrovasc Dis* 10: 235-238, 2000
- 11) Merten CL, Knitelius HO, Hedde JP, Assheuer J, Bewermeyer H: Intracerebral hemorrhage from a venous angioma following thrombosis of a draining vein. *Neuroradiology* 40: 15-18, 1998
- 12) Peltier J, Toussaint P, Desenclos C, Le Gars D, Deramond H: Cerebral venous angioma of the pons complicated by nonhemorrhagic infarction. Case report. *J Neurosurg* 101: 690-693, 2004
- 13) Thobois S, Nighoghossian N, Mazoyer JF, Honnorat J, Derex L, Froment JC, Trouillas P: [Cortical thrombophlebitis and developmental venous anomalies]. *Rev Neurol (Paris)* 155: 48-50, 1999 (Fre, with Eng ab-

- stract)
- 14) Töpper R, Jürgens E, Reul J, Thron A: Clinical significance of intracranial developmental venous anomalies. *J Neurol Neurosurg Psychiatry* 67: 234-238, 1999
 - 15) Truwit CL: Venous angioma of the brain: history, significance, and imaging findings. *AJR Am J Roentgenol* 159: 1299-1307, 1992
 - 16) Yamamoto M, Inagawa T, Kamiya K, Ogasawara H, Monden S, Yano T: Intracerebral hemorrhage due to venous thrombosis in venous angioma — case report. *Neurol Med Chir (Tokyo)* 29: 1044-1046, 1989
 - 17) Zabramski JM, Henn JS, Coons S: Pathology of cerebral vascular malformations. *Neurosurg Clin N Am* 10: 395-410, 1999
-
- Address reprint requests to: Yukio Seki, M.D., Department of Neurosurgery, Chubu Rosai Hospital, 1-10-6 Komei, Minato-ku, Nagoya 455-8530, Japan.
e-mail: seki.nes@chubuh.rofuku.go.jp