

Frank E. Musiek*
Jane A. Baran†
Jennifer B. Shinn§
Linda Guenette*
Elena Zaidan†
Jeffrey Weihing*

*Department of Communication Disorders, University of Connecticut, Storrs, USA

†Department of Communication Disorders, University of Massachusetts Amherst, USA

§Department of Surgery, Division of Otolaryngology, University of Kentucky Chandler Medical Center, Lexington, USA

Key Words

Central deafness
Word deafness
Auditory evoked potentials
Central auditory processing disorder
Vascular anatomy
Cerebrovascular accident
Auditory cortex

Abbreviations

ABR: Auditory brainstem response
AAC: Augmentative and alternative communication
CANS: Central auditory nervous system
CT: Computer tomography
CVA: Cerebrovascular accident
DPOAEs: Distortion product otoacoustic emissions
HL: Hearing level
LAER: Late auditory evoked response
MCA: Middle cerebral artery
MLR: Middle latency response
MMN: Mismatch negativity
MRI: Magnetic resonance imaging
nHL: Normal hearing level
OAEs: Otoacoustic emissions
PAM: Post auricular muscle artifact
SL: Sensation level
SPL: Sound pressure level

Central deafness: An audiological case study

Sordera Central. Un caso audiológico de estudio

Abstract

Cases of central deafness are rare but they can be most informative about the function and dysfunction of the central auditory nervous system. Previous information on the anatomy, physiology, and terminology related to central deafness is reviewed and a patient with central deafness is profiled. The patient suffered bilateral cerebrovascular accidents (CVAs) compromising Heschl's gyrus and some adjacent neural tissue on both sides of the brain. At 18 months post CVAs, this patient could not understand speech presented solely through the auditory modality. Environmental sounds were perceived, but rarely recognized. Pure-tone testing revealed a severe-to-profound hearing loss bilaterally, but otoacoustic emissions, acoustic reflexes, and the auditory brainstem response were essentially within normal ranges for both ears. Middle late and late auditory potentials were compromised, yielding complex modifications of the waveforms. These findings and the compromised vascular anatomy in this case are detailed in this article.

Sumario

Los casos de sordera central son raros pero pueden ser muy informativos sobre la función y disfunción del sistema nervioso central auditivo. Se hizo una revisión preliminar de información sobre anatomía, fisiología y terminología relacionada con la sordera central y se delineó el perfil de un paciente con sordera central. El paciente sufrió accidentes cerebro- vasculares bilaterales (CVA) comprometiendo el giro de Heschl y algún tejido neural adyacente en ambos lados del cerebro. Después de 18 meses de los CVA, este paciente no entendía el lenguaje que se presentaba únicamente a través de la modalidad auditiva. Los sonidos ambientales eran percibidos pero raramente reconocidos. La prueba con tonos puros reveló una pérdida auditiva bilateral severa a profunda, pero las emisiones otoacústicas, los reflejos acústicos y las respuestas auditivas del tallo cerebral, se encontraron esencialmente dentro de límites normales en ambos oídos. Los potenciales de latencia media y tardía estaban comprometidos llevando a modificaciones complejas de las ondas. Estos hallazgos y la anatomía vascular comprometida de este caso se detallan en este artículo.

Central deafness is a relatively rare and intriguing disorder, which if appropriately studied, can help advance our knowledge and understanding of the anatomy and physiology of the structures within the central auditory nervous system (CANS) that are specifically involved in the processing of acoustic stimuli. Individuals with central deafness typically present with rather dramatic auditory deficits that are not commonly observed in other patients with CANS disorders (Musiek & Lee, 1998). Most patients with central deafness (i.e. 'deafness' of a central origin with preserved peripheral auditory function) demonstrate either inconsistent responses to acoustic signals or the total lack of a response to sounds. Although such severe auditory deficits are often noted in patients with significant involvement of the auditory periphery, they are rare in patients with a compromised CANS (Musiek et al, 1994; Baran et al, 2004).

This intriguing but rare disorder has the potential to afford clinicians and researchers the ability to study the CANS in unique and unprecedented ways. Unfortunately, a number of factors have limited, at least to some extent, the advancement of our knowledge in this area. These factors include: (1) a lack of consensus among researchers as to which anatomical structures should be involved in order to qualify a case for inclusion in the diagnostic category of central deafness, (2) a lack of consistency in the terminology used to describe the disorder (or disorders) represented in the literature, (3) the presence of considerable variability in the nature and/or extent of the auditory deficits experienced by the individuals studied, and (4) a lack of a consistent assessment protocol used across the investigations (Zaidan & Baran, 2003).

Historically, the anatomical basis of central deafness has been attributed to severe damage to the primary auditory cortex of both hemispheres; however, more recent research findings have indicated that other sites of CANS compromise can result in auditory symptoms and behaviors that are consistent with those noted in the earlier studies of central deafness. These additional anatomical sites can include unilateral temporal lobe damage as well as bihemispheric compromise of structures outside of the temporal lobe, including the inferior colliculus, the cerebellum, the internal capsule, the thalamic regions, and the medial geniculate body (Musiek & Lee, 1998; Zaidan & Baran, 2003).

Another factor that has limited one's ability to systematically compare results across the case studies reported in the literature is the lack of consistency in the use of terminology to characterize the central deafness cases being presented (Zaidan & Baran, 2003). Investigators have used a number of different terms to describe the disorders experienced by their patients (e.g. auditory agnosia, midbrain deafness, (pure) word deafness, cortical deafness, and central deafness) and in many of these published reports, these terms have not been fully defined. Moreover, the terminologies employed in the literature do not consistently describe distinct entities even when they are more fully defined; for example, there is considerable overlap observed in the definitions, symptoms, test results, and observed auditory behaviors for many cases that do not share the same diagnostic terminology (Musiek et al, 1994; Zaidan & Baran, 2003). For instance, word deafness (or pure word deafness), which is usually defined as impaired verbal comprehension sparing discrimination and recognition of non-verbal

sounds, rarely exists without some degree of impaired discrimination or recognition of non-verbal stimuli. In many of the case studies reported in the literature, 'word deafness' has been used to label the disorder of the subject or subjects studied; yet, a review of the case history information and/or the test results provided for these cases suggests that other types of non-verbal deficits (e.g. deficits in recognizing environmental sounds, deficits in the processing of music or melodies, no response or inconsistent responses to pure-tone test stimuli) were likely to have co-existed with the verbal processing deficits (e.g. Praamstra et al, 1991; Masuda et al, 2000). Hence, word deafness may well be a misnomer, especially if it is modified by the adjective 'pure', as this would appear to imply that only the perception of speech materials is affected. Thus, the use of a more generic term may be appropriate in many instances (see Musiek et al, 1994; 2004).

Several alternative definitions for auditory agnosia are also found in the literature. This term has been used to define behaviors such as the inability to identify non-verbal sounds and/or noise (Johkura et al, 1998), the inability to recognize all categories of auditory stimuli (Mendez, 2001), and the inability to discriminate or recognize speech even though the spoken words can be heard (Griffiths, 2002). As can readily be seen, there is considerable overlap in several of the deficits reported, not only within this diagnostic category, but across diagnostic categories (e.g. the definition used in the latter group of studies appears to overlap with that for 'word deafness').

Finally, central deafness and cortical deafness have been used somewhat indiscriminately in the literature. Central deafness is often used to refer to the condition experienced by individuals with bihemispheric involvement of the auditory areas of the CANS, whereas cortical deafness is the condition where compromise of the CANS is limited to the primary auditory areas of the cortex. Sometimes central deafness is considered a subtype of cortical deafness, as is auditory agnosia and word deafness, and at other times cortical deafness is considered a subtype of central deafness (Graham et al, 1980; Hood et al, 1994).

Based upon the foregoing discussion, it would appear that use of the term central deafness would be the most appropriate, especially when one is defining cases with lesions of the CANS where the auditory deficits involve the processing of verbal as well as non-verbal test stimuli. Hence, this term will be used in the present investigation. However, it should be stressed that not all patients with 'central deafness' will necessarily show a complete lack of response to sound stimuli—a situation which may be suggested by the use of the word 'deafness' in this particular terminology.

Another factor that has slowed advancements in our understanding of the role of the CANS in this disorder is the existence of considerable variability in the descriptions of the symptoms and auditory behaviors for the various cases reported (Musiek & Lee, 1998; Zaidan & Baran, 2003). In many of these clinical reports, there is a lack of detailed information regarding the full constellation of auditory problems that a given patient experiences—a situation that limits one's ability to associate specific auditory behaviors (or deficits) in these cases with a particular site-of-lesion (or sites-of-lesion). Space limitations preclude a detailed review of this topic, however, it is important to note that a wide array of auditory behaviors have been reported in the literature ranging from a complete lack of response to any

type of sound, to normal or near normal hearing for pure tones and/or environmental sounds with severe speech recognition deficits noted (Ozdamar et al, 1982; Praamstra et al, 1991; Hood et al, 1994; Musiek et al, 1994; Godefroy et al, 1995; Habib et al, 1995; Johkura et al, 1998; Kaga et al, 2000; Pinard et al, 2002; Musiek et al, 2004).

Another limitation that becomes readily apparent when one begins to review the literature in this area is the lack of a consistent 'audiological' approach to assessment across the clinical investigations reported in the literature (Zaidan & Baran, 2003). In many of the case studies reviewed, fairly extensive peripheral testing was completed; however, only a small number (approximately one-third) of the studies reviewed included electrophysiological assessment procedures, such as the auditory brainstem response, the auditory middle late response, and/or the late auditory evoked potentials. Such testing is important in differentiating a 'central' from a 'peripheral' basis for the auditory deficits noted in these cases, as well as in helping to localize the site-of-lesion within the CANS for those patients who experience this rare condition (e.g. Graham et al, 1980; Parving, 1980; Ozdamar et al, 1982; Praamstra et al, 1991; Hood et al, 1994; Musiek et al, 1994; Habib et al, 1995; Johkura et al, 1998; Griffiths, 2002; Musiek et al, 2004).

Case Study

Introduction

The present case study involves a case that presents with bihemispheric involvement of the primary auditory cortex, with only minimal involvement of structures outside of the primary auditory structures within the CANS. In this aspect, it is similar to many of the cases that have been reported in the literature. It is unique, however, in that it relates some novel findings in regard to the nature of the vascular anomalies that have resulted in the bihemispheric cortical damage, and it additionally presents some unique electrophysiological findings for a patient with central deafness. These unique findings add to our knowledge and understanding of the etiological bases and clinical assessment of central deafness.

Case history

This case is of a 46-year-old female who suffered a cerebrovascular accident (CVA) involving the left and right middle cerebral arteries. Prior to the CVA, the patient had reportedly experienced no speech or hearing problems, and she was active in several local societies and volunteer organizations. She is the mother of two children.

The patient reported that she could not hear anything of significance immediately following the CVA. Some improvement in her hearing ability was noted shortly after the CVA, but she remained unable to identify environmental sounds and she could not recognize speech for quite some time. At the time that the present evaluation was conducted (approximately a year and a half after the CVA), the patient could identify some environmental sounds, but she could not comprehend verbal messages when only the auditory modality was available to her. She could, however, identify a few spoken words if she could use some speech reading cues. Her main mode of communication following the CVA was by writing. At 18 months post-CVA she could read reasonably well, she readily used gestures when speaking,

and she spoke with a vocal quality that was similar to that of deaf speech, only high-pitched.

Speech and language evaluation

A review of a speech and language assessment conducted at another facility approximately six months following the patient's CVA indicated that this individual showed no functional response to auditory stimuli of any type. She also experienced a number of language deficits, including a moderate to severe expressive language deficit consistent with fluent aphasia, a mild reading deficit, and a moderate impairment in written expression. In addition, the patient's vocal loudness level and the prosody of her speech were found to be abnormal. These latter two findings were believed to be secondary to an auditory processing deficit. The clinical diagnosis rendered at the completion of testing was a severe impairment in auditory processing, consistent with central auditory dysfunction and a moderate to severe aphasia.

Following this assessment the patient was enrolled in a speech and language management program with therapy goals focusing on the remediation of the language deficits noted during the assessment process and the trial use of a number of augmentative and alternative communication (AAC) devices, including a pocket talker, an FM trainer, and a word prediction program. Some limited gains in language use were noted, but poor results with the AAC and other devices were reported.

A follow-up speech and language re-evaluation was conducted 11 months later at a second facility. At that time, the Communication Activities of Daily Living-2 and a number of subtests from the Western Aphasia Battery were administered. Results revealed an inability to process verbal as well as non-verbal sounds. 'Adequate' but inconsistent speech reading skills were noted during the evaluation. The use of speech reading as a strategy to help fill in what was missed through the auditory channel was most successful when the patient was presented with short, grammatically simple utterances at a slow speaking rate. The patient's oral-verbal expression was characterized by phonemic paraphasic errors and jargon, effortful attempts to retrieve words, and exaggerated prosody and loudness. She relied primarily on written communication for both language comprehension and verbal expression; however, her written expression was described as being characterized by phonemic paraphasic errors and jargon. The findings of this re-evaluation indicated that this patient's communication abilities remained significantly impaired, but that she was most successful communicating when she 'combined use of oral, written and non-verbal communication.' Speech and language intervention at that time was not recommended 'due to the severity of impairment in her auditory system.' However, an audiological re-evaluation, to include consideration of appropriate assistive listening devices was recommended.

Radiology

OVERVIEW

The radiological evaluation included computer tomography (CT) scans, magnetic resonance imaging (MRI) with contrast enhancement, and a cerebral arteriogram. The MRI and arteriogram provided the most definitive information. The MRI showed that much of the right temporal lobe and the posterior insula was

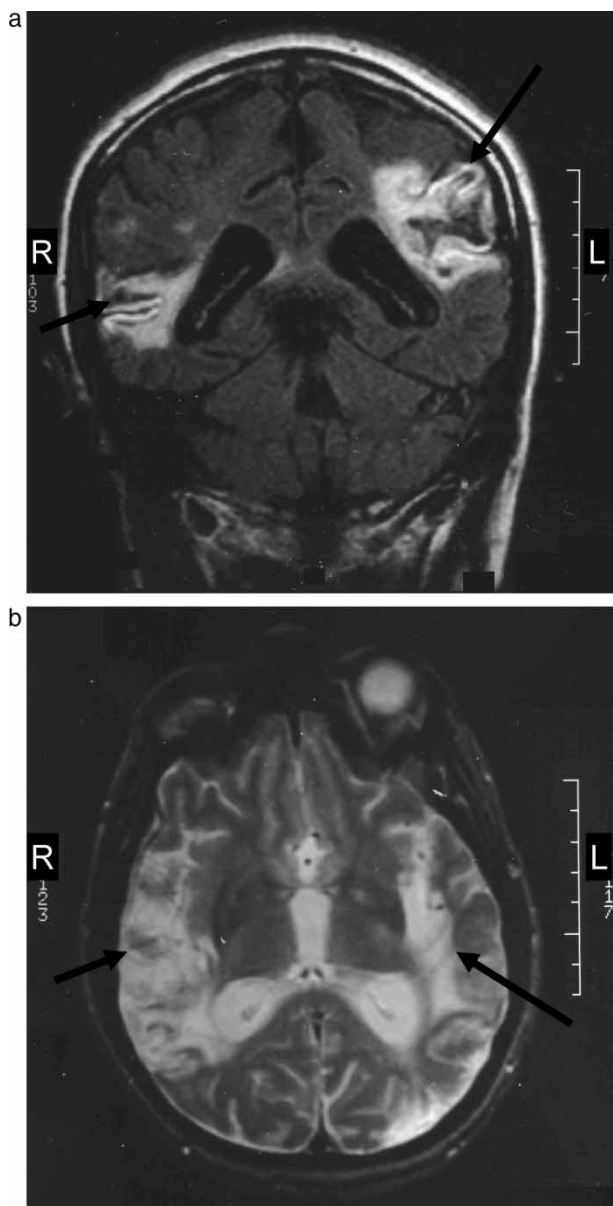


Figure 1. a. T2 magnetic resonance image (MRI) showing a coronal view of the brain for a 46-year-old female with bilateral CVAs affecting the right and left middle cerebral arteries. b. T2 magnetic resonance image (MRI) showing a transverse view of the brain for a 46-year-old female with bilateral CVAs affecting the right and left middle cerebral arteries.

involved (Figure 1, a and b). The maximum dimensions of the lesion on the right side were approximately 7.5 cm anterior to posterior and 3.0 cm inferior to superior. The left temporal lobe was involved primarily in its posterior aspect with the lesion measuring approximately 2.6 cm anterior to posterior and 1.2 cm inferior to superior (Figure 1, a and b). The parietal lobe was also involved on the left side with similar anterior to posterior measurements as the temporal lobe, but the inferior to superior measure appeared to be somewhat larger (i.e. about 3 cm). The cerebral arteriogram revealed some stenosis of the

right carotid artery and an occlusion of the left middle cerebral artery (MCA) at the M2 segment.

ANATOMICAL INTERPRETATION

The coronal view (at the posterior aspect of the temporal lobe) shows involvement of the right superior and middle temporal gyrus (Figure 1, a). It appears that the posterior insula is compromised; although, it is difficult to make a definitive determination based on this view. The left superior temporal gyrus is involved with medial extension to the insula, and the posterior central gyrus of the left inferior parietal lobe is involved along with the adjacent white matter.

The transverse view reveals that most of the mid to posterior region of the superior temporal plane on the right side is compromised (Figure 1, b). This would most likely include Heschl's gyrus, the planum temporale, the supramarginal gyrus, and possibly the angular gyrus. Also, the posterior insula is involved on the right side, as is the occipital area. The left side shows compromise of the mesial temporal lobe and the insula. The posterior temporal plane, including Heschl's area, the planum temporale, and possibly the supramarginal gyrus are involved on this side of the brain.

Audiological procedures

Pure-tone and speech audiometry were conducted using contemporary approaches. Pure-tone thresholds were assessed at the audiometric frequencies from 500 through 4000 Hz. Live voice spondees were used to try to establish spondee thresholds and/or speech detection thresholds. These procedures were modified (allowing extra time and selected spondees) to best allow the patient to respond.

Electroacoustic measures were derived and included both immittance and otoacoustic emissions tests. Tympanograms and acoustic reflexes (226 Hz probe tones) were obtained in a conventional manner using the GSI 1733. Distortion product otoacoustic emissions (DPOAEs) were acquired on a GSI 60. The intensity levels (L1, L2) were 70 dB SPL, and frequencies of 1000 through 4000 Hz were tested.

Electrophysiological testing was conducted using the Nicolet Spirit 2000, and included the auditory brainstem response (ABR), the middle latency response (MLR), and the late auditory evoked response (LAER). Acoustic stimuli for the ABR test were 100 μ sec clicks presented through ER-3A insert earphones at 80 dB nHL. Neuroelectric responses were picked up from cup electrodes attached at the high forehead and referenced to clip electrodes attached to the earlobe of the ear receiving the acoustic stimulus and the contralateral earlobe (ground). The filter band used for the ABR was 100–3000 Hz with 12 dB per octave roll-off. A total of 2000 accepted trials were averaged and the waveform was displayed on a 10 msec time window. The MLR was obtained with the same earphone and stimulus parameters mentioned above. Electrodes were attached at the C3, C4, and Cz electrode sites. The filter band was set at 20–1500 Hz (12 dB per octave roll-off). There were 1000 accepted trials averaged and the waveform was displayed on a 70 msec time window. The LAER potentials acquired included the N1 and P2 evoked potentials. The stimuli and recording sites were the same as for the MLR. The filter band for

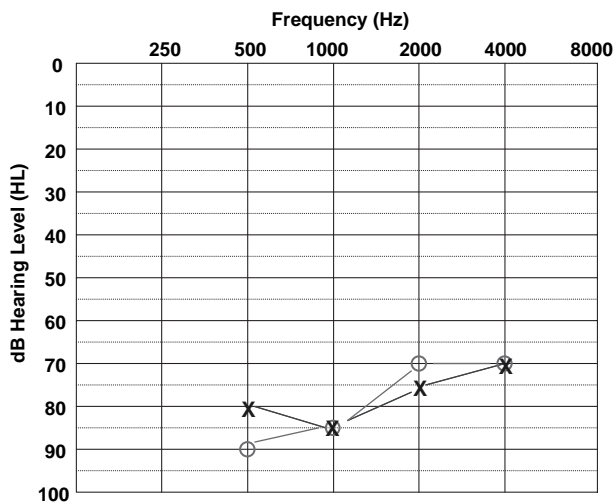


Figure 2. A pure-tone audiogram for the patient described in Figure 1. Thresholds at 250 and 8000 Hz were not recorded on the audiogram due to the high variability of the patient's responses at these two frequencies. Key: X = left ear; O = right ear.

the LAER was 1–30 Hz. There were 360 accepted trials and the waveform was displayed on a 500 msec time window.

Results

Pure-tone thresholds were variable and difficult to obtain, as is characteristic for patients with central deafness. Responses that were obtained fell in the severe hearing loss range for the left ear and the severe to profound hearing loss range for the right ear. Bone conduction responses could not be obtained for either ear at the limits of the audiometer—presumably due to the presence of the severe centrally-based pure-tone hearing deficit (see Figure 2). Spondee thresholds and speech recognition performance could not be measured at the time of testing as the patient could not understand any speech stimuli for either ear. Speech detection thresholds were established at 65 dB HL bilaterally.

Tympanograms revealed normal pressure, compliance, and shape bilaterally. Ipsilateral and contralateral acoustic reflexes were noted at slightly elevated hearing levels (HLs) at 500 Hz bilaterally, and were essentially normal at 1000 and 2000 Hz for both ears. However, given the audiometric data discussed above, these ipsilateral and contralateral reflex thresholds were obtained at markedly reduced sensation levels (SLs) bilaterally (Table 1).

The DPOAEs for the right ear were essentially within the normal range for absolute amplitude levels (in dB SPL) at 1000 through 4000 Hz. In the left ear, the DPOAEs reflected normal absolute amplitude levels for all frequencies except 4000 Hz. The noise floors were high bilaterally, possibly due to some nervousness on the part of the patient. However, even with these elevated noise floors, the DPOAE-to-noise ratios were excellent bilaterally (Musiek & Baran, 1997), with only one recording falling at a ratio of less than 10 dB (the right ear at 1000 Hz) (Figure 3).

Table 1. Ipsilateral and contralateral acoustic reflex thresholds (dB HL) at 500, 1000, and 2000 Hz for the right and left ears of a 46-year-old female with bihemispheric CVAs.

Right Ear			
Test frequency	500 Hz	1000 Hz	2000 Hz
Ipsilateral reflex	105	90	90
Contralateral reflex	105	95	90

Left Ear			
Test frequency	500 Hz	1000 Hz	2000 Hz
Ipsilateral reflex	95	85	75
Contralateral reflex	105	95	90

The ABR absolute and interwave latencies for both ears fell within the normal range bilaterally, as did the interaural latency difference for wave V (Figure 4).

The MLR for the right ear showed similar latencies and amplitudes for the Na and Pa waves across all electrode sites and were within normal limits (see Musiek et al, 1999) (Figure 5). These traces are grand averages, as the individual recordings were noisy and difficult to interpret. The left ear MLR recordings were also difficult to interpret, even when grand averaged. It appears that the response that is seen on these tracings may be a post auricular muscle artifact (PAM), as it occurs too early in time to be an Na or Pa response. In the time interval that a Pa response would normally be expected, there is no readable response (Figure 5).

The LAER response (N1, P2) for the right ear shows unusual morphology—even with grand averages (Figure 6). There are

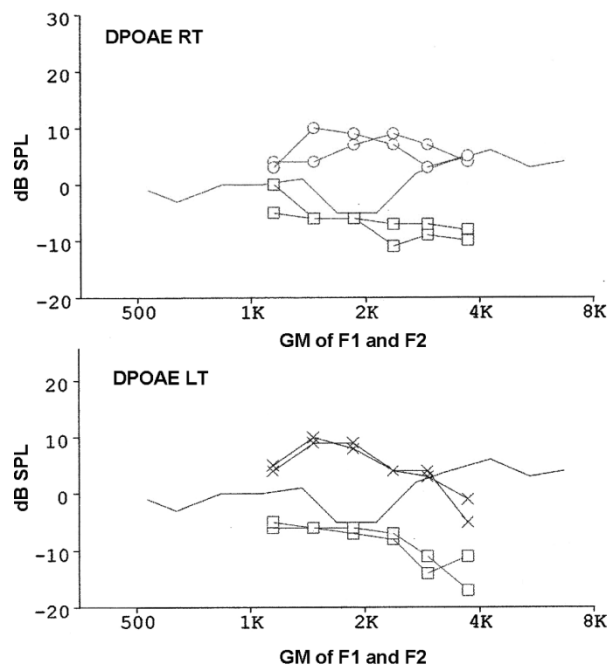


Figure 3. Right ear (upper panel) and left ear (lower panel) DPOAE responses for the patient described in Figure 1. Key: squares = noise floor; solid line coursing from 500 through 8000 Hz = the 90th percentile line.

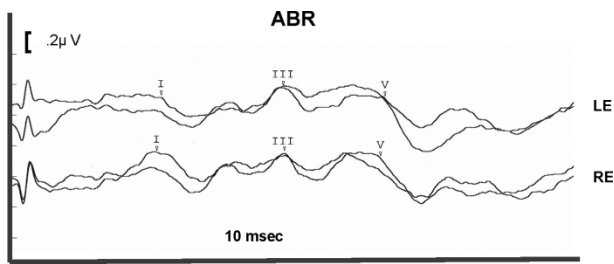


Figure 4. Auditory brainstem responses for the left (LE) and right (RE) ears of the patient described in Figure 1. Measured latencies are as follows: LE (I = 1.74 msec, III = 3.88 msec, V = 5.66 msec); RE (I = 1.66 msec, III = 3.90 msec, V = 5.58 msec).

two positive peaks, one at about 100 msec and the other a rather broad, flattened peak extending from about 150 to 250 msec. The first peak could be P1, and the second, P2, with the slight negative response between the two, possibly N1. This, however, is highly speculative. The grand average for the left ear shows a normal N1, but only a partial P2, at best (there is perhaps a front side of the P2, but much of this is return to baseline, and little else) (Figure 6).

Discussion

Cases of central deafness are rare in occurrence, but of great value to the study of the CANS. The present case study presents considerable audiological and anatomical information, which is significant in terms of the amount and type of information that this case adds to the available literature on this topic.

Neuroanatomy

The anatomical areas involved in this case are essentially relegated to auditory areas of the cerebrum. There is little involvement of non-auditory areas of the brain, other than the possible exception of some limited involvement of the right occipital lobe and the more rostral aspect of the parietal lobe. As such, this case fits into the broad category of central deafness

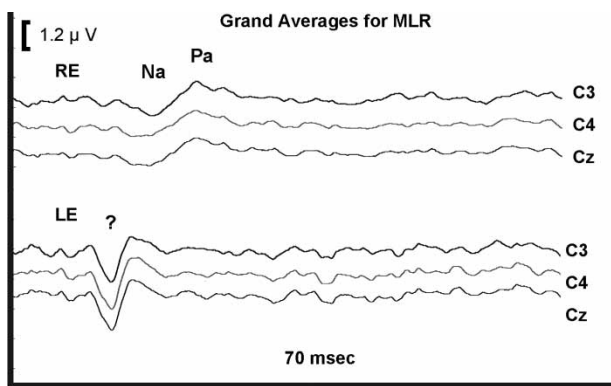


Figure 5. (Auditory) middle latency responses (grand averages) for the right (RE) and left (LE) ears at three electrode locations for the patient described in Figure 1. The Na latencies occurred at 17–18 msec, and the Pa latencies were noted at ~ 23.5 msec for each of the three averaged waveforms derived for the RE. The responses for the LE are difficult to interpret—the positive peaks noted in these waveforms could be post auricular artifact.

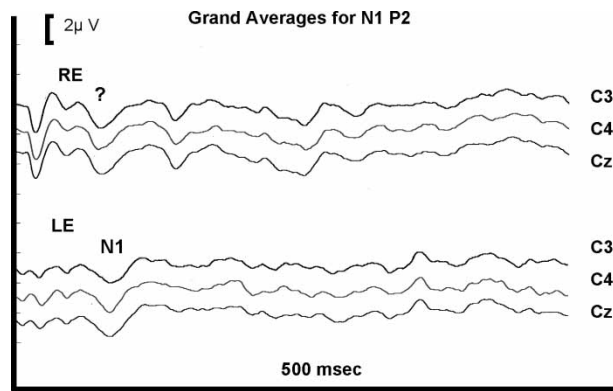


Figure 6. The N1, P2 late potentials (grand averages) derived at three electrode sites for the right (RE) and left (LE) ears of the patient described in Figure 1. The N1 latencies for the LE recordings occur at approximately 90 msec. The RE responses are difficult to interpret.

secondary to bilateral involvement of Heschl's gyrus and the surrounding region of the temporal lobe. Although this is a common site of compromise in cases of central deafness, it has been shown that the disorder can occur with primary lesions that do not involve Heschl's gyrus. In these cases, other auditory regions of the cerebrum are involved and generally, but not always, they are compromised on both sides of the brain (see Nishioka et al, 1993; Musiek & Lee, 1998). In the present case, auditory areas of the cerebrum outside of the temporal lobe were also compromised. These areas included the insula (bilaterally), the inferior post central gyrus (left side), the mid temporal gyrus (left side), the planum temporale (bilaterally), and possibly the supramarginal and angular gyrus (right side). All of these regions have been shown to be responsive to acoustic stimulation (Celesia, 1976; Bamiou et al, 2003; Musiek & Baran, 2007). Therefore, considerable auditory tissue (both primary and secondary) was compromised in this patient, which may have been a factor in the patient's prognosis for recovery and rehabilitative planning.

The vascular anatomy related to this CVA in this case is interesting and somewhat puzzling. The report of the cerebral arteriogram for the right side relates a 'stenosis of the proximal cavernous portion of the internal carotid.' With blood supplies for the frontal, parietal, and temporal lobes all derived from branches of the internal carotid artery, it would appear that if this was the anomalous site within this artery that there would be collateral damage to the parietal and frontal lobes as well as to the temporal lobe. However, this was not the case in this particular patient. Damage was limited to the superior and middle temporal gyri. Based on a review of vascular anatomy presented by Waddington (1974), tissue compromise in this area coincides with a branch of the MCA from which the posterior temporal artery and its branches are derived (Figure 7). There of course may be some variance or anomalous anatomy that could affect our interpretation; for instance there could be collateral circulation that could differentially affect the anatomy of tissue damage in this case. The damage to the left side matches well with the radiological documentation showing an occlusion of the more distal angular artery which supplies the superior posterior temporal gyrus.

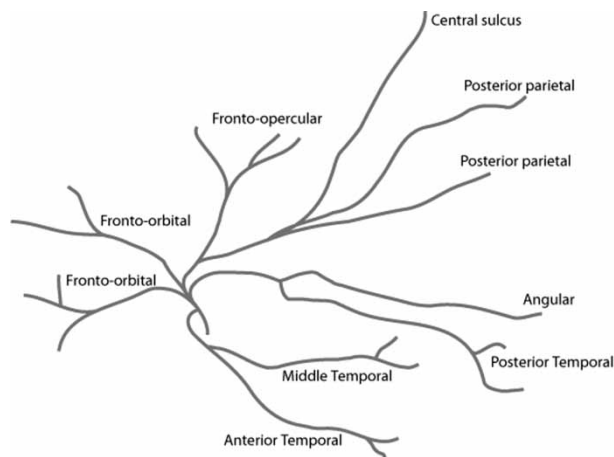


Figure 7. A sketch depicting the branches of the middle cerebral artery (based on Waddington, 1974).

Audiology

The pure-tone test results indicate that this individual could detect sounds at high intensity levels. Therefore, the patient was not totally deaf at the time of the testing. However, her ability to utilize sound in a meaningful way was minimal at best. Given the DPOAE and acoustic reflex test results, it is reasonable to assume that the pure-tone deficits noted for this patient were related to the major compromise of the CANS and not an indication of compromise of peripheral auditory system. It is of interest that Heffner and Heffner (1986) have reported poorer threshold detection of tones in Macaques after bilateral auditory cortex ablations. In extreme cases of CANS involvement, such as this one, pure-tone thresholds can be markedly influenced by central auditory involvement, although in most cases of central auditory dysfunction pure-tone thresholds are minimally affected (see Baran et al, 2004).

Routine speech audiometry could not be conducted with this patient as she could not understand any speech stimuli, including spondees or sentences, on an auditory-only basis. In general, even with visual cues this patient could only occasionally understand and repeat a few words. Although the term ‘word deafness’ is often misunderstood and misused, this case would probably be consistent with this terminology. However, as was discussed above, the use of the term, ‘pure’ word deafness, would not appear to be appropriate in this case as this individual also experienced a number of deficits for non-verbal stimuli.

The acoustic reflexes and the ABR results indicated that the auditory brainstem pathways were intact and functioning normally. The thresholds of the acoustic reflexes were obtained at extremely reduced sensation levels when compared to the pure-tone threshold measures obtained. This observation, when combined with the normal OAE and ABR findings, would indicate that this patient’s peripheral sensitivity was much better than would be predicted by the pure-tone test results.

The MLR at C3, C4, and Cz for the right ear appeared to be within normal limits as both latency and amplitude measures seemed appropriate. The left ear MLR was more difficult to interpret as an early deflection from the baseline was noted. From

our perspective this deflection appeared to be a PAM artifact and not a neural response to the auditory stimuli, as this waveform was too early to be a Na-Pa complex (Goldstein & Aldrich, 1999). Given that the MLR generator sites may be affected, it is possible that the MLR from the left ear is an unusual neural response rather than a PAM—but the authors feel this is unlikely. If the left ear MLR is primarily a PAM response, then the Na-Pa complex is absent or severely attenuated.

In most cases of central deafness for which MLRs were completed, these responses were absent or severely compromised bilaterally (Musiek et al, 1994). Therefore, it is significant that the present patient did have (to our interpretation) a normal MLR for the right ear. This finding is consistent with the concept that a given hemisphere may influence the contralateral ear more than the ipsilateral ear for both behavioral and electrophysiological measures (see Baran & Musiek, 1999; Musiek et al, 1999). In this case, the normal MLR (right ear) was opposite the lesser of the two damaged auditory cortices.

The N1, P2 late potentials also presented a rather complex interpretation. The left ear demonstrated a possible P1 and a definite N1; however, the P2 was compromised. As mentioned earlier, the front side of the P2 was primarily the N1 returning to baseline. There was a slight positive deflection above baseline in this region of the waveform but the remainder of the waveform was essentially flat. The N1, P2 from the right ear shows more activity than the response from the left ear, but unusual waveform morphology is also noted. There is a possible P1 followed by a possible N1 at around 80 msec, and then there is a positive peak at approximately 125 msec, followed by a negative deflection at about 150 msec, which is difficult to interpret, and then a positive peak at a post-stimulus time latency where P2 is typically observed. These unusual waveforms could be reflecting the abnormal synchronicity of damaged neurons in the auditory cortex. It does seem reasonable to state that for these late potentials that while the N1 response may be present and at near normal morphology and latency, that a normal P2 is simply not seen.

In previous cases of central deafness that we have seen in our clinics, the middle and late potentials have been essentially absent for both ears across recording sites (Musiek et al, 1994; 2004). Similar findings have been reported in a number of other investigations (e.g. Graham et al, 1980; Ozdamar et al, 1982). In this case, however, although the MLR and late potentials were not normal, there were some components of the potentials that were present and within the normal range. Several other investigators have reported similar findings; for example the presence of MLR and/or late potentials, but with some abnormal components being evident or with some minor deviations in waveform components being noted (e.g. Parving et al, 1980; Hood et al, 1994). In addition, there have been a few studies that have reported essentially normal MLR findings for patients with extensive compromise of the CANS (e.g. Parving et al, 1980), although in both of these reports the late potentials were absent or showed some minor deviations in waveform morphology. Therefore, as has been suggested earlier, electrophysiological measures can play a critical role in diagnosing central deafness; however, they must be used in combination with a full peripheral audiological work-up and a review of patient history to make this diagnosis. Reliance on only electrophysiological procedures such as the MLR and/or

the late potentials may fail to reveal the presence of CANS involvement in some patients with significant central auditory deficits. In addition, the finding of abnormal or absent MLR and/or late potentials may be secondary to a severe to profound hearing loss and not an indication of CANS involvement. Without the administration of some objective measures of peripheral auditory function, such as acoustic reflexes, OAEs, and/or the ABR test, it will be difficult to attribute the patient's auditory symptoms and deficits (which often include severe to profound hearing loss) to a central as opposed to a peripheral origin.

Concluding Comments

The more cases of central deafness that are reported in the literature, the more clinicians and researchers can understand this unique and rare auditory problem. Cases such as the one reported in this article not only teach us about the value of our clinical test procedures, but they also teach us about the functional anatomy of the CANS. This case was similar to many reported cases of central deafness in a number of ways. The etiology noted in this case (e.g. vascular disease) is common to many, if not most, cases of central deafness, as is the finding of bilateral temporal lobe involvement, specifically at or near Heschl's gyrus. Compromised MLRs and late potentials are also commonly observed in patients with central deafness. Although this case shared many common features, test findings, and observations with previous case studies reported in the literature, it also differed from previous reports in at least two notable ways: (1) the vascular anatomy and areas of damage revealed by the radiological procedures in this case permitted some very detailed and unique observations about the precise location and extent of the damage in this case; and (2) the patient in this study has shown little improvement in auditory function over a period of at least 18 months following her medical condition even though she was relatively young at the time of her bihemispheric CVA. In other studies of young adults with similar types of CANS compromise, significant improvements in auditory function have been noted upon follow-up testing (e.g. Hood et al, 1994). However, the current patient has improved little in a year and a half after her CVA. Unfortunately, at this time there are only a few studies that have followed patients with central deafness over time to document improvement (or lack thereof) in auditory function following the onset of central deafness. A careful analysis of both the initial test findings post onset of the disorder and the early course of auditory improvement following the CANS insult in a larger number of patients with central deafness may provide audiologists and other health care professionals with important information that may lead to more informed decisions regarding the prognosis for improvement in individual patients. This type of analysis may also help inform our decisions regarding intervention strategies for patients with this disorder.

Acknowledgements

Portions of this paper were presented at the annual meetings of the American Speech-Language-Hearing Association in November, 2003 and the American Auditory Society in March, 2005.

The authors would like thank Susan Munroe for her help with this study.

References

- Bamiou, D.E., Musiek, F.E. & Luxon, L.M. 2003. The insula (Island of Reil) and its role in auditory processing. Literature review. *Brain Res Rev*, 42(2), 143–154.
- Baran, J.A. & Musiek, F.E. 1999. Behavioral assessment of the central auditory nervous system. In F.E. Musiek & W.F. Rintelmann (eds.) *Contemporary Perspectives in Hearing Assessment*. Boston, MA: Allyn & Bacon, pp. 375–413.
- Baran, J.A., Bothfeld, R.W. & Musiek, F.E. 2004. Central auditory deficits associated with compromise of the primary auditory cortex. *J Am Acad Audiol*, 15(2), 106–116.
- Celesia, G.G. 1976. Organization of auditory cortical areas in man. *Brain*, 99(Pt. 3), 403–414.
- Godefroy, O., Leys, D., Furby, A., De Reuck, J., Daems, C., et al. 1995. Psychoacoustical deficits related to bilateral subcortical hemorrhages. A case with apperceptive auditory agnosia. *Cortex*, 31(1), 149–159.
- Goldstein, R. & Aldrich, W.M. 1999. *Evoked Potential Audiometry: Fundamentals and Applications*. Boston, MA: Allyn & Bacon.
- Graham, J., Greenwood, R. & Lecky, B. 1980. Cortical deafness: A case report and review of the literature. *J Neurol Sci*, 48(1), 35–49.
- Griffiths, T.D. 2002. Central auditory pathologies. *Br Med Bull*, 63, 107–120.
- Habib, M., Daquin, G., Milandre, L., Royere, M.L., Rey, M., et al. 1995. Mutism and auditory agnosia due to bilateral insular damage: Role of the insula in human communication. *Neuropsychologia*, 33(3), 327–339.
- Heffner, H.E. & Heffner, R.S. 1986. Hearing loss in Japanese Macaques following bilateral auditory cortex lesions. *J Neurophysiol*, 55(2), 256–271.
- Hood, L.J., Berlin, C.I. & Allen, P. 1994. Cortical deafness: A longitudinal study. *J Am Acad Audiol*, 5(5), 330–342.
- Johkura, K., Matsumoto, S., Hasegawa, O. & Kuroiwa, Y. 1998. Defective auditory recognition after small hemorrhage in the inferior colliculi. *J Neurol Sci*, 161(1), 91–96.
- Kaga, K., Shindo, M., Tanaka, Y. & Haebara, H. 2000. Neuropathology of auditory agnosia following bilateral temporal lobe lesions: A case study. *Acta Otolaryngol*, 120(2), 259–262.
- Masuda, S., Takeuchi, K., Tsuruoka, H., Ukai, K. & Sakakura, Y. 2000. Word deafness after resection of a pineal body tumor in the presence of normal wave latencies of the auditory brain stem response. *Ann Otol Rhinol Laryngol*, 109(12, Pt 1), 1107–1112.
- Mendez, M.F. 2001. Generalized auditory agnosia with spared music recognition in a left-hander. Analysis of a case with a right temporal stroke. *Cortex*, 37(1), 139–150.
- Musiek, F.E. & Baran, J.A. 1997. Distortion product otoacoustic emissions: Hit and false-positive rates in normal-hearing and hearing-impaired subjects. *Am J Otol*, 18(4), 454–461.
- Musiek, F.E. & Baran, J.A. 2007. *The Auditory System: Anatomy, Physiology and Clinical Correlates*. Boston, MA: Allyn & Bacon.
- Musiek, F.E., Baran, J.A. & Pinheiro, M.L. 1994. *Neuroaudiology: Case Studies*. San Diego, CA: Singular Publishing Group.
- Musiek, F.E., Charette, L., Morse, D. & Baran, J.A. 2004. Central deafness associated with a midbrain lesion. *J Am Acad Audiol*, 15(2), 133–151.
- Musiek, F., Charette, L., Kelly, T., Lee, W.W. & Musiek, E. 1999. Hit and false-positive rates for the middle latency response in patients with central nervous system involvement. *J Am Acad Audiol*, 10(3), 124–132.
- Musiek, F.E. & Lee, W.W. 1998. Neuroanatomical correlates to central deafness. *Scand Audiol Suppl*, 49, 18–25.
- Nishioka H., Takeda Y., Koba T., Yano J., Ohiwa Y. et al. A case of cortical deafness with bilateral putaminal hemorrhage. *No Shinkei Geka*, 21(3), 269–272.
- Ozdamar, O., Kraus, N. & Curry, F. 1982. Auditory brain stem and middle latency responses in a patient with cortical deafness. *Electroencephalogr Clin Neurophysiol*, 53(2), 224–230.

- Parving, A., Salomon, G., Elberling, C., Larsen, B. & Lassen, N.A. 1980. Middle components of the auditory evoked response in bilateral temporal lesions. *Scand Audiol*, 9(3), 161–167.
- Pinard, M., Chertkow, H., Black, S. & Peretz, I. 2002. A case study of pure word deafness: Modularity in auditory processing? *Neurocase*, 8(1–2), 40–55.
- Praamstra, P., Hagoort, P., Maassen, B. & Crul, T. 1991. Word deafness and auditory cortical function. *Brain*, 114(Pt.3), 1197–1225.
- Waddington, M. 1974. *Atlas of Cerebral Angiography with Anatomic Correlation*. Boston, MA: Little, Brown & Co.
- Zaidan E. & Baran J.A. 2003. Clinical and anatomic findings in central deafness: Meta-analytic approach. Paper presented at the annual meeting of the American Speech-Language-Hearing Association, Chicago, IL.

Copyright of International Journal of Audiology is the property of Taylor & Francis Ltd and its content may not be copied or emailed to multiple sites or posted to a listserv without the copyright holder's express written permission. However, users may print, download, or email articles for individual use.