

SHORT COMMUNICATION

Lacunar stroke attributable to radiation-induced intracranial arteriopathy

I. S. M. Salih^a, N. J. N. Higgins^b, E. A. Warburton^a and J.-C. Baron^a^aDepartment of Clinical Neurosciences and Stroke Unit, University of Cambridge, Cambridge, UK; and ^bUniversity Department of Radiology, Addenbrooke's Hospital, Cambridge, UK**Keywords:**

arteriopathy, lacunar, medulloblastoma, radiotherapy, stroke

We report the rare presentation of lacunar stroke syndrome secondary to single perforator mouth occlusion from radiation-induced middle cerebral artery (MCA) stem arteriopathy. A 30-year-old female had acute-onset right-sided ataxic hemiparesis and dysarthria. As a child, she had a medulloblastoma of the posterior fossa and had surgery followed by cranial radiotherapy. She had no significant vascular risk factors. Acute CT showed extensive bilateral basal ganglia and left thalamic calcification; DWI showed a left internal capsule lacunar infarct; and MRA and CTA showed a 50% stenosis of the proximal left MCA.

Received 10 October 2006

Accepted 24 January 2007

Stroke can occur as a delayed complication of radiotherapy to the head and neck [1]. Delayed radiation-induced narrowing of large extra-cranial arteries is well recognized, but intra-cranial arteries can also be involved, e.g. the carotid siphon after radiotherapy for pituitary or optic pathway tumours [2]. Most cases reported are large artery syndromes. Very few cases of single perforator infarct secondary to radiation have been reported [3].

Case report

A 30 year-old right-handed female presented with sudden onset slurred speech and right-sided weakness involving face, arm and leg, with no history of headache, visual impairment or neck trauma. She is a non-smoker; her father has type-2 diabetes mellitus. There is no family history of neurological disease. She has no history of hypertension, diabetes mellitus, cerebrovascular disease, ischaemic heart disease or atrial fibrillation. At age 7 years she was found to have medulloblastoma of the fourth ventricle and had surgery followed by chemotherapy and radiotherapy. The tumour was successfully removed without major residual neurological deficit. Post-operatively she received 3500 cGy to the cranium over a 3-week period, 2000 to the whole spine, and further 1000 cGy to the posterior fossa. As complications of radiotherapy she had impaired intellectual development and spine osteoporosis with poor spinal growth leading to short stature.

Clinical examination revealed dysarthria and right-sided ataxic hemiparesis with moderate (3/5 MRC) motor weakness affecting face, arm, and leg equally, with no

sensory impairment. There was no dysphasia or visual field abnormality, and no extrapyramidal features. Blood pressure and systemic examination were normal.

CT of the head within 24 h of onset showed extensive calcification of the basal ganglia and posterior thalamus bilaterally, but more marked on the left (Fig. 1a). Diffusion-weighted (DWI) 7 days after onset confirmed a lacunar infarct in the posterior limb of the left internal capsule, extending to the left putamen (Fig. 1b); its size did not exceed 1.5 cm in any direction. FLAIR also demonstrated diffuse white matter changes in the occipital lobe bilaterally, reflecting damage from radiation (Fig. 1c). She had normal carotid ultrasounds, transthoracic echocardiogram, 24-h ECG monitoring, and baseline bloods including fasting glucose, calcium, phosphorus and alkaline phosphatase; total cholesterol (TC) was mildly elevated at 6.3 mmol/l with TC/HDL ratio at 5.3. Auto-immune screen including anti-phospholipid antibodies and thrombophilia screen were negative.

Magnetic resonance angiography (MRA) showed narrowing and irregular calibre of the whole left middle cerebral artery (MCA) stem, suggesting local atheroma (Fig. 1d). These MRA findings were confirmed on CT angiogram (Fig. 1e); the maximal degree of stenosis was measured at 50%.

The patient made a good recovery, and was left with mild right arm weakness and moderate ataxia. She was started on Aspirin and simvastatin. Her blood pressure was consistently below 120/80 over 2 years of follow-up.

Discussion

This patient presented with a typical lacunar stroke syndrome, which is very unusual in young people. Taken together, the extremely unusual calcification of the basal ganglia and thalamus on CT; the occipital lobe white matter changes on FLAIR; the left MCA

Correspondence: Jean-Claude Baron, MD, Department of Clinical Neurosciences, University of Cambridge, Box 83, Addenbrooke's Hospital, Hills Road, Cambridge CB2 2QQ, UK (tel.: +44 (0) 1223-586661; fax: +44 (0) 1223-217909; e-mail: jcb54@cam.ac.uk).

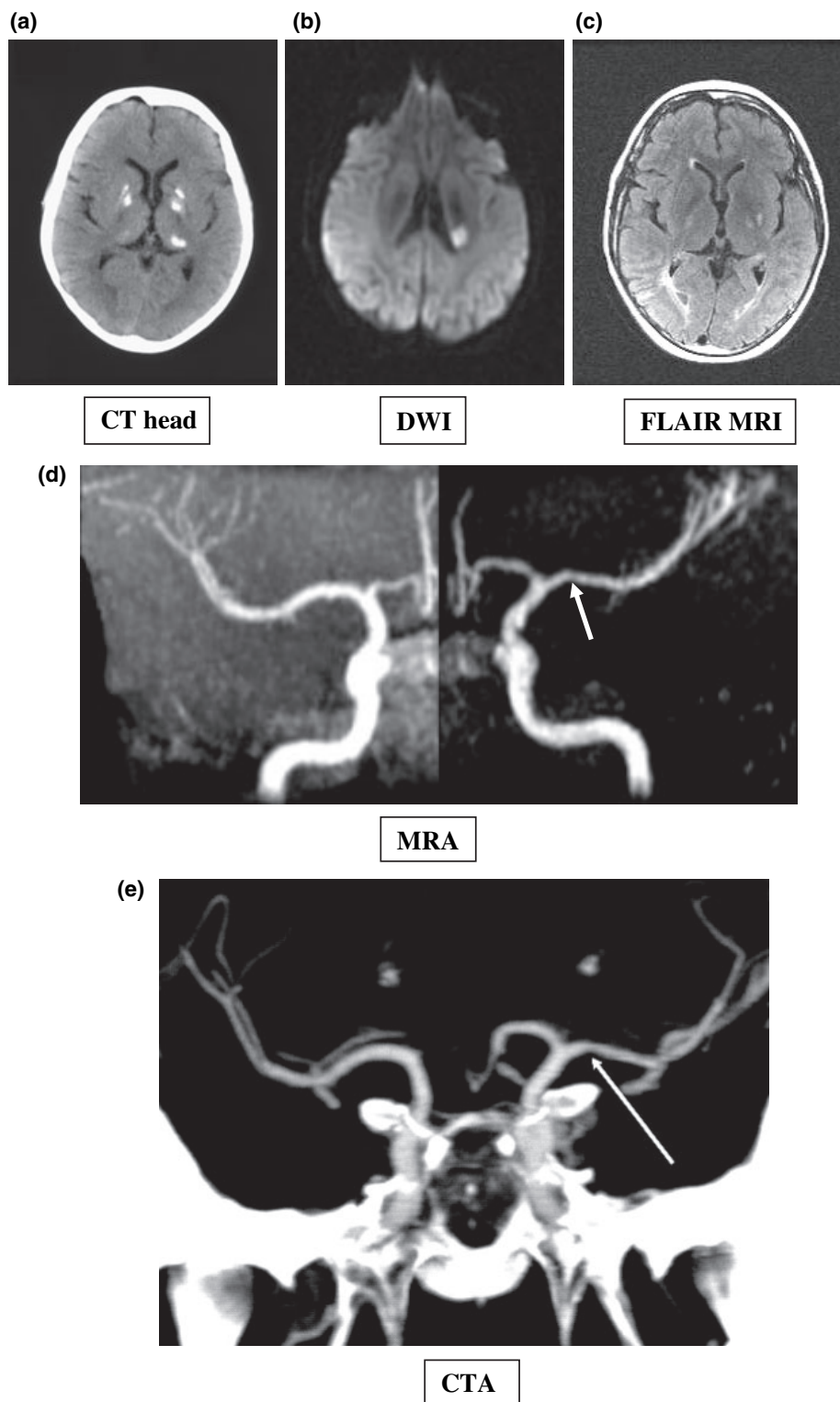


Figure 1 Imaging findings. (a) CT scan of the head showing bilateral calcifications in the basal ganglia and the posterior thalamus bilaterally (more marked on the left). (b) Diffusion weighted imaging (DWI) showing high signal in the left posterior limb of internal capsule and neighbouring lentiform nucleus, consistent with an acute single perforator infarct. (c) FLAIR sequence showing white matter changes in the occipital lobe bilaterally from childhood radiation therapy. (d) Maximum intensity projection (MIP) MRA of the carotid system showing narrowing and irregular calibre of stem of the left MCA (arrow). (e) CT angiography (coronal MIP) showing narrowing and irregular calibre of the stem of the left MCA (arrow).

stem narrowing on MRA and CTA; the young age and negative young stroke work-up; the lack of vascular risk factors other than borderline cholesterol; and finally the history of cranial radiotherapy, strongly suggest radiation-induced accelerated atheroma of the left MCA causing occlusion of the mouth of a perforator leading to a single perforator infarct, or, less likely, of the perforator itself.

The possibility that the basal ganglia calcification was unrelated to the radiation is very unlikely, as involvement of the thalamus is very unusual; there was no known neurological family history; and the patient had no extrapyramidal features and normal blood calcium. That she had sporadic small vessel disease is also very unlikely as it is very rare in the young; she had no vascular risk factor apart from borderline cholesterol; and her blood pressure was always well within normal ranges even 2 years down the line, although formal 24 h monitoring was not performed.

Extracranial disease is well known following radiotherapy to head and neck tumours [1]. However, involvement of the intra-cranial arteries, especially the carotid siphon and middle cerebral artery, is also well documented [3–5]. Huvos *et al.* documented accelerated atheroma as the pathological process induced by radiation therapy in large arteries [6].

A lacunar stroke as a consequence of MCA atheroma causing occlusion of a mouth of a perforator but unrelated to radiation is well described [7,8], especially in East Orientals [9] in whom it is the most frequent presentation of MCA stenosis [10].

Stroke associated with MCA disease caused by radiation therapy has been reported, though rarely. Intracranial vasculopathy following radiotherapy for childhood medulloblastoma has been reported in three cases [4,5], including one case with extensive basal ganglia calcifications [5]. Stenosis affected arteries distal to the Circle of Willis, including one case with > 50% stenosis of the MCA bilaterally [5]. However, neither case had a lacunar stroke. Bowen and Paulsen [3] described two cases, aged 39 and 46 years, of single perforator infarction occurring 13 and 20 years, respectively, after pituitary irradiation. In both patients cerebral angiography revealed stenotic changes in the internal carotid, but also in the middle and anterior cerebral arteries in one case, and possibly of the small perforators in the other case.

Why the radiotherapy given to the posterior fossa resulted in atheroma localized to the anterior circulation, and only to the left MCA, is unclear, but the bulk of the radiotherapy was to the whole cranium, and it is possible that even the beam angulations for the posterior fossa were such that the plane of the circle of Willis was involved. The prominent basal ganglia calcification in this

case (and in a previous similar case [5]) together with the occipital FLAIR changes would support this idea; whilst the clear predominance of the calcification on the left side would fit with the left MCA being mostly affected.

In our case the lacunar syndrome was caused by perforator occlusion likely secondary to radiation-induced MCA local atheroma. Although the stenosis, as measured on CT angiogram, was only moderate at 50%, perforator occlusion has been reported in moderate proximal MCA disease [9], e.g. in 50–69% stenosis [10]. Transcranial Doppler to further document the stenosis was not performed in our case.

This case-report serves to emphasize that lacunar syndromes can be due to post-radiation proximal MCA disease.

Acknowledgements

We thank Dr Justin Cross for his valuable advice on imaging of this case.

References

1. Steele SR, Martin MJ, Mullenix PS, Crawford JV, Cuadrado DS, Andersen CA. Focused high-risk population screening for carotid arterial stenosis after radiation therapy for head and neck cancer. *American Journal of Surgery* 2004; **187**: 594–598.
2. Conomy JP, Kellermeyer RW. Delayed cerebrovascular consequences of therapeutic radiation. A clinicopathologic study of a stroke associated with radiation-related carotid arteriopathy. *Cancer* 1975; **36**: 1702–1708.
3. Bowen J, Paulsen CA. Stroke after pituitary irradiation. *Stroke* 1992; **23**: 908–911.
4. Painter MJ, Chutorian AM, Hilal SK. Cerebrovasculopathy following irradiation in childhood. *Neurology* 1975; **25**: 189–194.
5. Grenier Y, Tomita T, Marymont MH, Byrd S, Burrows DM. Late postirradiation occlusive vasculopathy in childhood medulloblastoma. Report of two cases. *Journal of Neurosurgery* 1998; **89**: 460–464.
6. Huvos AG, Leaming RH, Moore OS. Clinicopathologic study of the resected carotid artery. Analysis of sixty-four cases. *American Journal of Surgery* 1973; **126**: 570–574.
7. Lee DK, Kim JS, Kwon SU, Yoo SH, Kang DW. Lesion patterns and stroke mechanism in atherosclerotic middle cerebral artery disease: early diffusion-weighted imaging study. *Stroke* 2005; **36**: 2583–2588.
8. Lyrer PA, Engelter S, Radu EW, Steck AJ. Cerebral infarcts related to isolated middle cerebral artery stenosis. *Stroke* 1997; **28**: 1022–1027.
9. Bang OY, Heo JH, Kim JY, Park JH, Huh K. Middle cerebral artery stenosis is a major clinical determinant in striatocapsular small, deep infarction. *Archives of Neurology* 2002; **59**: 259–263.
10. Lee PH, Oh SH, Bang OY, Joo SY, Joo IS, Huh K. Infarct patterns in atherosclerotic middle cerebral artery versus internal carotid artery disease. *Neurology* 2004; **62**: 1291–1296.