

A case of acute ischemic stroke: optimizing management with penumbra and vessel imaging

Brian H Buck* and Jeffrey L Saver

SUMMARY

Background An 83-year-old woman with a history of hypertension and dyslipidemia developed acute onset of impaired speech and comprehension, and right-sided weakness. Her previous medical history was notable for hyperthyroidism and a curative remote mastectomy for breast cancer. The patient was on two antihypertensive medications and a statin, and she was not receiving any antiplatelet medication. She was taken by ambulance to a primary stroke center. Initial examination showed global aphasia, right homonymous hemianopia, right hemiplegia, and hemisensory loss.

Investigations Physical examination, laboratory tests, noncontrast head CT scan, multimodal brain MRI scan, catheter cerebral angiogram, echocardiogram, continuous cardiac monitoring.

Diagnosis Acute ischemic stroke caused by distal left internal carotid artery occlusion, with salvageable penumbral tissue and a persistent large-vessel occlusion.

Management Neuroprotective study agent (total dose of 20 g intravenous MgSO_4 or matched placebo), intravenous tissue plasminogen activator, rescue mechanical thrombectomy using the Merci[®] clot retrieval device.

KEYWORDS acute stroke, MRI, neuroprotective agents, prehospital emergency care, thrombolytic therapy

CME

Vanderbilt Continuing Medical Education online

This article offers the opportunity to earn one Category 1 credit toward the AMA Physician's Recognition Award.

THE CASE

An 83-year-old right-handed woman was eating dinner when she suddenly slumped to the right and her speech became slurred and nonfluent. Her vascular risk factors were hypertension and dyslipidemia, and the only other past medical history of interest was long-term hypothyroidism and a curative mastectomy for breast cancer. The patient was on two antihypertensive medications and a statin, and was not receiving any antiplatelet medication. Her husband immediately called the emergency medical services. The paramedics arrived 7 min later and their initial assessment indicated that the patient was experiencing a stroke. The patient met the Los Angeles Prehospital Stroke Screen criteria for stroke,¹ and after a neurologist confirmed the patient's history by phone and obtained consent, the patient was enrolled in the Field Administration of Stroke Therapy–Magnesium (FAST–MAG) phase III neuroprotective trial.² The study infusion (4 g MgSO_4 intravenous over 15 min followed by a maintenance infusion of 16 g MgSO_4 over 24 h, or matched placebo) was started at 33 min after symptom onset, and the patient was transported to a primary stroke center where a noncontrast head CT scan showed a hyperdensity in the M1 segment of the left middle cerebral artery, with no other signs suggestive of an ischemic stroke noted. A provisional diagnosis of acute ischemic stroke secondary to occlusion of the M1 was made and the patient was treated with intravenous tissue plasminogen activator (tPA) at 1 h 54 min after symptom onset.³

Once the intravenous tPA infusion was started, the patient was transferred via air ambulance to a comprehensive stroke center. On arrival (3 h 17 min after symptom onset) the patient remained globally aphasic with dense right

BH Buck is a Fellow of the Division of Neurology in the Department of Medicine, Sunnybrook Health Science Centre, University of Toronto, Toronto, ON, Canada. JL Saver is Director of the UCLA Stroke Centre and Professor of Neurology at University of California Los Angeles, Los Angeles, CA, USA.

Correspondence

*Sunnybrook Health Sciences Centre, Room A408-2075 Bayview Avenue, Toronto, ON M4N 3M5, Canada
brianhbuck@gmail.com

Received 18 December 2006 Accepted 26 March 2007

www.nature.com/clinicalpractice
doi:10.1038/ncpneuro0553

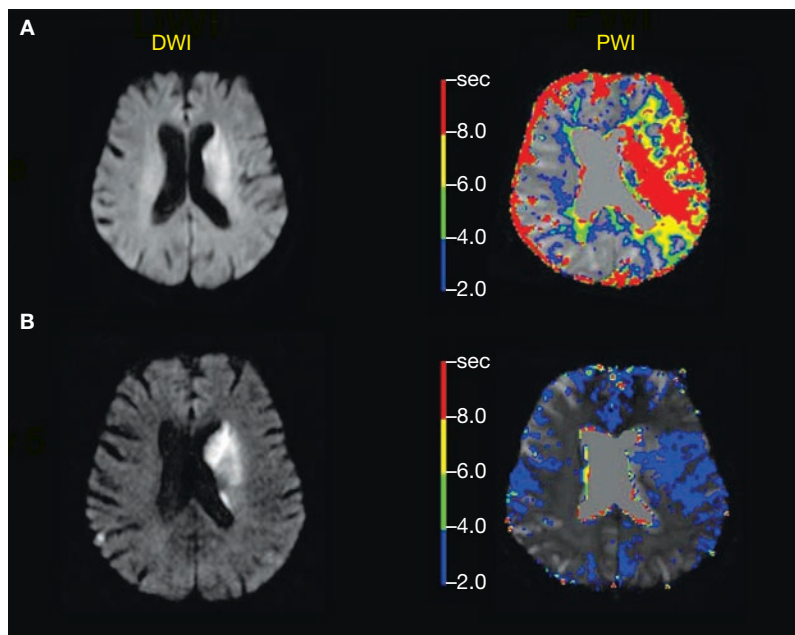


Figure 1 Serial MRI scans of the patient's brain performed before treatment with the Merci® clot retrieval device and 5 days after therapy. **(A)** Pretreatment scan shows a 'mismatch' between the volumes of the PWI abnormality and the DWI lesion. **(B)** Five days after therapy, the DWI lesion is approximately the same size as it was before treatment. The perfusion deficit has now normalized. Abbreviations: DWI, diffusion-weighted imaging; PWI, perfusion-weighted imaging.

hemiparesis and hemisensory loss; her score on the NIH stroke scale was 24, which indicated a severe neurological deficit. A multimodal MRI scan was completed at 3 h 39 min after symptom onset. The apparent diffusion coefficient and diffusion-weighted imaging (DWI) demonstrated ischemic changes confined predominantly to the left basal ganglia and internal capsule (Figure 1). Perfusion-weighted MRI was performed and postprocessed time-to-peak (TTP) images were generated while the patient was still in the MRI scanner. There was a much larger perfusion abnormality relative to the DWI lesion, indicating the presence of a substantial volume of potentially salvageable penumbral tissue. Time-of-flight magnetic resonance angiography showed a loss of signal in the left internal carotid artery and middle cerebral artery.

A cerebral angiogram performed immediately after MRI demonstrated an occlusive thrombus extending from the left internal carotid artery origin through the left middle cerebral artery trunk. Recanalization was attempted by endovascular thrombectomy using the Merci® Retriever device (self-expanding nitinol helix;

Concentric Medical, Mountain View, CA). The first pass of the Merci® Retriever device was performed at 4 h 22 min after symptom onset. After two passes, complete recanalization of the left internal carotid artery was achieved, and partial recanalization of the left M1 segment with good collateral perfusion was noted at 4 h 51 min after stroke onset. Over the next 48 h the patient's language function and right hemiparesis slowly improved. After 24 h she was started on 81 mg of aspirin daily. Cardiac monitoring and transesophageal echocardiogram showed a normal ejection fraction and no valvular or wall motion abnormalities. Moderate aortic arch atherosclerosis was noted. The final etiologic diagnosis of stroke subtype according to TOAST (Trial of Org 10172 in Acute Stroke Treatment) criteria was 'stroke of undetermined etiology';⁴ however, the stroke was possibly caused by an artery-to-artery embolus resulting from aortic arch atherosclerosis. A repeat MRI scan on day 5 showed minimal expansion of the DWI abnormality and normalization of the perfusion deficit (Figure 1). The patient was transferred to an inpatient rehabilitation unit for 10 days, after which she was discharged and sent home. Her residual deficit on discharge consisted of subtle word-finding difficulties and mild distal right arm and leg weakness. Her NIH stroke scale score had decreased from 24 to 4, which indicated a mild residual neurological deficit and represented a dramatic improvement relative to her initial presentation.

DISCUSSION OF DIAGNOSIS

Up to 3 h after symptom onset, almost all stroke patients will have potentially salvageable penumbral tissue; beyond 3 h, the proportion of patients with salvageable penumbra declines steadily with time. Specialized CT or magnetic resonance stroke imaging protocols are an essential first step in evaluating patients' suitability for late reperfusion therapy, which has inherent risks. Multimodal imaging protocols can assess the degree of established tissue injury, the extent of hemodynamic compromise, and the presence of vessel occlusion or stenosis.

The current patient was imaged with a stroke MRI protocol designed to minimize the acquisition time and maximize the amount of imaging data available for therapeutic decision-making. In this protocol, a DWI sequence identifies brain tissue bioenergetically compromised by ischemia, and also helps to identify the stroke

topography, mechanism and vascular localization. A gradient echo sequence is sensitive to the paramagnetic effects of blood degradation products and in acute stroke is used to identify acute and chronic hemorrhage. A fluid-attenuated inversion recovery (FLAIR) sequence reveals early parenchymal changes associated with acute ischemia, and it indexes the burden of vascular disease by identifying previous strokes and leukoaraiosis. Perfusion-weighted imaging employs dynamic contrast enhancement with gadolinium, and is used to identify areas of hemodynamic compromise. Finally, three-dimensional, time-of-flight magnetic resonance angiography of the intracranial circulation provides information about vessel status and can identify large-vessel occlusions or stenoses that can be targeted with endovascular therapy.

A good approximation of the volume of salvageable penumbral tissue harbored by a particular patient is provided by evaluating the mismatch between the volumes of perfusion and diffusion abnormalities on MRI.⁵ Diffusion lesions initially represent the area of bioenergetic compromise, and over time the infarct core, whereas the perfusion abnormality represents the area of hemodynamic compromise. The region in which perfusion abnormality, but no diffusion abnormality, is observed (where there is reduced blood flow but not yet bioenergetic compromise) roughly indexes the penumbral volume. The advantage of using mismatch to define penumbra is that it is simple to apply in a clinical setting; however, clinicians should note that diffusion abnormalities can over-represent the infarct core,⁶ and that the perfusion abnormality will include areas of benign oligemia that are not at substantial risk of infarction.⁷

Perfusion MRI data can be rapidly processed—usually while the patient is still on the scanning table—in order to generate TTP maps. Visual subtraction of DWI lesions from the TTP maps allows clinicians to rapidly evaluate for the presence of mismatch. More-sophisticated, multivariate models that predict tissue fate on a voxel-by-voxel basis are currently being validated, but the mismatch model is still the technique most widely used to select patients for late recanalization therapies.⁸ Once the extent of penumbral tissue has been identified, a range of late reperfusion approaches—mechanical, pharmacologic, or some combination—can be employed.⁹

TREATMENT AND MANAGEMENT

This case highlights an emerging model of stroke care, with treatment coordinated between multiple levels of care providers, and with the goal of early protection of penumbral tissue and rapid delivery of recanalization therapies. The prehospital initiation of the FAST-MAG study infusion demonstrates how paramedics can play an important role in accelerating the delivery of neuroprotective agents. In this patient, the FAST-MAG study infusion was initiated at 33 min after stroke onset. Additionally, coordination of care between the primary and comprehensive stroke centers involved in this case allowed for the delivery of intravenous tPA and endovascular therapy in rapid succession, with recanalization achieved at 4 h 51 min after stroke onset.

The most effective treatment for acute ischemic stroke is early reperfusion of the ischemic brain to salvage ischemic penumbral tissue, reduce final infarct size, and improve functional outcome. The only proven and widely available reperfusion therapy is the administration of intravenous tPA within 3 h of symptom onset, which carries an approximately 6% risk of symptomatic intracranial hemorrhage. On the basis of the results of studies that used ultrasound monitoring after intravenous tPA treatment, the rate of complete early (less than 2 h after administration) recanalization is 34%, and it is even lower for more-proximal vessel occlusions.¹⁰ With terminal internal carotid artery occlusions, as in this case, the early recanalization rate with intravenous tPA alone is approximately 6%.¹⁰ The narrow time window for delivery of intravenous tPA, coupled with a modest rate of early recanalization for proximal large-vessel occlusions, has driven the development of novel treatment approaches for patients who present outside of the 3 h time window or, as in this case, those who are treated with intravenous tPA but fail to achieve recanalization (see Box 1 for proposed algorithm).

Endovascular therapies for reperfusion include both mechanical and pharmacological strategies. There are a number of advantages to using a purely mechanical reperfusion strategy, particularly in a patient who, like the patient in this case, has already received intravenous tPA and still has a proximally located, large-volume occlusive thrombus. Using a mechanical thrombectomy device such as the Merci®

Box 1 Proposed multimodal MRI–CT algorithm for selecting patients for late (>3 h) reperfusion therapies.

Very favorable for i.v. or i.a. therapy

Distal M1 or proximal M2 occlusion (beyond lenticulostriate) + target mismatch (PWI volume $\geq 20\%$ larger than DWI volume and absolute lesion volume ≤ 100 ml)¹⁴

Favorable for i.v. or i.a. therapy

Proximal M1 occlusion + target mismatch
Distal ICA occlusion + target mismatch (i.a. preferred over i.v.)
Distal MCA or ACA branch occlusion + severe deficit + target mismatch (i.v. preferred)
Penetrator occlusion + severe deficit + target mismatch (i.v. preferred)

Avoid fibrinolytic therapy, consider i.a. mechanical therapy

Large infarct core (≥ 100 ml), but substantial visualized penumbra (PWI $\geq 20\%$ larger than DWI volume)

Avoid recanalization therapy, consider decompressive surgery if malignant MCA infarction¹⁵

No substantial visualized penumbra

Abbreviations: ACA, anterior cerebral artery; DWI, diffusion-weighted imaging; ICA, internal carotid artery; i.a., intra-arterial; i.v., intravenous; MCA, middle cerebral artery; PWI, perfusion-weighted imaging. Adapted from Molina and Saver 2005.⁹ Permission obtained from Lippincott Williams & Wilkins © Molina CA and Saver JL (2005) Extending reperfusion therapy for acute ischemic stroke: emerging pharmacological, mechanical, and imaging strategies. *Stroke* **36**: 2311–2320.

Retriever obviates the need for an additional dose of fibrinolytic agent, thereby reducing the risk of hemorrhage. Furthermore, experience at our center has shown that mechanical therapies can achieve recanalization more quickly than can intra-arterial fibrinolytics, and such therapies can deal effectively with large clot burdens that often overwhelm pharmacologic agents (JL Saver, unpublished data). In the present case, the time from first pass of the Merci® device to recanalization was 29 min. The technical efficacy and safety profile of the Merci® Retriever device have been evaluated in prospective trials of patients with large-vessel stroke treated within 8 h.^{11,12} These trials showed recanalization rates that ranged from 46% to 69%, depending on whether adjunctive therapies were used, and also that good neurologic outcomes were more frequent, and mortality was lower, in patients with successful recanalization.¹³ Several ongoing

trials comparing mechanical and medical reperfusion therapies will also evaluate whether multimodal MRI can identify those patients likely to benefit from each treatment, as well as those likely to be harmed.¹⁴

CONCLUSIONS

This case illustrates an emerging model of stroke care that involves the coordination of treatment across multiple levels of care providers. The goal of therapy across all levels of acute care is to protect penumbral tissue and reperfuse ischemic penumbra as early as possible. The patient in this case benefited from early recognition of stroke symptoms by paramedics, which potentially allowed the delivery of a neuroprotective agent, intravenous MgSO₄, before the patient was admitted to hospital. On arrival at a primary stroke center, the patient was rapidly assessed and treated with intravenous tPA. The patient did not improve after tPA therapy and was transferred to a comprehensive stroke center where multimodal stroke imaging sequences established the presence of salvageable penumbral tissue and identified a persistent large-vessel occlusion. This case demonstrates how multimodal MRI coupled with endovascular therapies can safely deliver reperfusion to certain late-presenting or tPA-unresponsive patients, and that such treatment can result in improved clinical and functional outcomes.

References

- Kidwell CS *et al.* (2000) Identifying stroke in the field: prospective validation of the Los Angeles Prehospital Stroke Screen (LAPSS). *Stroke* **31**: 71–76
- Saver JL *et al.* (2004) Prehospital neuroprotective therapy for acute stroke: results of the Field Administration of Stroke Therapy–Magnesium (FAST–MAG) pilot trial. *Stroke* **35**: e106–e108
- The National Institute of Neurological Disorders and Stroke rt-PA Stroke Study Group (1995) Tissue plasminogen activator for acute ischemic stroke. *N Engl J Med* **333**: 1581–1588
- Adams HP Jr *et al.* (1993) Classification of subtype of acute ischemic stroke: definitions for use in a multicenter clinical trial. TOAST: Trial of Org 10172 in Acute Stroke Treatment. *Stroke* **24**: 35–41
- Schlaug G *et al.* (1999) The ischemic penumbra: operationally defined by diffusion and perfusion MRI. *Neurology* **53**: 1528–1537
- Kidwell CS *et al.* (2000) Thrombolytic reversal of acute human cerebral ischemic injury shown by diffusion/perfusion magnetic resonance imaging. *Ann Neurol* **47**: 462–469
- Parsons MW *et al.* (2001) Perfusion magnetic resonance imaging maps in hyperacute stroke: relative cerebral blood flow most accurately identifies tissue destined to infarct. *Stroke* **32**: 1581–1587

- 8 Kidwell CS *et al.* (2003) Beyond mismatch: evolving paradigms in imaging the ischemic penumbra with multimodal magnetic resonance imaging. *Stroke* **34**: 2729–2735
- 9 Molina CA and Saver JL (2005) Extending reperfusion therapy for acute ischemic stroke: emerging pharmacological, mechanical, and imaging strategies. *Stroke* **36**: 2311–2320
- 10 Saqqur M *et al.* (2007) Site of arterial occlusion identified by transcranial Doppler predicts the response to intravenous thrombolysis for stroke. *Stroke* **38**: 948–954
- 11 Smith WS *et al.* (2005) Safety and efficacy of mechanical embolectomy in acute ischemic stroke: results of the MERCI trial. *Stroke* **36**: 1432–1438
- 12 Smith WS (2006) Safety of mechanical thrombectomy and intravenous tissue plasminogen activator in acute ischemic stroke: results of the multi Mechanical Embolus Removal in Cerebral Ischemia (MERCI) trial, part I. *AJNR Am J Neuroradiol* **27**: 1177–1182
- 13 Smith WS (2007) Technology Insight: recanalization with drugs and devices during acute ischemic stroke. *Nat Clin Pract Neurol* **3**: 45–53
- 14 Albers GW *et al.* (2006) Magnetic resonance imaging profiles predict clinical response to early reperfusion: the diffusion and perfusion imaging evaluation for understanding stroke evolution (DEFUSE) study. *Ann Neurol* **60**: 508–517
- 15 Vahedi K *et al.* (2007) Early decompressive surgery in malignant infarction of the middle cerebral artery: a pooled analysis of three randomised controlled trials. *Lancet Neurol* **6**: 215–222

Acknowledgments

BH Buck is supported by a fellowship award from the Heart and Stroke Foundation of Canada.

Competing interests

JL Saver has declared associations with the following companies/organizations: Boehringer Ingelheim, Concentric Medical, the NIH. See the article online for full details of the relationship. BH Buck declared he has no competing interests.