

Bilateral Sudden Profound Hearing Loss and Vertigo as a Unique Manifestation of Bilateral Symmetric Inferior Pontine Infarctions

Roberto Bovo, MD; Rocco Ortore, MD; Andrea Ciorba, MD;
Anna Berto, MD; Alessandro Martini, MD

Objectives: We present a case of sudden bilateral profound deafness and vertigo, without any accompanying neurologic signs, secondary to bilateral infarctions of the cochlear and vestibular nuclei.

Methods: Vertigo, vomiting, tinnitus, and bilateral profound deafness suddenly developed in a 65-year-old woman without any accompanying neurologic signs. In particular, she did not present dysarthria, numbness, cranial nerve palsies, or visual or cerebellar signs.

Results: Magnetic resonance imaging of the brain revealed 2 fresh infarctions of 8 to 10 mm symmetrically localized in the posterolateral bulbopontine junction. Angiography revealed a complete occlusion of the basilar artery, with a well-represented backward flow of its distal portion from the carotid artery via posterior communicating arteries. Excluding a transient ischemic attack that occurred 16 days after the acute episode, the patient had had no other neurologic events at 8 months of follow-up.

Conclusions: Acute vertigo and sudden deafness in a patient with known cerebrovascular occlusive disease may represent the warning signs of an impending brain stem or cerebellar infarction, even when other neurologic signs are absent. These events are fortunately very rare, but should be considered by clinicians who see patients with vertigo.

Key Words: bilateral sudden hearing loss, cochlear nucleus infarction, pontine infarction, sudden hearing loss, vertigo, vestibular nucleus infarction.

INTRODUCTION

Sudden deafness and vertigo in an older patient with known cerebrovascular occlusive disease suggests the likelihood of vertebrobasilar ischemia, because the vertebrobasilar system supplies most of the auditory pathways and the inner ear. Among overall cases of vertebrobasilar ischemia, bilateral and simultaneous deafness are extremely rare, accounting for 0.44% to 3.4% of total cases, and literature reports are few.¹⁻¹¹ These bilateral forms are generally due to occlusion of the basilar or the vertebral arteries and have a severe prognosis. In fact, although hearing and vestibular symptoms sometimes represent the opening clinical feature, the patients soon manifest multiple brain stem or cerebellar signs such as crossed sensory loss, lateral gaze palsy, facial palsy, Horner syndrome, or cerebellar dysmetria.

We report a patient who had vertigo and sudden bilateral profound deafness as the sole manifestation of bilateral symmetric infarctions at the posterolateral bulbopontine junction.

CASE REPORT

In January 2006, a 65-year-old woman suddenly

developed vertigo with nausea, vomiting, and bilateral tinnitus. A few hours later she noticed sudden hearing loss in her left ear, and after 12 more hours, the deafness became bilateral, making her unable to hear at all. Her clinical history revealed long-standing hypertension and a cerebrovascular accident in her childhood that caused a left pyramidal hemiparesis whose actual sequelae were a slight motor deficit in the left arm and leg. A fourth ventricular enlargement, documented on a previous computed tomographic scan, had been stable for many years. For the other aspects there was a negative history, in particular with regard to head trauma, meningitis, autoimmune diseases, ototoxic drugs, and other neurologic events. Objective examinations revealed a horizontal right-beating nystagmus of 2° without any accompanying neurologic signs (excluding the sequelae of the old left hemiparesis). In particular, she did not have dysarthria, numbness, cranial nerve palsies, or visual or cerebellar signs. Pure tone audiometry revealed a bilateral sensorineural deafness that was profound in the right ear (95 dB) and total in the left. This was in contrast with her normal audiogram that was found in our outpatient files for 2003. Otoacoustic emissions were absent, and auditory brain stem responses to clicks at maximum in-

From the Department of Audiology, Ferrara University, Ferrara, Italy.

Correspondence: Roberto Bovo, MD, Dept of Audiology, Arcispedale S Anna, Corso Giovecca 203, IT-44100 Ferrara, Italy.

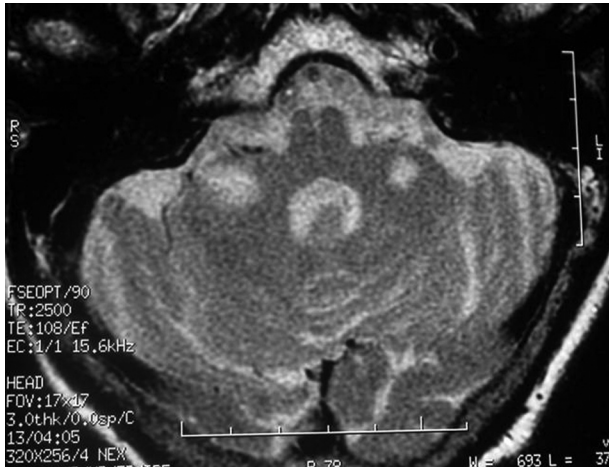

Fig 1. Contrast-enhanced magnetic resonance image of brain shows 2 fresh infarctions symmetrically localized in posterolateral bulbopontine junction.

tensity (125 dB sound pressure level) were absent. An electrocochleogram demonstrated bilateral normal cochlear potentials, and the compound action potential of the nerve was absent.

Contrast-enhanced magnetic resonance imaging of the brain revealed 2 fresh infarctions symmetrically localized in the posterolateral bulbopontine junction (Fig 1). The lesions measured about 10 mm and involved bilaterally the cochlear and inferior vestibular nuclei. Magnetic resonance angiography documented the total absence of blood flow signal in the basilar artery. Brain angiography (Fig 2) confirmed the occlusion of the basilar artery, with a well-represented backward flow of its distal portion and of the superior cerebellar arteries from the carotid artery via posterior communicating arteries. Either these last arteries, or the posteroinferior cerebellar arteries (which originated from the vertebral arteries), had a larger-than-normal diameter. Echo color Doppler scans of the carotid and vertebral arteries, an electrocardiogram, and a transesophageal echocardiogram appeared normal, thus excluding a cardiac source of embolism. Vascular risk factors were an increased plasma level of homocysteine (55.9 mmol/L) and hypercholesterolemia (280 mg/dL); the results of the remaining blood examinations were within normal limits. After a few days, the vertigo and the nystagmus resolved completely, but the patient continued to complain of nonspecific dizziness and bilateral tinnitus. During the entire admission her general condition was stable, and she was treated with antihypertensive and antithrombotic drugs, hypolipemics, and B complex vitamins. Twelve days later, the patient was discharged without any improvement of the auditory threshold or the tinnitus. Vestibular symptoms were absent, excluding a slightly ataxic gait. Unfortunately, the vestibular function

could not be evaluated, because the patient refused a caloric test. We recommended a vibrating cutaneous device for the detection of alarm sounds and training in lipreading given by a speech pathologist. Four days after discharge, the patient had a transient ischemic attack with dysarthria, numbness, and paresis of the upper right arm. She underwent an urgent nonenhanced cerebral computed tomographic scan, which demonstrated no change with respect to the previous one, and she was kept under observation for 24 hours. Aside from this episode, there were no neurologic events after 10 months of follow-up. The most recent audiogram revealed no changes in the auditory thresholds, and no other rehabilitative treatment was deemed useful.

DISCUSSION

Occlusion of the basilar artery is a rare event with a high mortality rate and a poor functional outcome in survivors. The initial symptoms can develop as a disturbance of hearing and/or vestibular functioning, although neurologic signs of brain stem and cerebellar ischemia follow within 24 to 48 hours in most cases. A quick diagnosis and initiation of adequate therapy are thus decisive.

Our case is peculiar because of 1) a bilateral and profound sudden deafness due to a bilateral and symmetric infarction at the posterolateral bulbopontine junction; 2) the absence of neurologic signs other than vertigo (and the stable sequelae of a cerebrovascular accident during childhood), despite the complete occlusion of the basilar artery; 3) the presence of a significant backward flow from the carotid arteries via posterior communicating arteries that probably, over the years, permitted minimal but just sufficient blood flow in the posterior regions; and 4) no other remarkable ischemic attacks during 10 months of follow-up, excluding a transient ischemic attack that occurred 16 days after the first episode. As far as we know, this is the first case of bilateral sudden deafness with such characteristics. In fact, among the patients described in the literature who survived ischemic attacks, not one had bilateral profound deafness due to a well-documented bilateral infarction of the cochlear and vestibular nuclei. In our case, the occlusion of the basilar artery was probably progressive and permitted the development of good collateralization. Welsh et al¹² documented a significant difference in the potential for intracerebral collateralization and regional perfusion due to developmental or structural variability in the posterior communicating arteries, or more generally in the circle of Willis. Most probably, our patient has a favorable configuration of the circle of Willis.

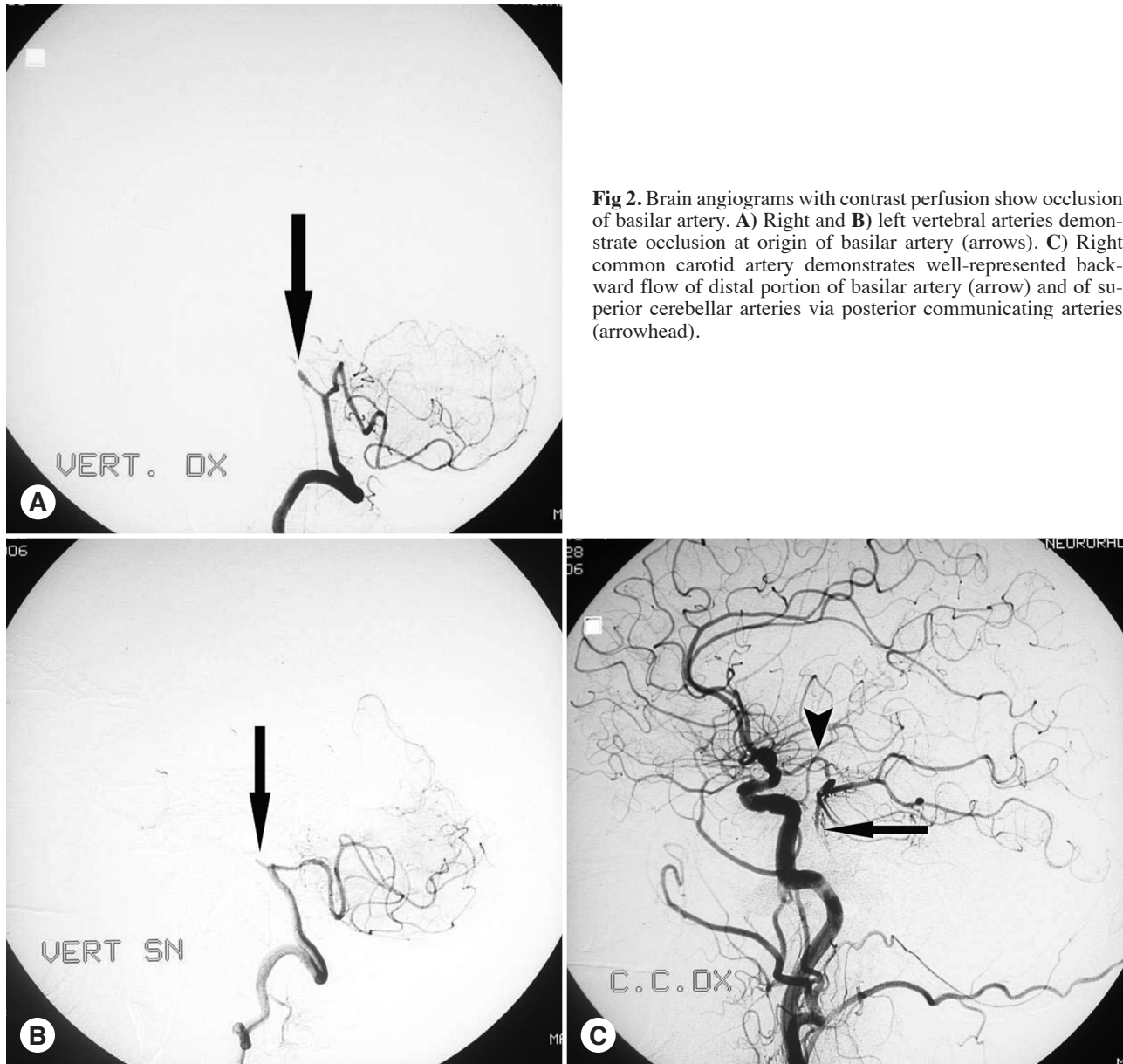


Fig 2. Brain angiograms with contrast perfusion show occlusion of basilar artery. **A)** Right and **B)** left vertebral arteries demonstrate occlusion at origin of basilar artery (arrows). **C)** Right common carotid artery demonstrates well-represented backward flow of distal portion of basilar artery (arrow) and of superior cerebellar arteries via posterior communicating arteries (arrowhead).

Huang et al² observed 7 patients who had sudden bilateral hearing impairment among 503 patients with vertebrobasilar occlusive disease. The main initial neurologic symptoms were sudden bilateral hearing impairment, tinnitus, and vertigo. Acute labyrinthitis or Meniere's disease was the initial diagnosis, but subsequently all of the patients developed brain stem or cerebellar signs, including facial and/or other cranial nerve palsy, diplopia, and bilateral weakness. Ichikawa et al³ reported a similar case with an abrupt onset of bilateral hearing loss but without vertigo. The patient was hospitalized and treated for "idiopathic deafness." Two days later he manifested brain stem and cerebellar symptoms. In these extremely rare cases, bilateral sudden hearing loss may mimic a functional disturbance, that is to say, a

fictitious or a conversion deafness.¹ The hypothesis of a functional deafness was also initially considered in our patient, but an urgent cerebral magnetic resonance imaging scan was requested soon after her admission.

The differential diagnosis of bilateral deafness also includes head trauma, autoimmune inner ear diseases, disseminated encephalitis, human immunodeficiency virus infection, syphilis, drug ototoxicity,¹ and acute drug addiction, whereas in the case of hearing loss due to bacterial meningitis, the clinical history permits an easy diagnosis. Huang and Young¹⁰ encountered a patient with basilar artery occlusion manifesting as vertigo, subsequently followed by bilateral sudden deafness and dysarthria

and terminating in a coma state within 6 hours. A review of the patient's history showed that he had had 2 episodes of transient vertigo 2 weeks before a major stroke. Restated, patients with basilar artery occlusion often have transient vertiginous attacks before a fatal stroke. Embolism of the vertebrobasilar system is probably more common than is generally considered; a potential cardiac source of embolism has been reported in 22% to 70% of patients with infarcts in the vertebrobasilar region.¹³ With our patient, a cardiologic and vascular evaluation seemed to exclude a possible source of embolism, either artery-to-artery or cardiogenic. Moreover, a bilateral and symmetric distribution of embolism, as in this case, would be very atypical.

After 8 months, the deafness of our patient did not ameliorate. This outcome concurs with the observations of Lee and Baloh.¹¹ In their series of vascular sudden deafness, the improvement rate in patients with profound hearing loss was significantly lower than that in patients with less-than-profound hearing loss (40% versus 89%; $p < .01$).

In conclusion, acute vertigo and sudden deafness in a patient with known cerebrovascular occlusive disease may represent the warning signs of an impending brain stem or cerebellar infarction, even when other neurologic signs are absent. These events are fortunately very rare, but should be considered by clinicians who see patients with vertigo.

REFERENCES

1. Lehnhardt E. Acute inner ear deafness [in German]. *HNO* 1991;39:378-85.
2. Huang MH, Huang CC, Ryu SJ, Chu NS. Sudden bilateral hearing impairment in vertebrobasilar occlusive disease. *Stroke* 1993;24:132-7.
3. Ichikawa H, Fukui T, Negishi A, Sugita K, Kanda M. A case of bilateral cerebellar peduncle infarction with bilateral hearing impairment of a sudden onset [in Japanese]. *Rinsho Shinkeigaku* 1994;34:569-76.
4. Fetterman BL, Luxford WM, Saunders JE. Sudden bilateral sensorineural hearing loss. *Laryngoscope* 1996;106:1347-50.
5. Deplanque D, Godefroy D, Guerouaou D, Laureau E, Desauty A. Sudden bilateral deafness: lateral inferior pontine infarction. *J Neurol Neurosurg Psychiatry* 1998;64:817-8.
6. Sunose H, Toshima M, Mitani S, Suzuki M, Yoshida F, Takasaka T. Sudden bilateral hearing loss and dizziness occurred with cerebellar infarction. *Otolaryngol Head Neck Surg* 2000;122:146-7.
7. Schmiz A, Haibt-Luttke G, Albrecht G, Hagen R, Gustorf-Aeckerle R. Thrombosis of the basilar artery — a rare differential sudden deafness diagnosis and vestibular failure [in German]. *Laryngorhinootologie* 2000;79:253-9.
8. Toyoda K, Hirano T, Kumai Y, Fujii K, Kiritoshi S, Ibayashi S. Bilateral deafness as a prodromal syndrome of basilar artery occlusion. *J Neurol Sci* 2002;193:147-50.
9. Lee H, Yi HA, Baloh RW. Sudden bilateral simultaneous deafness with vertigo as a sole manifestation of vertebrobasilar insufficiency. *J Neurol Neurosurg Psychiatry* 2003;74:539-41.
10. Huang CC, Young YH. Vertigo with rebound nystagmus as an initial manifestation in a patient with basilar artery occlusion. *Eur Arch Otorhinolaryngol* 2005;262:576-9.
11. Lee H, Baloh RW. Sudden deafness in vertebrobasilar ischemia: clinical features, vascular topographical patterns and long-term outcome. *J Neurol Sci* 2005;228:99-104.
12. Welsh LW, Welsh JJ, Lewin B, Dragonette JE. Incompetent circle of Willis and vertebrobasilar insufficiency. *Ann Otol Rhinol Laryngol* 2003;112:657-64.
13. Bogousslavsky J, Cachin C, Regli F, Despland PA, Van Melle G, Kappenberger L. Cardiac sources of embolism and cerebral infarction — clinical consequences and vascular concomitants: the Lausanne Stroke Registry. *Neurology* 1991;41:855-9.