

Short Illustrated Review

Haemorrhagic presentation of low-grade glioma in adults

A. Della Puppa¹, F. Zustovich², M. Gardiman³, R. Manara⁴, D. Cecchin⁵, R. Scienza¹

¹ Department of Neurosurgery, Padua Hospital, Padua, Italy

² Department of Oncology, I.O.V.-I.R.C.C.S, Padua, Italy

³ Department of Pathology, Padua Hospital, Padua, Italy

⁴ Department of Neuroradiology, Padua Hospital, Padua, Italy

⁵ Department of Diagnostic Medical Sciences, Nuclear Medicine Service, University Hospital, Padua, Italy

Received 13 February 2007; Accepted 10 July 2007; Published online 6 August 2007

© Springer-Verlag 2007

Summary

Intracranial bleeding is rare in patients with low-grade gliomas, above all in adult population. We reviewed the literature of such cases and reported another case of a haemorrhagic low-grade glioma in a 54-year-old woman presenting with a left hemiparesis. Computer tomography (CT) images showed a right basal ganglia haemorrhage with no mass effect. Vascular malformations were ruled out by angiography. Eighteen fluoro–fluoro deossiglucosio (18F-FDG) positron emission tomography (PET/CT) showed a large hypometabolic area corresponding to the lesion. We waited for patient's improvement. Late magnetic resonance images revealed a low-grade glioma at the bleeding site. Tumour was removed and histopathologic examination revealed a WHO grade II mixed glioma.

The authors emphasise that this evidence has to be kept in mind since it has important therapeutic implications.

Keywords: Low-grade gliomas; mixed gliomas; intra-tumoural bleeding.

Introduction

Any brain tumour can bleed. However, an intracerebral haemorrhage is usually associated with malignant tumours, primary or mets.

The incidence of bleeding in gliomas of all grades is between 3.7 and 7.2% [9] and low-grade gliomas account for less than 1% of tumours presenting haemorrhage [14]. Haemorrhage in gliomas is usually more frequent in pediatric than in adult population (5.3 and 2.3%, respectively, of cerebral tumours) [8]. We reviewed the literature of published cases of bleeding low-grade gliomas and report an illustrative case.

Literature review

The literature used for this review was identified using the Medline database (PubMed, <http://www.ncbi.nlm.nih.gov/PubMed/>). The search strategy of the electronic databases was performed combining the following terms: “low-grade gliomas” AND (“cerebral hemorrhage” OR “haemorrhage” OR “bleeding” OR “haemorrhagic” OR “hemorrhagic onset”).

Analysis

The search strategy produced a total of 47 references. Among them, it was possible to identify 15 cases of haemorrhagic cerebral low-grade gliomas [1, 3,

Correspondence: Alessandro Della Puppa, M.D., Via Giustiniani 2, Azienda Ospedaliera di Padova, 35100 Padova, Italy. e-mail: alessandro.dellapuppa@sanita.padova.it

Table 1. Cases collected from the literature review

Patient (sex, age)	Histology	Haemorrhage type	Author
M, 15 years old	astrocytoma	subarachnoid	Memon <i>et al.</i> [18]
Not specified	astrocytoma	intracerebral	Bitoh <i>et al.</i> [3]
M, 15 years old	astrocytoma	cerebellar	Harada <i>et al.</i> [12]
F, 2 years old	astrocytoma	hypothalamic	Tashiro <i>et al.</i> [19]
M, 12 days old	ganglioglioma	intracerebral	Tekkok and Ventureyra [20]
F, 13 years old	pilocytic	intracerebral	Golash <i>et al.</i> [9]
M, 4 years old	pilocytic	intraventricular	Devi <i>et al.</i> [7]
Not specified	astrocytoma	not specified	Abrahams and Prayson [1]
Not specified	astrocytoma	not specified	Licata and Turazzi [16]
Not specified	astrocytoma	not specified	
Not specified	oligodendroglioma	not specified	
Not specified	oligodendroglioma	not specified	
Not specified	oligodendroglioma	not specified	
Not specified	oligodendroglioma	not specified	
F, 15 years old	glioneuronal	intracerebral	Buccoliero <i>et al.</i> [4]

4, 7, 9, 12, 16, 18–20] (Table 1). Only two references were about the hemorrhagic onset of low-grade gliomas (key words: “low-grade gliomas” AND “hemorrhagic onset”). The first was about a glioneur-

onal tumour in a young patient, the second one was about a large single centre experience but unfortunately patients’ age and haemorrhage type were not described.

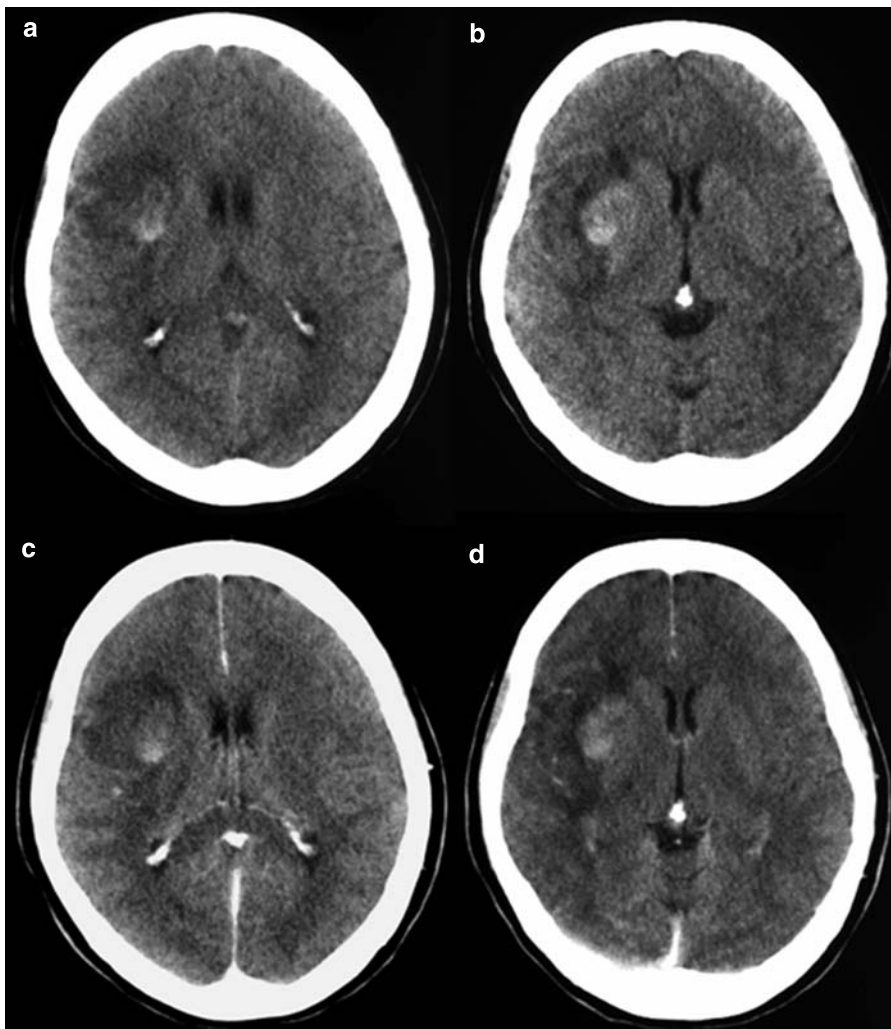


Fig. 1. Axial CT before (a and b) and after (c and d) administration of contrast medium: the images show a hyperdense lesion lateral to the right putamen consistent with an intraparenchymal haematoma; there is moderate perilesional edema without contrast enhancement and without significant mass effect

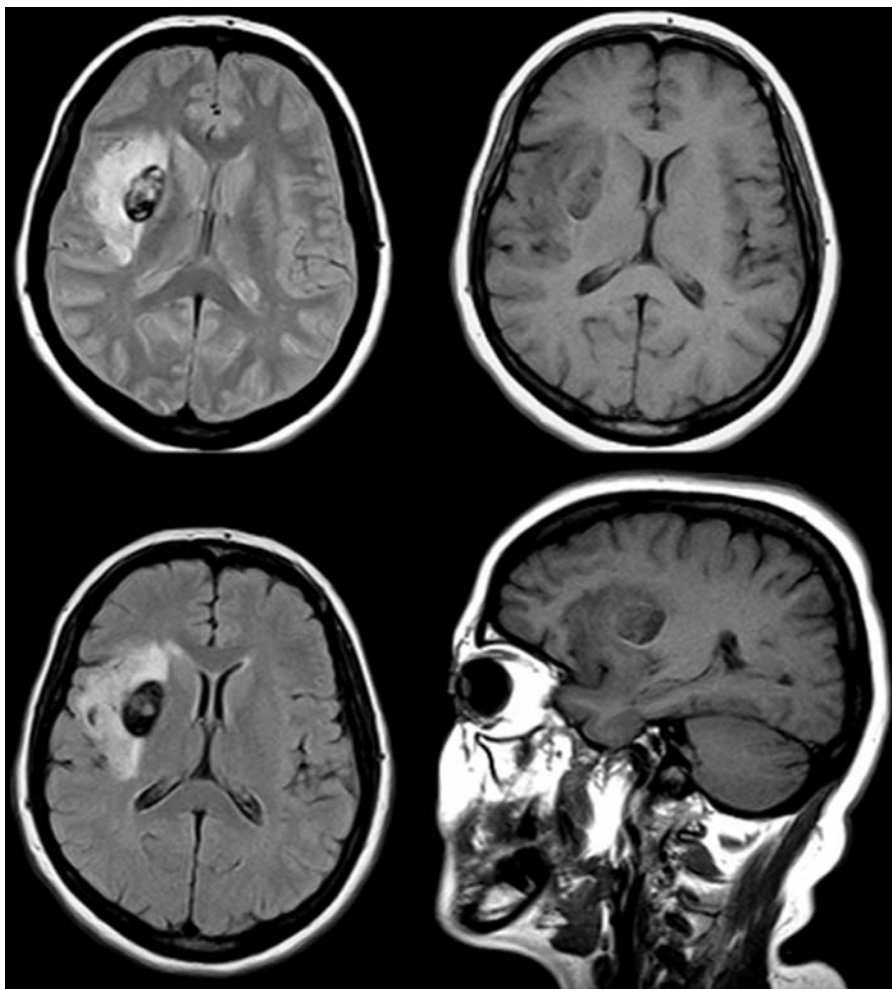


Fig. 2. DP, T1 and FLAIR axial images at the same level, showing a dishomogeneous ovoid hypointense lesion (due to the presence of blood degradation products), characterized by marked lateral edema

Case report

A 54-year-old woman presented with acute onset of headache, vomiting, left hemiparesis. Cerebral CT (Fig. 1) showed a right putaminal-external capsule haemorrhage, with little mass effect. She was referred to our institution for further treatment. We learned that the patient had a 6-month history of episodic headaches. On examination she was alert and presented left hemiparesis.

Angiography was performed and vascular malformations were ruled out. Cerebral magnetic resonance imaging (MRI) showed a mixed signal lesion in the haemorrhagic site surrounded by a no-contrast enhancing area.

After i.v. injection of 18F-FDG, early (after 1 h) and delayed (after 4 h) PET/CT images were acquired. A large area of hypometabolism was detected by PET/CT, CT, corresponding to the lesion described by MRI, so we waited for complete patient recovery and for the haemorrhage to clear up.

Clinical and radiological monitoring was carried out. No neurological signs were further present but some complex partial seizures. Subsequent MRI showed

(Fig. 2) a mixed signal core in the putaminal-external capsule, no-contrast enhancing, surrounded by a diffuse area of low intensity on the T1-weighted images with an

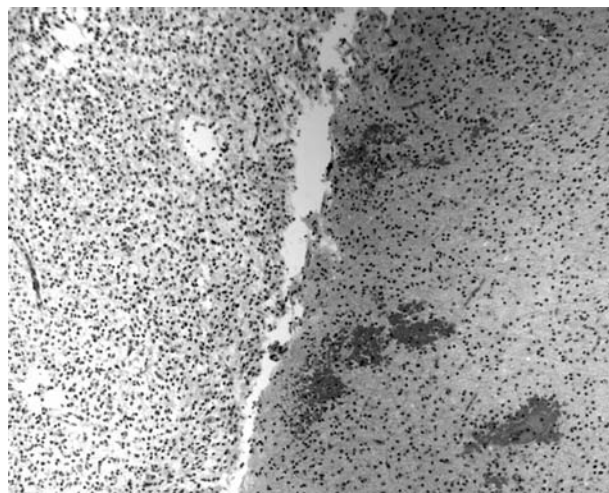


Fig. 3. Histopathological findings of the removed low-grade oligo-astrocytoma showing both astrocytoma (on the right side) and oligodendroglioma (on the left side) characteristics

increase in signal intensity in the T2-weighted images. This data was interpreted as a haemorrhagic cavernoma with surrounding oedema. Then, a right fronto-temporal craniotomy was performed and the bleeding core, mimicking cavernoma, was removed using a neuronavigation system. Seizures disappeared. Histopathologic examination revealed that the lesion was a WHO grade II mixed oligo-astrocytoma (Fig. 3). Owing to residual disease after surgery and to age and good performance status, the patient has been undergone complementary chemotherapy treatment with Temozolomide (200 mg/m² a day for 5 days every 28 days cycles). Currently, to date 2 cycles have been administered without significant toxicity.

Discussion

In the literature, cases of bleeding tumours of different histology were reported. Metastases, particularly from melanoma, and malignant gliomas are considered the most frequent bleeding tumours. Glioblastoma presents the highest overall incidence of bleeding tumours but primary melanoma and neuroblastoma which are proportionally rarer do, however, have a much higher ratio of bleeding [16]. The incidence of bleeding in gliomas of all grades is between 3.7 and 7.2% [9]. Frequency of bleeding increases with the degree of tumour malignancy [16]. Some authors [14] underline considerable bleeding rates in anaplastic astrocytomas, oligodendrogliomas, oligoastrocytomas when reporting about intratumoural microhaemorrhages, that have the same incidence in WHO grade IV astrocytomas (56%) and WHO grade III oligodendrogliomas (53%).

Low-grade gliomas make up approximately 15% of brain tumours in adults [22]. Despite facing a better prognosis when compared with patients with higher grade glial tumours, between 50 and 75 % of patients harbouring low-grade gliomas eventually die of their disease [11].

There are only a few reports discussing haemorrhages associated with low-grade gliomas [2, 5, 10, 14, 17]. Low-grade gliomas account for less than 1% of tumours presenting with haemorrhage. Some cases have been described but they were mostly reported in pediatric patients [8] contrary to our patient who was 54 years old. In the literature we collected, no adult patient was reported. Three types of bleeding are described: intracerebral, intraventricular and subarachnoid (Table 1). Our patient presented an intracerebral haemorrhage similar to 4 patients reported in the literature. Bleeding is rarely the onset of symptoms [4, 16] but this was the case in our patient.

Metabolic studies were not helpful in gaining more details about the nature of the described lesion. How-

ever, hypometabolic PET images allowed us to wait for improvements in the patient's neurological conditions. Late MRI findings were suggestive of an acute haemorrhagic event within the tumour but the rarity of this finding induced us to believe, erroneously as it happens, it was a haemorrhagic cavernoma. This misdiagnosis is what led us to only partially removing the tumour.

Reasons for bleeding in low-grade gliomas are not understood, since neither tumour necrosis nor abnormal vessels are present in these tumours. Some authors [6, 21] suggest that abnormal vessels or endothelial proliferation could be the cause of haemorrhage in oligodendrogliomas.

In the literature (Table 1), low-grade astrocytic and oligodendroglial bleeding tumours were both described, even if glioneuronal and pylocytic tumours were also reported.

In our case, histopathologic examination showed a low-grade glioma where it was possible to recognize a diffuse admixture of oligodendrocytes and astrocytes, both of them were unequivocally neoplastic, with a prevalence of astrocytes. In this tumour, a fibrillary classic astroglial component was evident intermingled with oligodendroglial cells with clear cytoplasm and round, regular nuclei. In the literature the fibrillary component was described in two out of six (Table 1) bleeding astrocytomas [12, 16]. Although low grade astrocytoma is not commonly known as a tumour producing intracerebral haemorrhage, the information on the possible haemorrhagic presentation of this tumour is important for correct diagnosis and thus for proper management of this tumour such as surgical timing and approach.

Conclusions

Low-grade gliomas are nowadays a challenging pathology for neurosurgeons concerning diagnosis, best treatment and follow-up. Hemorrhage is an unusual clinical presentation, particularly in the intraparenchymal form, which we have bare in mind in differential diagnosis with other bleeding cerebral pathologies. Clinical preoperative suspicion permits clinicians to choose the best diagnostic and therapeutic approach.

References

1. Abrahams NA, Prayson RA (2000) The role of histopathologic examination of intracranial blood clots removed for hemorrhage of unknown etiology: a clinical pathologic analysis of 31 cases. *Ann Diagn pathol* 4(6): 361–366
2. Aichholzer M, Gruber A, Haberler C (2001) Intracranial hemorrhage from an aneurysm encased in a pilocytic astrocytoma.

- Case report and review of the literature. *Child Nerv Syst* 17: 173–178
3. Bitoh S, Hasegawa H, Ohtsuki H, Obashi J, Fujiwara M, Sakurai M (1984) Cerebral neoplasm initially presenting with massive intracerebral hemorrhage. *Surg Neurol* 22(1): 57–62
 4. Buccoliero AM, Giordano F, Mussa F, Taddei A, Genitori L, Taddei GL (2006) Papillary glioneuronal tumor radiologically mimicking a cavernous hemangioma with hemorrhagic onset. *Neuropathology* 26(3): 206–211
 5. Byard RW, Bourne AJ, Hanieh A (1991) Sudden and unexpected death due to hemorrhage from occult central nervous system lesions. A pediatric autopsy study. *Pediatr Neurol* 17: 88–94
 6. Charles NC, Nelson L, Brookner AR (1981) Pilocytic astrocytoma of the optic nerve with hemorrhage and extreme cystic degeneration. *Am J Ophthalmol* 92: 691–695
 7. Devi BI, Shukla D, Bhat D, Santosh V (2001) Hypothalamic tumour with haemorrhage. *Childs Nerv Syst* 17(9): 567–569
 8. Garg A, Chugh M, Gaikwad SB, Chandra SP, Gupta V, Mishra NK, Sharma MC (2004) Juvenile pilocytic astrocytoma presenting with subarachnoid hemorrhage. Case report and review of the literature. *J Neurosurg (Suppl)* 5: 525–529
 9. Golash A, Thorne J, West CG (1998) Low-grade pilocytic astrocytoma presenting as a spontaneous intracerebral haemorrhage in a child. *Br J Neurosurg* 12(1): 59–62
 10. Gottfried ON, Fufts DW, Townsend JJ, Couldwell WT (2003) Spontaneous hemorrhage associated with a pilomyxoid astrocytoma: case report. *J Neurosurg* 99(2): 416–420
 11. Guidelines and Outcomes Committee of the AANS (1998) Practice parameters in adults with suspected or known supratentorial non-optic pathway low-grade glioma. *Neurosurg Focus* 4(6): Article 10
 12. Harada K, Hayashi T, Okamoto Y, Shojima K, Utsunomiya H, Maehara F, Sato Y (1986) Cerebellar astrocytoma presenting with cerebellar hemorrhage: a case report. *No Shinkei Geka* 14 (Suppl 3): 411–416
 13. Hwang SL, Huang TY, Chai CY, Howng SL (1998) Hypothalamic juvenile pilocytic astrocytoma presenting with intracerebral hemorrhage. *J Formos Med Assoc* 97(11): 784–787
 14. Kondziolka D, Bernstein M, Resch L (1987) Significance of hemorrhage into brain tumor: clinicopathological study. *J Neurosurg* 67: 852–857
 15. Laurent JP, Bruce DA, Schut L (1981) Haemorrhagic brain tumors in pediatric patient. *Child Brain* 8: 263–270
 16. Licata B, Turazzi S (2003) Bleeding cerebral neoplasms with symptomatic hematoma. *J Neurosurg Sci* 47(4): 201–210; discussion 210
 17. Lones MA, Verity MA (1991) Fatal hemorrhage in a cerebral pilocytic astrocytoma-adult type. *Acta Neuropathol (Berl)* 81(6): 688–690
 18. Memon MY, Neal A, Imami R, Villareal N (1984) Low-grade glioma presenting as subarachnoid hemorrhage. *Neurosurgery* 14(5): 574–577
 19. Tashiro T, Aida T, Sugimoto S, Abe H, Nagashima K (1992) A case of hypothalamic astrocytoma with precocious puberty. *No Shinkei Geka* 20(1): 61–65
 20. Tekkok IH, Ventureyra EC (1997) Spontaneous intracranial hemorrhage of structural origin during the first year of life. *Childs Nerv Syst* 13(3): 154–165
 21. Van Ouwkerk WJ, Dirven CM (1998) Hematoma in a low-grade medullary astrocytoma: report of unusual case and literature review. *Childs Nerv Syst* 14: 742–746
 22. Yoshida D, Kogiku M, Noha M, Takahashi H, Teramoto A (2005) A case of pleomorphic xanthoastrocytoma presenting with massive tumoral hemorrhage. *J Neurooncol* 71(2): 169–171

Comment

The authors nicely document the hemorrhagic presentation of a low grade (grade II) mixed glioma in a 54-year old female. The clinical presentation, radiographic images and review of the literature of other similar cases are presented.

The case is rare, as noted by the authors. It is surprising that this presentation occurs given the lack of angiogenesis and fragile neovascularity in low grade tumors, which is likely the source of haemorrhage in higher grade lesions. One might be suspicious that this could be the forme fruste of a transformation of this tumour to one of higher grade. In this respect, it would be interesting to review the natural history of those patients with low grade tumours who present with haemorrhage, to see if differs from those that do not.

William T. Couldwell
Salt Lake City, Utah