

CNS lupus

A study of 41 patients

Fady G. Joseph,
MRCP, MD
G. Alistair Lammie,
FRCPATH
Neil J. Scolding,
FRCP, PhD

CME

Address correspondence and
reprint requests to Dr. N.J.
Scolding, Institute of Clinical
Neurosciences, Frenchay
Hospital, Bristol, UK BS16 1LE
n.j.scolding@bristol.ac.uk

ABSTRACT

Background: CNS lupus is a serious but potentially treatable illness, which, though long recognized, may still present very difficult diagnostic challenges. We believed that further detailed study of patients with neuropsychiatric lupus would yield clinical information of practical value in improving both recognition and management of this difficult illness.

Methods: A retrospective case analysis of 41 patients with CNS systemic lupus erythematosus (CNS-SLE) was performed largely in the southwest of England and South Wales, covering the period 1990 to 2002.

Results: We found that primary neurologic presentation of SLE was not rare (10/41 patients), and there was an unexpected emergence of movement disorders (particularly parkinsonism and myoclonus) early in the disease course (4/10 patients). These showed a good response to immunosuppressants, but not to standard dopaminergic therapy. Typically, the erythrocyte sedimentation rate (ESR) or plasma viscosity was elevated during neurologic episodes while C-reactive protein levels were normal, and lupus-related serum antibody tests usually supportive. But, significantly, neither a normal ESR nor negative serology excluded CNS lupus. MR brain imaging is more commonly abnormal in patients with focal neurologic deficits and normal or shows wholly nonspecific change with more diffuse manifestations (cognitive decline, epilepsy). Abnormal CSF correlated significantly with poorer outcome. At the end of the period of study, 54% had no more than minor functional disability, the remainder having a severe or fatal outcome.

Conclusions: Our observations, particularly the emergence of non-choreic movement disorders, the blood, serum, and imaging findings, and the prognostic importance of CSF abnormalities, should help improve both the recognition of CNS systemic lupus erythematosus, perhaps particularly in elderly individuals, and its management. *Neurology*® 2007;69:644-654

Systemic lupus erythematosus (SLE) has a tendency for widespread organ involvement. Its current prevalence is approximately 6 to 50 per 100,000, and its incidence has more than tripled over the last 40 years, from 1.51 per 100,000 during 1950 through 1979 to 5.56 per 100,000 during 1980 through 1992 (adjusted figures), with a statistically significant improvement in survival.¹ Women (especially in the childbearing years) and those of African Caribbean and Asian racial origin are five times more likely to be affected than men or Caucasians.² The diagnosis is now commonly based on the widely accepted revised (1997) diagnostic criteria³ (table 1).

Hebra and Kaposi in 1875 were the first to note CNS involvement in lupus,⁴ and writing on the “erythema group of skin diseases” in 1895, Osler discussed cerebral changes in SLE and reported on a young doctor with SLE and hemiplegia and another patient who “imagines all sorts of things.”⁵ CNS disease is generally associated with a poor prognosis that is only second in severity to renal involvement. Although studies vary, the consensus of opinion suggests that about 50% of SLE patients will have neuropsychiatric phenomena at some time during their illness.⁶⁻¹⁰ However, presentation with

From the Institute of Clinical Neurosciences (F.G.J., N.J.S.), Frenchay Hospital, Bristol, and Department of Pathology (G.A.L.), University of Wales College of Medicine, Cardiff, UK.

Fady Joseph was supported by the Neurological Research Fund established by Dr. M.J. Campbell.

Disclosure: The authors report no conflicts of interest.

Table 1 Diagnosis of systemic lupus erythematosus based on American College of Rheumatology criteria³

Malar rash
Discoid rash
Photosensitivity
Oral ulcers
Arthritis
Serositis (pleurisy or pericarditis)
Renal disorder (proteinuria above 0.5 g/24 h or cellular casts)
Neurologic disorder
Hematologic disorder (hemolytic anemia, leukopenia, or lymphopenia on two or more occasions) or
Immunologic disorder (thrombocytopenia)
Antinuclear antibody

Four of 11 features are required.

neurologic features at the onset of the disease is regarded as rare, occurring only in approximately 3%. A 1999 consensus document defined the neurologic and psychiatric manifestations of SLE.¹¹ The authors proposed that 19 syndromes (table 2) be grouped under the common definition of neuropsychiatric SLE.

The wholly nonspecific nature of these features helps explain why the clinical identification of CNS lupus remains in practice a serious diagnostic challenge, which is complicated by the lack of specific laboratory tests, nonspecific neuroimaging findings, and inaccessible brain parenchyma for histologic confirmation. The possibility of opportunistic infection in individuals who may well have received significant previous immune suppression also contributes to the extraordinarily difficult diagnostic problems lupus patients with neurologic disease may present.¹²

We hypothesized that further detailed study of patients with neuropsychiatric lupus would yield clinical information of practical value in improving the recognition and management of this difficult and serious illness. We therefore identified and have retrospectively studied a large local cohort of patients with CNS-SLE to gain clearer insight to the neurologic features, course, behavior, outlook, and management of neuropsychiatric SLE.

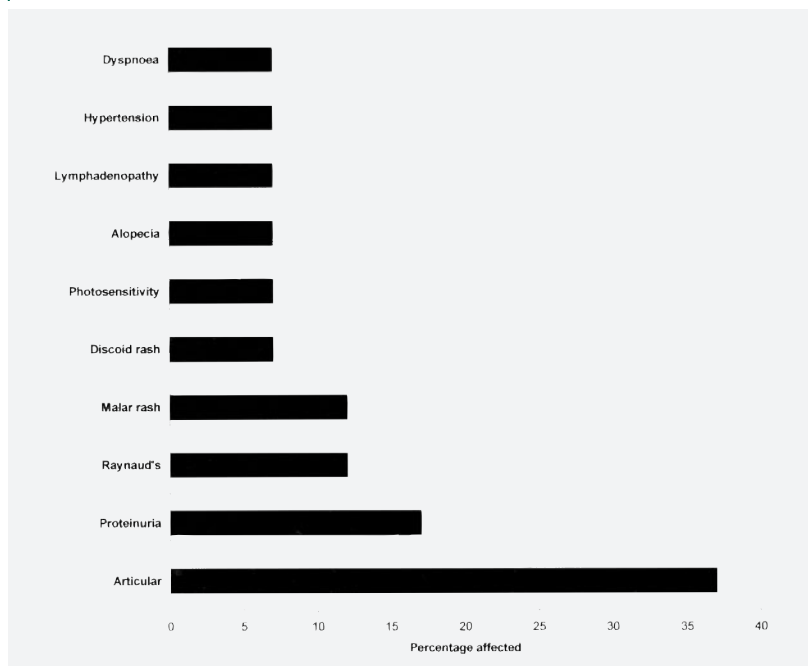
Table 2 Neuropsychiatric manifestations of systemic lupus erythematosus¹¹

Central nervous system
Aseptic meningitis
Cerebrovascular disease
Demyelinating syndrome
Headache (including migraine and idiopathic intracranial hypertension)
Movement disorder (chorea)
Myelopathy
Seizure disorder
Acute confusional state
Anxiety disorder
Cognitive dysfunction
Mood disorder
Psychosis
Peripheral nervous system
Acute inflammatory demyelinating polyradiculopathy (Guillain-Barré syndrome)
Autonomic disorder
Mononeuropathy, single or multiplex
Myasthenia gravis
Cranial neuropathy
Plexopathy
Polyneuropathy

METHODS The case records of patients with CNS-SLE were identified from the hospital records of nine major centers in southwestern England and south Wales, with additional cases from two centers in Edinburgh and Oxford, over a 12-year period. Cases were identified from three main sources: Specific requests were made individually to all neurology and rheumatology specialist consultants (32 patients with CNS lupus were identified through this mechanism). Information analysts at each hospital (using International Classification of Diseases 9th and 10th ed. codes) were consulted: These would have included the diagnosis of CNS lupus from all specialties and departments (seven further patients with CNS lupus were identified through this mechanism). Pathology department records in each hospital were also searched (two additional patients with CNS lupus patients were identified through this route).

Approximately 300 records concerning individuals who had at some stage been suspected of having CNS-SLE were obtained and scrutinized for the certainty of this possibility, using the American College of Rheumatology (ACR) criteria for SLE and CNS involvement (tables 1 and 2). Patients with CNS symptoms attributable to intracranial infections, uremia, or any other suspected secondary causes were excluded from the study. Those patients deemed to have CNS-SLE were then studied for basic demographic details, length of follow-up, CNS features (particularly initial neurologic presentation or “early CNS involvement” compared with “later neurologic involvement” occurring at any time subsequently in the course of the follow up period), systemic (nonneuropsychiatric) features (either prior or subsequent to CNS features), further investigation findings, therapeutic measures,

Figure 1 Frequency of various systemic manifestations occurring prior to neurologic systemic lupus erythematosus



clinical progression, and final outcome. The “outcome” for each admission was recorded as “asymptomatic,” “minor disability” (e.g., mild weakness or sensory disturbance not causing significant functional impairment, or deficit in visual acuity better than 6/12), “moderate disability” (e.g., monoparesis, paraparesis, optic neuropathy reducing visual acuity to 6/12 vision or less, with significant functional impairment), “severe disability” (requiring wheelchair and dependent on others for activities of daily living), or “death.”

Illustrative cases. *Case 1.* A 38-year old Caucasian woman initially presented with attacks of myoclonus and memory impairment and diverse systemic features of SLE such as Raynaud, arthralgia, dyspnea, chest pain, photosensitivity, alopecia, and proteinuria. Renal biopsy confirmed lupus nephritis, supported by neutropenia, lymphopenia, positive antinuclear antibodies (ANA) (1/320), persistently elevated anti-DNA titers, and low complement level. She later had visual difficulties and hallucinations, headaches, fatigue, with evidence of a hemiparesis, dysarthria, ataxia, paranoid delusions, and disinhibition. MRI of brain and spine were normal. EEG and CSF analysis was unremarkable, and CSF oligoclonal bands were absent. She received various immunosuppressant drugs including pulsed methylprednisolone, oral prednisolone, hydroxychloroquine, and azathioprine with relatively little response. A beneficial response was only eventually seen with mycophenolate treatment, which appeared to improve renal function and systemic disease more than CNS features. She had moderate disability over 3 years later with occasional myoclonus (at no stage was there evidence of renal failure sufficient to cause myoclonus).

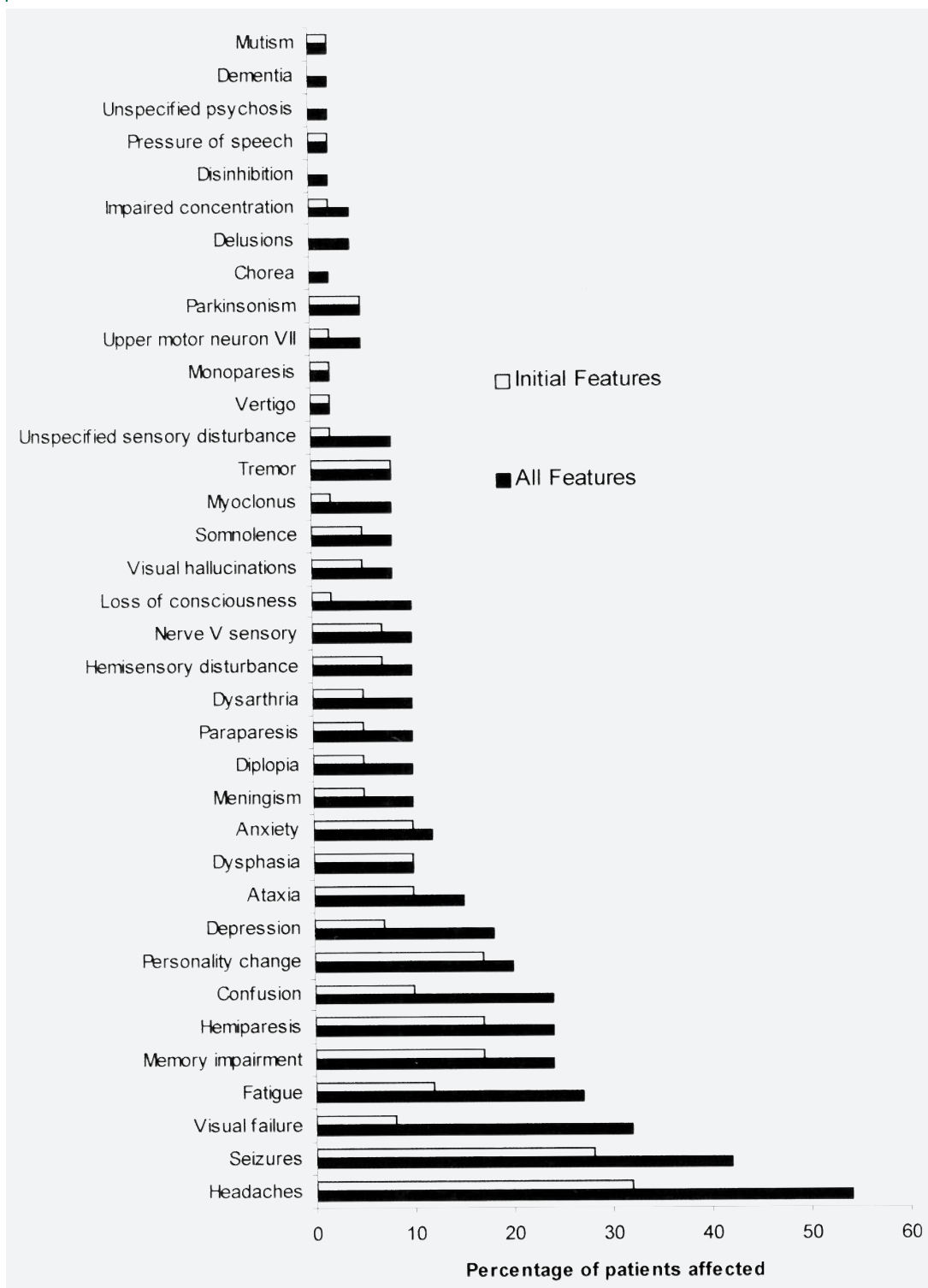
Case 2. A 74-year old Caucasian woman presented with a 1-month history of left facial weakness and a 1-week history of a painful red left eye with diplopia, ptosis, limb tremor, and bradykinesia. When seen, the ocular pain had settled, but not the diplopia and ptosis. Examination re-

vealed an alert, normotensive individual, with a resolving left lower motor neuron facial weakness and a partial left third nerve palsy. She had a classic parkinsonian rest tremor of the right hand with cogwheel rigidity at the right wrist with impaired arm swing on walking. Brain CT was normal. Routine blood tests were normal. Erythrocyte sedimentation rate (ESR) was raised at 64 mm/h and C-reactive protein (CRP) level was <6 g/L. Rheumatoid factor was negative, but ANA was high at 1 in 5,120, anti-DNA antibodies elevated at 371 (normal <75), with low serum complement levels: C3 0.53 g/L (0.75 to 1.65), C4 0.13 g/L (0.14 to 0.54). Three weeks later her partial third nerve lesion had completely resolved spontaneously, but her rest tremor persisted. She had “slightly sore” metacarpophalangeal joints, but there were no other clinical systemic features. Her parkinsonism deteriorated significantly with progressive hypokinesia; both bromocriptine and later levodopa proved ineffectual and were discontinued. Over the next 3 months, she developed a papular urticarial rash over the abdomen and upper legs, with progressive cognitive decline and marked episodic confusion (in the absence of any psychotropic medication), and was admitted for further investigation. The skin lesions were considered compatible with vasculitis. Brain MRI showed nonspecific changes and a few probably ischemic lesions in the brainstem. In view of her dementing illness (abbreviated Mini-Mental Test [MMT] 3/10) and evidence of active lupus, she was started on prednisolone 40 mg and hydroxychloroquine 200 mg b.d. At discharge 1 month later her abbreviated MMT was 8/10, and her parkinsonism was strikingly improved. A further month on, she had only a slight left hand tremor and mild cogwheel rigidity. She experienced an extensive left leg deep vein thrombosis a few days after discharge and was anticoagulated with warfarin as lifelong therapy. Hydroxychloroquine was discontinued uneventfully at 18 months. At 3 years’ follow-up on alternate-day 10 mg of oral prednisolone, with warfarin and dothiepin, she was independent with good cognitive function and little if no evidence of parkinsonism.

Case 3. A 13-year-old girl was diagnosed as having definite SLE on clinical and serologic grounds, with fever, lymphadenopathy, photosensitivity, a malar rash, and proteinuria. She had neutropenia, and serologically was ANF positive and anti-DNA positive; antiphospholipid antibody (APA) titer was within normal limits, and lupus anticoagulant assay was negative/normal; complement levels also were normal. After 6 years of systemic disease, she experienced a generalized seizure; subsequently she developed an abrupt onset of left hemiparesis, accompanied by headaches and progressive impairment of consciousness. Brain CT showed a right hemisphere infarct; her CSF was not examined. Despite treatment with high-dose steroids, her deterioration continued and she died. At postmortem examination, she was found to have SLE-associated cerebral vasculitis (figure 1).

RESULTS Forty-one patients satisfied the criteria for CNS-SLE: 38 women and 3 men. The remaining records were not included as they either had no genuine evidence of CNS-SLE or were perceived to be consequences of secondary factors associated with systemic lupus or its treatment. All were Caucasian apart from one African Caribbean woman. Patients’ case notes included details

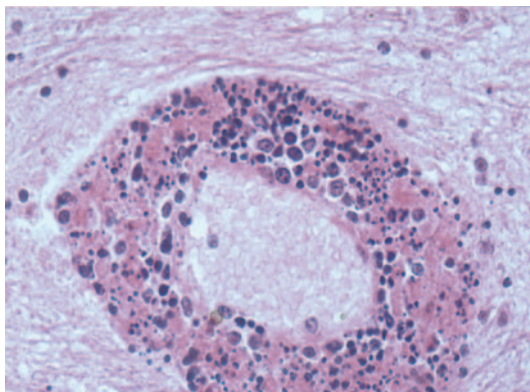
Figure 2 Comparison of neurologic features occurring early in the course of the disease with frequency at any time in the course of the illness



over a total of 4,534 months, with a mean of 111 months (9.2 years) per patient (range 2 to 474 months). Mean age at first neuropsychiatric presentation was 41 years (range 13 to 74 years) and the mean latency of CNS-SLE from initial systemic involvement was 5.75 years (range 0 to 37).

Major non-CNS features. The most commonly reported systemic features were skin and mucosal involvement (malar, vasculitic, discoid or nonspecific rash, photosensitivity, livedo reticularis, alopecia, and oral ulceration) seen in 87% of patients, joint involvement with arthralgia and

Figure 3 Systemic lupus erythematosus-associated vasculitis



Leptomeningeal vessel of a 13-year-old child with a CNS autopsy diagnosis of florid vasculitis associated with systemic lupus erythematosus, leading to a temporoparietal infarction. Widespread evidence of vasculitis was present in the brain in the absence of vasculitis elsewhere, confirming isolated cerebral vasculitis. Acute inflammatory infiltrate is present in the leptomeninges associated with cocci, which were isolated from blood culture. The lesions in the vessel walls appear to vary from older lesions in which the vessel wall is virtually necrotic to more recent lesions in which the acute inflammatory infiltrate is just present. (Photograph courtesy of Dr. G. Alistair Lammie, Consultant Neuropathologist, University Hospital of Wales, Cardiff, UK).

arthropathy (56%), pulmonary involvement (24%), renal disease (20%), hypertension (20%), deep vein thrombosis (17%), Raynaud phenomena (15%), fever (15%), chest pain (12%), anorexia (10%), lymphadenopathy (10%), and myalgia (7%). Less frequently noted were night sweats (5%), pre-eclamptic toxemia (2%), pulmonary embolism (2%), avascular necrosis of the hip (2%), retinal vasculitis (2%), central scotoma (2%), and scleritis (2%).

Skin, joint, and renal involvement were most frequently observed features that preceded CNS complications (figure 2). Their frequency did not differ substantively from their overall frequency during the course of the disease.

Major clinical neurologic, ocular, and psychiatric features. A plethora of CNS manifestations were recorded, but the most commonly reported features were headaches (54%), seizures (42%), visual failure (32%), fatigue (27%), hemiparesis (24%), memory impairment (24%), confusion (24%), personality change (20%), and depression (18%).

A similar pattern of frequency was seen for first neurologic event; a comparison of initial and all CNS features encountered is illustrated in figure 3. However, one exception to this was visual failure, which was significantly more common as

a later rather than early feature of the disease (77 vs 23%) and more likely to be bilateral in late disease (80 vs 20%). Optic neuritis occurred in 3 of 41 cases (7.3%), retinopathy with cotton wool exudates and hemorrhages was observed in 1 of 41 (2.4%), unexplained vitreous hemorrhage was seen in 1 of 41 (2.4%), and scleritis during a flare of SLE in 1 of 41 (2.4%). Uveitis was not reported in our series.

Arterial strokes featured in 17% (seven patients), with a mean age at onset of 36.7 years (range 26 to 50 years). The majority presented with persistent hemimotor and sensory phenomena, dysphasia, or dysarthria, with good clinical-radiologic correlation. Cerebral hemorrhage was noted in two patients and a subarachnoid hemorrhage in another. No case of venous sinus thrombosis was identified (though MR venography was not performed on all patients). There were no other relevant risk factors (hypertension, diabetes mellitus, hypercholesterolemia, or smoking history) in any but one patient who had a pre-existing treated hypertension. Four of seven had transthoracic echocardiography: None showed any source of emboli. IgG APA was elevated in two of seven (29%), and one of these was diagnosed as having a secondary antiphospholipid syndrome.

Two patients had spinal cord involvement in this study with MRI spinal changes. Prior systemic features preceded both cases of myelopathy in this current series.

CNS manifestations as presenting feature of SLE. CNS manifestations as the initial presenting feature of SLE occurred in 10 patients (24%). The ACR criteria for SLE require that at least four characteristic features occur at any time during the disease course, not necessarily simultaneously. Although these criteria were not fulfilled at this early stage, the later emergence of more typical features of the disease confirmed the diagnosis in each case. Various manifestations were observed, but movement disorders (four cases), seizures (four cases), or meningism (two cases) featured. Of the four with movement disorders, one had hemichorea, one had myoclonus, and two had parkinsonism (e.g., see Cases 1 and 2). There was very strong evidence for parkinsonism and cognitive impairment being directly related to SLE in one case with supportive typical clinical and investigation findings and a dramatic improvement in the movement disorder and mental state of this patient with immunosuppression (Case 2).

Investigation findings. Blood tests and serology. One patient was pancytopenic, four thrombocytopenic, 3 neutropenic, and 5 lymphopenic. The ESR or plasma viscosity was elevated in 17 of 34 patients (50%). The CRP was elevated in 3 of 34 (9%). ANA level results were available in 34 patients at the time of a neuropsychiatric episode, and 29 (85%) were significantly elevated. Anti-DNA antibody results were documented in 29 cases at the time of illness, and 21 (72%) were positive. There was no association between the above blood test results and clinical outcome.

Serum complement results were available in 26 patients, and 11 (42%) showed abnormally low C3 and/or C4 levels, but 17 (66%) of complement levels were normal during a typical neurologic disease flare-up. Of patients with a relatively good outcome (asymptomatic or minor disability), 4 of 12 (33%) of subjects tested had low serum complement levels, whereas in those with adverse outcomes, 7 of 14 (50%) showed hypocomplementemia (p value 0.22 by Fisher exact test).

Thirteen of 29 (45%) were APA positive; just one of these patients was thought to have secondary APA syndrome, with lupus anticoagulant activity. Thirty-three percent of patients with asymptomatic or minor final outcomes were APA positive compared with 55% in the other outcome groups (p value 0.18 by Fisher exact test). Of nine stroke patients, two had elevated IgG APA. Five of 29 (17%) were lupus anticoagulant positive, with only 1 patient being lupus anticoagulant positive and APA negative.

Spinal fluid examination. CSF analysis was performed in 23 cases with abnormal results in 39%. There was an elevation in CSF protein in five (22%) with a range of 0.67 to 2.43 g/L. A lymphocytic pleocytosis was seen in five (22%) patients (range of 8 to 95 lymphocytes/mm³) and was associated with a raised CSF protein in three cases. Oligoclonal bands were present in 4 of 18 (22%) and were associated with other CSF abnormalities in 2 of these.

Of patients with normal CSF, 77% had eventual minor disability, and 23% with moderate, severe disability or death. The converse was true of abnormal CSF ($p = 0.01$, Fisher exact test).

Radiology. CT brain scans results were available for 25 patients. Sixteen were normal, whereas nine (36%) showed abnormalities: Three had patchy low attenuation areas, two had intracranial hemorrhage, and four demonstrated infarcts (two within the basal ganglia and two cortical).

MRI brain scans were performed on 31 patients. Eleven (36%) were normal. Of the remainder, 10 showed nonspecific white matter lesions, 3 had periventricular white matter changes, 2 showed subcortical lesions, 2 had evidence of intracranial hemorrhage, 1 had infarcts in the basal ganglia and parietal cortex, 1 showed leptomeningeal enhancement, and 1 MRI supported clinical evidence of optic neuritis. Of the patients with normal scans, 64% (7/11) had diffuse CNS features such as headaches, meningism, memory impairment, confusion, and seizures, and the remaining 36% had focal events such as monoparesis, hemiparesis, and hemisensory symptoms in the absence of MRI brain lesions. Of those with abnormal MR scans, 14 of 20 (70%) had focal clinical features and 6 of 20 (30%) diffuse phenomena ($p = 0.06$, Fisher exact test).

Four patients had spinal MRI: Two were normal, and the others showed areas of increased signal in the cervical spine (both C5 to C6) suggesting cervical inflammation.

One patient had normal digital subtraction angiography (and a normal CT and brain MRI). One other patient, with evidence of unilateral infarcts in the basal ganglia and the parietal cortex, had "spasm of the circle of Willis" reported from MR angiography of the brain.

EEG. EEG was abnormal in 11 of 14 (79%) patients tested, showing nonspecific generalized slowing. A "liability to seizures" was also reported in three of these.

Treatment and outcome. The final outcome at the end of the follow-up study period was recorded. Five patients (12%) were asymptomatic, 17 (42%) had minor disability, 12 (32%) moderate disability, 2 (5%) severe disability, and 5 (12%) had died. Nine (22%) of patients only had one neuropsychiatric attack, 14 (34%) had a further episode, 11 (27%) had three separate episodes, 6 (15%) had four separate attacks, and 1 patient had seven episodes of neuropsychiatric manifestations. There was no apparent relationship between the number of clinical neuropsychiatric relapses and the final outcome.

Thirty-six received steroid therapy either as methylprednisolone pulses and oral prednisolone. Of these, four were given steroids alone, but the remainder were given combination therapy with antiplatelet agents or warfarin only (2 patients) or with more potent immunosuppressants (35 patients). Cyclophosphamide was used in nine patients, all of whom had been severely affected: Following treatment, four had eventual minor disability and four were left severely disabled.

One of these died. Ten patients received azathioprine; two of these emerged asymptomatic, five were deemed to have minor disability, two had moderate disability, and one died. Cyclophosphamide and azathioprine were used in succession in four cases. Hydroxychloroquine was used in 12 patients: One was left asymptomatic, seven had only minor disability, three moderate disability, and one had died. Plasmapheresis was used in two patients, one of whom had moderate disability outcome and one eventual death. Hydroxychloroquine was given in conjunction with azathioprine in five patients and with cyclophosphamide in two patients. IV immunoglobulin therapy was given to two patients. Other treatments tried were cyclosporin in one patient and mycophenolate in another.

One patient received no treatment at all and made a full recovery after a monophasic illness with headache, an episode of transient loss of consciousness, and a probable partial seizure. Six patients in this series were anticoagulated with warfarin, and this was the sole treatment in one patient following a stroke. Two patients were given symptomatic treatment with antiepileptic drugs only (one had an asymptomatic outcome and the other died as a result of an intracerebral hemorrhage). One was given a combination of antiplatelet and antiepileptic drugs and had severe neurologic disability following her severe illness with marked headaches, visual failure, ataxia, paraparesis, and seizures. Two patients were given antiparkinsonian medication in conjunction with steroids and various immunosuppressants.

Histopathology. Of five deaths, two were autopsied. One 23-year-old woman had extensive bilateral hemorrhagic infarction involving the caudate nucleus and putamen, along with typical microscopic features of the disease. The second autopsy was that of a 13-year-old girl with definite clinical and serologic evidence of SLE. After careful examination by two experienced neuropathologists, she received a postmortem diagnosis of “cerebral vasculitis associated with SLE.” Although true CNS vasculitis in SLE is regarded as being rare, she was found to have widespread vasculitis of the brain and leptomeninges (in the absence of vasculitis elsewhere), with a clinically eloquent infarction in the right cerebral hemisphere probably caused by occlusion from necrosis and acute inflammatory infiltrate of small vessels associated with the vasculitic process (figure 1).

DISCUSSION In summary, we have identified features that may aid the recognition and diagno-

sis of this difficult illness. Primary neurologic presentation of SLE was commoner than anticipated (10/41 patients) and included both seizures (4 cases) and an unexpected emergence of movement disorders such as parkinsonism and myoclonus (4 cases).

Seizures are already known to occur in 14 to 25% of lupus patients compared with 0.5 to 1% in the general population.¹³ They are usually primary generalized, but partial episodes also occur. Our study suggested a higher overall frequency: 42% (usually with other CNS and systemic features). They were an early manifestation in 27%, and in 10% were the first SLE symptom. Seizures as an early CNS manifestation are also well described (often erroneously diagnosed as isolated epilepsy¹⁴), with reported frequencies of 8 to 27%,^{8,15-18} more frequent in children (9.4 to 51%, mean = 35%).¹⁹⁻²⁶

The higher figures in our study must be viewed cautiously: it is not community based and clearly prone to neurologic case-ascertainment bias. But, arguably, other surveys set in rheumatology departments might easily have missed some neurologic cases. The real frequency of the various neurologic features we found to be commoner than other studies, if exaggerated in our study, might nonetheless be higher than currently considered.

Movement disorders were not included in the ACR criteria. Chorea has been regarded as a “hallmark feature” of SLE, though, in fact, is uncommon, seen in under 4% of patients.^{8,15,27,28} We noted only one case (2.4%), as the presenting manifestation of SLE, responding to corticosteroids. There are few reports of myoclonus in SLE, none as a presenting feature.²⁹⁻³¹

Parkinsonism (Case 2) is very rare in SLE, not even mentioned in the major series.^{8,9,15,16,20} We found 26 cases reported in 16 publications from 1930.³²⁻⁴⁷ Rest tremor is reported as a first manifestation of SLE,^{48,49} but SLE presenting with overt parkinsonism has only been documented once before, in a 24-year-old man who also had a hemiplegia and thrombocytopenia, with T2 MRI hyperintensities in the brainstem, occipital and parietal lobes, thalamus, and internal capsule; he showed almost complete recovery after steroids.³⁹ Other reported cases followed SLE diagnosis by months or years. Presentation at the age of 74 (our Case 2) is most unusual. Other cases were 9 to 57 years (mean 23 years), parkinsonism thus having been considered a juvenile SLE manifestation, often associated with severe multisystem CNS involvement. A previous case series of CNS-

SLE in the elderly⁵⁰ revealed subacute confusional state, dementia, and depression associated with the disease and, as with our study, suggested that SLE is more common in this group than originally thought and is treatment responsive.

Our Case 2 was elderly, but her very clear parkinsonian features failed to respond to dopaminergic agents. Although only CNS histology could prove whether this was coincidence of idiopathic Parkinson disease (or multisystem atrophy, etc.) and CNS lupus, the dramatic sustained improvement in both cognitive function and parkinsonism following prednisolone and hydroxychloroquine strongly suggested that CNS lupus was indeed responsible and that one neurologic condition, not two, was present. Partial or complete recovery was seen in nearly all other reported cases, commonly after immune therapy. The mechanisms underlying parkinsonism in SLE are unknown; both direct immune-mediated effects and indirect consequences such as vasculopathy and coagulopathy are the likely principal mechanisms of CNS lupus, and immunologically both B- and T-cell-related mechanisms are implicated.⁵¹⁻⁵³ A strong case for antibodies cross-reacting with neuronal antigens has emerged.^{41,52}

Of other features, 54% of our patients had headaches and 27% migraine. Only 7 of 14 (50%) of our APA-positive individuals had significant headache, consistent with the reported absence of any direct link between migraines and APA.⁵⁴ Arterial strokes featured in 17% of patients, similar to other studies.^{8,16,20,55} The important and well-validated observation that cognitive dysfunction in SLE is commonly reversible⁵⁶ is also supported: All our cases improved either before or following steroid treatment (also supporting reports that true “lupus psychosis” exists and is not simply a steroid-induced phenomenon).⁵⁷ Two patients (5%) had an aseptic meningitis, confirming its documented relative rarity,^{17,55} but in both, isolated meningism was the presenting feature of SLE.

Myelopathy, seen in just two of our cases, is an infrequent though serious manifestation.^{8,16,17,20,58} Cranial nerve involvement is also relatively uncommon and usually transient.^{59,60}

Visual disturbance, the third commonest symptom in our study, is known to be frequent in SLE and to involve any ocular structure.^{61,62} Visual difficulties were significantly more likely to be bilateral (80%) and to occur late in the disease course (77%). Migraine may account for reversible visual phenomena (probably five cases). There was clinical evidence of optic neuritis in 3

of 41 of our cases (7.3%), comparable with other studies.⁶³ Retinopathy has been more frequently observed with cotton wool exudates (indicative of local retinal ischemia) and hemorrhages (one patient).

The classic finding of a low CRP but elevated ESR or plasma viscosity was seen in 44% of patients. Importantly (as other studies have shown), anti-DNA antibody testing is positive in only about 70% of CNS episodes. There was one positive anti-P result in a patient with depression, confusion, and headaches, but this test was not routinely offered by most units in our study. APA were present in 45% of those tested, consistent with the 16 to 60% reported.⁶⁴⁻⁶⁶ Two of nine stroke patients in this study had elevated APA, both IgG.

CSF abnormalities were seen in 39% of our patients, comparable with other studies. The frequency of CSF oligoclonal bands has varied between reports,^{7,67,68} our results supporting a lower figure of 22%.

Thirty-six percent of CT brain scans were abnormal, and 65% of MR scans, but CT remains valuable in identifying hemorrhages and larger infarcts. Perisulcal cortical atrophy is reported as a frequent finding on CT,⁶⁹ but was not seen in our study. MRI features were often nonspecific, though often differed with the clinical pattern of CNS disease: Abnormal scans were associated with focal neurologic deficits, normal scans with more diffuse phenomena such as headaches, meningism, memory impairment, confusion, and generalized seizures. Clinical–radiologic correlates are not always obvious; MRI lesions may resolve completely within days in keeping with clinical improvement or persist despite clear remission.

Seventy-nine percent had a diffusely abnormal EEG. The reported selective left temporolimbic region changes⁷⁰ were not observed in our study. EEG may be useful in confirming the organic nature of the illness and in distinguishing steroid-induced from primary lupus psychosis.

We have avoided the term “lupoid sclerosis,”⁷¹ which may imply mechanistic similarities between SLE and multiple sclerosis. Although neuro-SLE may mimic multiple sclerosis clinically, pathologic studies clearly show them to be very distinct disorders.^{72,73} We found no cases where there had been any such diagnostic ambiguity.

Two previous studies suggested that articular disease may be “protective” and associated with a reduced chance of CNS involvement,^{74,75} but our study demonstrated the opposite—37% of indi-

viduals with CNS lupus had prior joint involvement—as have others.³⁵ Although ANA and anti-DNA results did not appear to have any bearing on disease outcome or CNS relapse rate, an abnormal CSF was associated with a poor prognosis.

ACKNOWLEDGMENT

The authors are grateful for the enthusiastic support and cooperation of their colleagues in neurology and rheumatology departments throughout the southwest of England and south Wales and in Oxford and Edinburgh.

Received January 1, 2007. Accepted in final form March 12, 2007.

REFERENCES

1. Uramoto KM, Michet CJ Jr, Thumboo J, Sunku J, O'Fallon WM, Gabriel SE. Trends in the incidence and mortality of systemic lupus erythematosus, 1950–1992. *Arthritis Rheum* 1999;42:46–50.
2. Molokhia M, McKeigue PM, Cuadrado M, Hughes G. Systemic lupus erythematosus in migrants from west Africa compared with Afro-Caribbean people in the UK. *Lancet* 2001;357:1414–1415.
3. Hochberg MC. Updating the American College of Rheumatology revised criteria for the classification of systemic lupus erythematosus. *Arthritis Rheum* 1997;40:1725–.
4. Hebra F, Kaposi M. On diseases of the skin, including exanthema. New Sydenham Society, London. 1875;4:1–247.
5. Osler W. On the visceral complications of erythema exudativum multiforme. *Am J Med Sci* 1895;110:629–646.
6. McCune WJ, Golbus J. Neuropsychiatric lupus. *Rheum Dis Clin North Am* 1988;14:149–167.
7. van Dam AP. Diagnosis and pathogenesis of CNS lupus. *Rheumatol Int* 1991;11:1–11.
8. Sanna G, Bertolaccini ML, Cuadrado MJ, et al. Neuropsychiatric manifestations in systemic lupus erythematosus: prevalence and association with antiphospholipid antibodies. *J Rheumatol* 2003;30:985–992.
9. Feinglass EJ, Arnett FC, Dorsch CA, Zizic TM, Stevens MB. Neuropsychiatric manifestations of systemic lupus erythematosus: diagnosis, clinical spectrum, and relationship to other features of the disease. *Medicine (Baltimore)* 1976;55:323–339.
10. Dubois EL, Tuffanelli DL. Clinical Manifestations of systemic lupus erythematosus. Computer analysis of 520 cases. *JAMA* 1964;190:104–111.
11. The American College of Rheumatology nomenclature and case definitions for neuropsychiatric lupus syndromes. *Arthritis Rheum* 1999;42:599–608.
12. Cha JH, Furie K, Kay J, Walensky RP, Mullins ME, Hedley-Whyte ET. Case records of the Massachusetts General Hospital. Case 39-2006. A 24-year-old woman with systemic lupus erythematosus, seizures, and right arm weakness. *N Engl J Med* 2006;355:2678–2689.
13. Mikdashi J, Krumholz A, Handwerker B. Factors at diagnosis predict subsequent occurrence of seizures in systemic lupus erythematosus. *Neurology* 2005;64:2102–2107.
14. Toubi E, Khamashta MA, Panarra A, Hughes GR. Association of antiphospholipid antibodies with central nervous system disease in systemic lupus erythematosus. *Am J Med* 1995;99:397–401.
15. Brey RL, Holliday SL, Saklad AR, et al. Neuropsychiatric syndromes in lupus: prevalence using standardized definitions. *Neurology* 2002;58:1214–1220.
16. Afeltra A, Garzia P, Mitterhofer AP, et al. Neuropsychiatric lupus syndromes: relationship with antiphospholipid antibodies. *Neurology* 2003;61:108–110.
17. Costallat L, Bertolo M, Appenzeller S. The American College of Rheumatology (ACR) nomenclature and case definitions for neuropsychiatric lupus syndromes. Analysis of 527 patients. *Lupus* 2001;10.
18. Jonsen A, Bengtsson AA, Nived O, Ryberg B, Sturfelt G. Outcome of neuropsychiatric systemic lupus erythematosus within a defined Swedish population: increased morbidity but low mortality. *Rheumatology (Oxford)* 2002;41:1308–1312.
19. Parikh S, Swaiman KF, Kim Y. Neurologic characteristics of childhood lupus erythematosus. *Pediatr Neurol* 1995;13:198–201.
20. Sibbitt WL Jr, Brandt JR, Johnson CR, et al. The incidence and prevalence of neuropsychiatric syndromes in pediatric onset systemic lupus erythematosus. *J Rheumatol* 2002;29:1536–1542.
21. Loh WF, Hussain IM, Soffiah A, Lim YN. Neurological manifestations of children with systemic lupus erythematosus. *Med J Malaysia* 2000;55:459–463.
22. Quintero-Del-Rio AI, Van M. Neurologic symptoms in children with systemic lupus erythematosus. *J Child Neurol* 2000;15:803–807.
23. Harel L, Sandborg C, Lee T, von Scheven E. Neuropsychiatric manifestations in pediatric systemic lupus erythematosus and association with antiphospholipid antibodies. *J Rheumatol* 2006;33:1873–1877.
24. Baca V, Lavalle C, Garcia R, et al. Favorable response to intravenous methylprednisolone and cyclophosphamide in children with severe neuropsychiatric lupus. *J Rheumatol* 1999;26:432–439.
25. Steinlin MI, Blaser SI, Gilday DL, et al. Neurologic manifestations of pediatric systemic lupus erythematosus. *Pediatr Neurol* 1995;13:191–197.
26. Reiff A, Miller J, Shaham B, Bernstein B, Szer IS. Childhood central nervous system lupus; longitudinal assessment using single photon emission computed tomography. *J Rheumatol* 1997;24:2461–2465.
27. Janavs JL, Aminoff MJ. Dystonia and chorea in acquired systemic disorders. *J Neurol Neurosurg Psychiatry* 1998;65:436–445.
28. Guttman M, Lang AE, Garnett ES, et al. Regional cerebral glucose metabolism in SLE chorea: further evidence that striatal hypometabolism is not a correlate of chorea. *Mov Disord* 1987;2:201–210.
29. Aarli JA. Immunological aspects of epilepsy. *Brain Dev* 1993;15:41–49.
30. Feinfeld DA, Scholnick HR, Janis R. Lupus nephritis in a neuronal storage disease. *Arch Intern Med* 1977;137:693–694.
31. Noto M, Kato M, Takeda R, Izaki K, Kitagawa M. [Case of systemic lupus erythematosus (SLE) with giant

- cell arteritis of the brain causing akinetic mutism and myoclonus]. *Rinsho Shinkeigaku* 1975;15:743–751.
32. Miyoshi Y, Atsumi T, Kitagawa H, et al. Parkinson-like symptoms as a manifestation of systemic lupus erythematosus. *Lupus* 1993;2:199–201.
 33. Osawa H, Yamabe H, Kaizuka M, et al. Systemic lupus erythematosus associated with transverse myelitis and parkinsonian symptoms. *Lupus* 1997;6:613–615.
 34. Shahar E, Goshen E, Tauber Z, Lahat E. Parkinsonian syndrome complicating systemic lupus erythematosus. *Pediatr Neurol* 1998;18:456–458.
 35. Garcia-Moreno JM, Chacon J. Juvenile parkinsonism as a manifestation of systemic lupus erythematosus: case report and review of the literature. *Mov Disord* 2002;17:1329–1335.
 36. Kwong KL, Chu R, Wong SN. Parkinsonism as unusual neurological complication in childhood systemic lupus erythematosus. *Lupus* 2000;9:474–477.
 37. Tan EK, Chan LL, Auchus AP. Reversible parkinsonism in systemic lupus erythematosus. *J Neurol Sci* 2001;193:53–57.
 38. Chacon J, Garcia-Moreno JM, Valencia J, et al. [Parkinson disease of juvenile onset with systemic lupus erythematosus in a pre-symptomatic stage]. *Rev Neurol* 1999;29:725–727.
 39. Lim SM, Oldfield M, Abbott RJ. Systemic lupus erythematosus presenting with steroid-responsive parkinsonism and post-hemiplegic dystonia. *Eur J Neurol* 1998;5:309–312.
 40. Fabiani G, Teive HA, Germiniani FM, Sa DS, Werneck LC. Reversible parkinsonian syndrome in systemic and brain vasculitis. *Mov Disord* 2002;17:601–604.
 41. Kunas RC, McRae A, Kesselring J, Villiger PM. Antidopaminergic antibodies in a patient with a complex autoimmune disorder and rapidly progressing Parkinson's disease. *J Allergy Clin Immunol* 1995;96:688–690.
 42. Yancey CL, Doughty RA, Athreya BH. Central nervous system involvement in childhood systemic lupus erythematosus. *Arthritis Rheum* 1981;24:1389–1395.
 43. Willoughby EO, Cardon L, Rubnitz ME. Clinicopathologic conference: psychotic episodes, meningitis and chest pain. *Postgrad Med* 1964;35:318–326.
 44. Nagaoka S, Kato K, Ishigatsubo Y, et al. [A case of systemic lupus erythematosus with akinesia, muscle rigidity and neurogenic bladder]. *Ryumachi* 1984;24:382–388.
 45. Poch G. Enfermedades del colágeno. Manifestaciones neurológicas, musculares y psiquiátricas. Buenos Aires: Lopez Libreros Editores SRL, 1960.
 46. Seminario C, Pessano J. Cuatro casos clínicos de lupus eritematoso agudo. *Sem Med (B Air)* 1930;2:721–730.
 47. Morales-Buenrostro LE, Tellez-Zenteno JF, Estanol B. [Symptomatic hemiparkinsonism with abnormal SPECT in a patient with systemic lupus erythematosus (SLE)]. *Neurologia* 2002;17:391–393.
 48. Tola MR, Granieri E, Caniatti L, et al. Systemic lupus erythematosus presenting with neurological disorders. *J Neurol* 1992;239:61–64.
 49. Venegoni E, Biasioli R, Lamperti E, Rinaldi E, Salmaggi A, Novi C. Tremor as an early manifestation of systemic lupus erythematosus. *Clin Exp Rheumatol* 1994;12:199–201.
 50. Dennis MS, Byrne EJ, Hopkinson N, Bendall P. Neuropsychiatric systemic lupus erythematosus in elderly people: a case series. *J Neurol Neurosurg Psychiatry* 1992;55:1157–1161.
 51. Kammer GM, Mishra N. Systemic lupus erythematosus in the elderly. *Rheum Dis Clin North Am* 2000;26:475–492.
 52. Scolding NJ, Joseph FG. The neuropathology and pathogenesis of systemic lupus erythematosus. *Neuropathol Appl Neurobiol* 2002;28:173–189.
 53. Trysberg E, Carlsten H, Tarkowski A. Intrathecal cytokines in systemic lupus erythematosus with central nervous system involvement. *Lupus* 2000;9:498–503.
 54. Markus HS, Hopkinson N. Migraine and headache in systemic lupus erythematosus and their relationship with antibodies against phospholipids. *J Neurol* 1992;239:39–42.
 55. Ainiala H, Loukkola J, Peltola J, Korpela M, Hietaharju A. The prevalence of neuropsychiatric syndromes in systemic lupus erythematosus. *Neurology* 2001;57:496–500.
 56. Hanly JG, Liang MH. Cognitive disorders in systemic lupus erythematosus. *Epidemiologic and clinical issues. Ann NY Acad Sci* 1997;823:60–68.
 57. Wekking EM. Psychiatric symptoms in systemic lupus erythematosus: an update. *Psychosom Med* 1993;55:219–228.
 58. Kovacs B, Lafferty TL, Brent LH, DeHoratius RJ. Transverse myelopathy in systemic lupus erythematosus: an analysis of 14 cases and review of the literature. *Ann Rheum Dis* 2000;59:120–124.
 59. Chandrasekaran AN, Rajendran CP, Ramakrishnan S, Madhavan R, Parthiban M. Childhood systemic lupus erythematosus in south India. *Indian J Pediatr* 1994;61:223–229.
 60. Keane JR. Eye movement abnormalities in systemic lupus erythematosus. *Arch Neurol* 1995;52:1145–1149.
 61. Peponis V, Kytтары VC, Tyradellis C, Vergados I, Sitaras NM. Ocular manifestations of systemic lupus erythematosus: a clinical review. *Lupus* 2006;15:3–12.
 62. Yap EY, Au Eong KG, Fong KY, et al. Ophthalmic manifestations in Asian patients with systemic lupus erythematosus. *Singapore Med J* 1998;39:557–559.
 63. Al-Mayouf SM, Al-Hemidan AI. Ocular manifestations of systemic lupus erythematosus in children. *Saudi Med J* 2003;24:964–966.
 64. Merkel PA, Chang Y, Pierangeli SS, Convery K, Harris EN, Polissos RP. The prevalence and clinical associations of anticardiolipin antibodies in a large inception cohort of patients with connective tissue diseases. *Am J Med* 1996;101:576–583.
 65. Escalante A, Brey RL, Mitchell BD Jr, Dreiner U. Accuracy of anticardiolipin antibodies in identifying a history of thrombosis among patients with systemic lupus erythematosus. *Am J Med* 1995;98:559–565.
 66. Gulko PS, Reveille JD, Koopman WJ, Burgard SL, Bartolucci AA, Alarcon GS. Anticardiolipin antibodies in systemic lupus erythematosus: clinical correlates, HLA associations, and impact on survival. *J Rheumatol* 1993;20:1684–1693.
 67. West SG, Emlen W, Wener MH, Kotzin BL. Neuropsychiatric lupus erythematosus: a 10-year prospective study on the value of diagnostic tests. *Am J Med* 1995;99:153–163.
 68. McLean BN, Miller D, Thompson EJ. Oligoclonal banding of IgG in CSF, blood-brain barrier function,

- and MRI findings in patients with sarcoidosis, systemic lupus erythematosus, and Behcet's disease involving the nervous system. *J Neurol Neurosurg Psychiatry* 1995;58:548–554.
69. Zanardi VA, Magna LA, Costallat LT. Cerebral atrophy related to corticotherapy in systemic lupus erythematosus (SLE). *Clin Rheumatol* 2001;20:245–250.
70. Glanz BI, Laoprasert P, Schur PH, Robertson-Thompson A, Khoshbin S. Lateralized EEG findings in patients with neuropsychiatric manifestations of systemic lupus erythematosus. *Clin Electroencephalogr* 2001;32:14–19.
71. Fulford KW, Catterall RD, Delhanty JJ, Doniach D, Kremer M. A collagen disorder of the nervous system presenting as multiple sclerosis. *Brain* 1972;95:373–386.
72. Ellis SG, Verity MA. Central nervous system involvement in systemic lupus erythematosus: a review of neuropathologic findings in 57 cases, 1955–1977. *Semin Arthritis Rheum* 1979;8:212–221.
73. Johnson RT, Richardson EP. The neurological manifestations of systemic lupus erythematosus. *Medicine (Baltimore)* 1968;47:337–369.
74. Karassa FB, Ioannidis JP, Touloumi G, Boki KA, Moutsopoulos HM. Risk factors for central nervous system involvement in systemic lupus erythematosus. *Q J Med* 2000;93:169–174.
75. Vlachoyiannopoulos PG, Karassa FB, Karakostas KX, Drosos AA, Moutsopoulos HM. Systemic lupus erythematosus in Greece. Clinical features, evolution and outcome: a descriptive analysis of 292 patients. *Lupus* 1993;2:303–312.

Did you know . . .

. . . you can browse by subspecialty topics on www.neurology.org?

Go to: <http://www.neurology.org/collections> and click on the specific topic for a complete list of articles.