

Surgery of intracranial aneurysms previously treated endovascularly

Wuttipong Tirakotai^{a,*}, Ulrich Sure^a, Yuhua Yin^a, Ludwig Benes^a,
Dirk Michael Schulte^a, Siegfried Bien^b, Helmut Bertalanffy^a

^a Department of Neurosurgery, Philipps University, Marburg, Germany

^b Department of Neuroradiology, Philipps University, Marburg, Germany

Received 5 March 2007; received in revised form 21 May 2007; accepted 26 May 2007

Abstract

Objective: To perform a retrospective study on the patients who underwent aneurysmal surgery following endovascular treatment.

Patients and methods: We performed a retrospective study on eight patients who underwent aneurysmal surgery following endovascular treatment (-attempts) with Guglielmi detachable coils (GDCs). The indications for surgery, surgical techniques and clinical outcomes were analyzed.

Results: The indications for surgical treatment after GDC coiling of aneurysm were classified into three groups. First group: surgery of incompletely coiled aneurysms ($n=4$). Second group: surgery of mass effect on the neural structures due to coil compaction or rebleeding ($n=2$). Third group: surgery of vascular complications after endovascular procedure due to parent artery occlusion or thrombus propagation from aneurysm ($n=2$). Aneurysm obliterations could be performed in all cases confirmed by postoperative angiography. Six patients had an excellent outcome and returned to their profession. Patient's visual acuity was improved. One individual experienced right hemiparesis (grade IV/V) and hemihypesthesia.

Conclusions: Microsurgical clipping is rarely necessary for previously coiled aneurysms. Surgical treatment is uncommonly required when an acute complication arises during endovascular treatment, or when there is a dynamic change of a residual aneurysm configuration over time that is considered to be insecure.

© 2007 Elsevier B.V. All rights reserved.

Keywords: Intracranial aneurysm; Postembolization surgery; Previously coiled aneurysm; Regrowth of aneurysm

1. Introduction

Since the introduction of GDC technique in 1990, endovascular treatment has become an alternative to surgery for aneurysm treatment [10]. Despite advances in endovas-

cular technology, some patients may develop clinical or radiological evidence of residual or regrowing of aneurysms, which may require further treatment [4,10,12,15,16,23]. As the use of the endovascular technique becomes more widespread, various complications after endovascular treatment were reported in several circumstances, in which neurovascular surgery seems to be an appropriate treatment alternative [2,6,23].

The literature on the surgical management of previously coiled aneurysms is limited [3,6,10,12,15,19,23,25]. The present retrospective study aims to report our experience in eight additional cases in which surgical intervention was necessary after endovascular procedures. Surgical management was performed either because of incomplete obliteration or regrowth of aneurysms, or due to complications related to the acute endovascular therapy. The surgical strategies

Abbreviations: A2, anterior cerebral artery second portion; AcomA, anterior communicating artery; BA, basilar artery; CT, computed tomography; F, female; GDCs, Guglielmi detachable coils (GDCs); H&H, Hunt and Hess Grade; ICA, internal carotid artery; Lt, left; M, male; MCA, middle cerebral artery; OphA, ophthalmic artery; PcomA, posterior communicating artery; PICA, posterior inferior cerebellar artery; Rt, right; SAH, subarachnoid hemorrhage; VA, visual acuity

* Corresponding author at: Neurochirurgische Klinik, der Philipps Universität Marburg, Baldingerstrasse, 35033 Marburg, Germany.
Tel.: +49 6421 2866447; fax: +49 6421 2866415.

E-mail address: tirakotai@gmx.de (W. Tirakotai).

Table 1

Patients underwent surgical treatment of aneurysm after previously coiled embolization

Case no.	Age/sex	Presentation	Aneurysm location	Surgical indication	Interval ^a	Surgical approach	Surgical technique	Results	Outcome
1	58/F	Referred case	Lt OphA	Residual neck of aneurysm	4 years	Lt pterional craniotomy	Partial coil-removal	Complete occlusion of aneurysm	Excellent
2	31/F	SAH H&H II	Rt PcomA	Residual neck of aneurysm	4 weeks	Rt pterional craniotomy	Subtotal coil-removal	Complete occlusion of aneurysm	Excellent
3	62/F	SAH H&H IV	BA apex and Lt. PICA	Regrowth of aneurysm	25 months	Rt pterional craniotomy	All coils remained	Complete occlusion of aneurysm	Excellent
4	36/F	Mild headache	Rt. PcomA	Incomplete coiling, newly formed of two small aneurysms at the aneurysmal neck	4 months	Rt pterional craniotomy	Partial removal of coils with thrombus	Complete occlusion of aneurysm	Excellent
5	61/F	Asymptomatic multiple aneurysms	Rt OphA and Lt. PcomA	Decreased VA due to optic nerve compression	22 months	Rt. pterional craniotomy	Anterior clinoidectomy, subtotal removal of coils, optic nerve decompression	Complete occlusion of aneurysm	Good, diplopia remains
6	58/M	Incidental finding	AcomA	Dense packing of aneurysm, mass effect with occlusion of Lt. A2 branch	2 h	Rt pterional craniotomy	Removal of all coils and thrombus, revascularization of left A2	Complete occlusion of aneurysm	Excellent
7	37/F	SAH H&H III	Lt VA–PICA	Failed embolization, thrombus formation in the aneurysm and Lt. proximal PICA	3 h	Lt far lateral craniotomy	Thrombus removal and revascularization of left PICA	Complete occlusion of aneurysm	Excellent
8	49/F	SAH H&H II	Lt MCA	Postendovascular intracerebral hematoma	3 h	Lt pterional craniotomy	Clot removal, inspection of coiled aneurysm	Complete occlusion of aneurysm	Hemiparesis grade IV/V

F, female; M, male; H&H, Hunt&Hess Grade; SAH, subarachnoid hemorrhage; VA, visual acuity; Lt, left; Rt, right; OphA, ophthalmic artery; PcomA, posterior communicating artery; BA, basilar artery; AcomA, anterior communicating artery; VA–PICA, vertebral artery–posterior inferior cerebellar artery; MCA, middle cerebral artery; A2, anterior cerebral artery second portion; h, hours.

^a Interval period between endovascular and surgical treatment.

and indications as well as the clinical outcome are analyzed.

2. Patients and methods

Between 1998 and 2005, 650 aneurysms were treated either by surgical clipping or endovascular in equal ratio. Eight patients (seven females) with previously coiled intracranial aneurysms underwent surgical interventions in our department. The mean age of this group of patients was 49 years (range of 31–62 years). Table 1 summarizes the clinical presentation, aneurysm location, intervals between coiling and surgery, surgical indication, results, and outcomes. Some of these cases are illustrated below.

3. Illustrative cases

3.1. Case 2 (residual neck)

A 31-year-old female was presented with a Hunt and Hess Grade II subarachnoid hemorrhage (SAH) secondary

to a right posterior communicating artery (PcomA) aneurysm (Fig. 1A). GDC embolization resulted in significant residual filling, which was observed on the follow-up arteriography performed at 2 weeks (Fig. 1B). No additional coils could be delivered because of the aneurysm's size and configuration. Therefore, surgical clipping and coil extraction was done via a right pterional approach. Small amount of coils had to be left due to their adhesion to the aneurysmal wall (Fig. 1C and D). She made a good recovery and returned to work 2 months after operation.

3.2. Case 3 (regrowth of aneurysm)

A 62-year-old female was presented with H&H IV, SAH. Cerebral arteriogram revealed a basilar tip aneurysm and a left posterior inferior cerebellar artery (PICA) aneurysm (Fig. 2A). The basilar tip aneurysm was initially treated by GDC embolization (Fig. 2B). Two months later, the patient underwent surgical clipping of the left PICA aneurysm. Two-year follow-up angiography demonstrated the obliteration of left PICA aneurysm and a regrowth of the basilar tip aneurysm (Fig. 2C). Re-coiling of the regrowing aneurysm

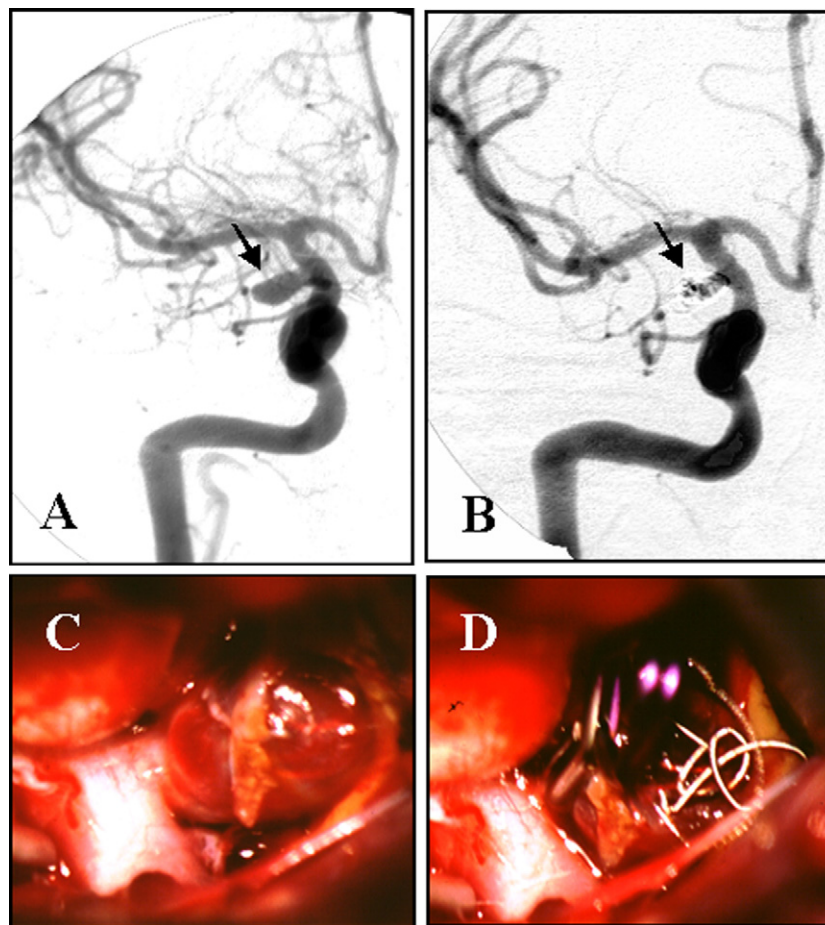


Fig. 1. (A) Right internal carotid (ICA) arteriogram demonstrating a right posterior communicating artery aneurysm (arrow). (B) Two-week postembolization arteriogram showing the residual neck of aneurysm (arrow). (C) Intraoperative photograph revealing aneurysm sac distended by coils. (D) Aneurysm is clipped and coils are removed through the wall of aneurysm.

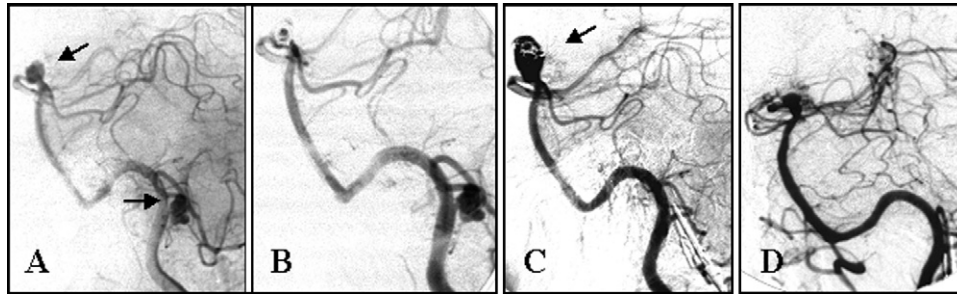


Fig. 2. (A) Left vertebral arteriogram revealing a basilar tip aneurysm and a left PICA aneurysm (arrows). (B) The basilar aneurysm is subtotally occluded by coils, while the PICA is left initially untreated. (C) Follow-up angiogram performed 2 years after coil embolization demonstrating a regrowth of basilar tip aneurysm (arrow) but an obliterated PICA aneurysm. (D) One-year follow-up angiogram after clipping of basilar aneurysm.

was not successful. Therefore, the patient underwent aneurysmal neck clipping without coil extraction via right pterional approach. Postoperative course was uneventful. The postoperative angiogram revealed complete obliteration of both aneurysms (Fig. 2D). The patient made a good recovery and returned to normal daily activities after 3 months.

3.3. Case 4 (newly formed aneurysm)

A 36-year-old female was initially treated at other institution with surgical wrapping of a complex right PcomA aneurysm in 1985. In the year 1999, GDC embolization of the aneurysm was performed and resulted in 90% occlu-

sion (Fig. 3A). Three month follow-up angiography revealed two newly formed aneurysms at the neck of incompletely coiled aneurysm (Fig. 3B). Repeated embolization was not amenable, and the patient underwent surgical clipping of proximal aneurysm neck by means of a right pterional craniotomy. After temporary occlusion of the right internal carotid artery (ICA) and opening of aneurysmal fundus, thrombotic materials with coils were extracted (Fig. 3D). Afterwards, two clips were applied to the aneurysm neck (Fig. 3E). Postoperative computed tomography (CT) imaging revealed no brain infarction or intracranial hemorrhage. Follow-up angiogram revealed a complete aneurysm clipping (Fig. 3C). The patient returned to her work after 3 months.

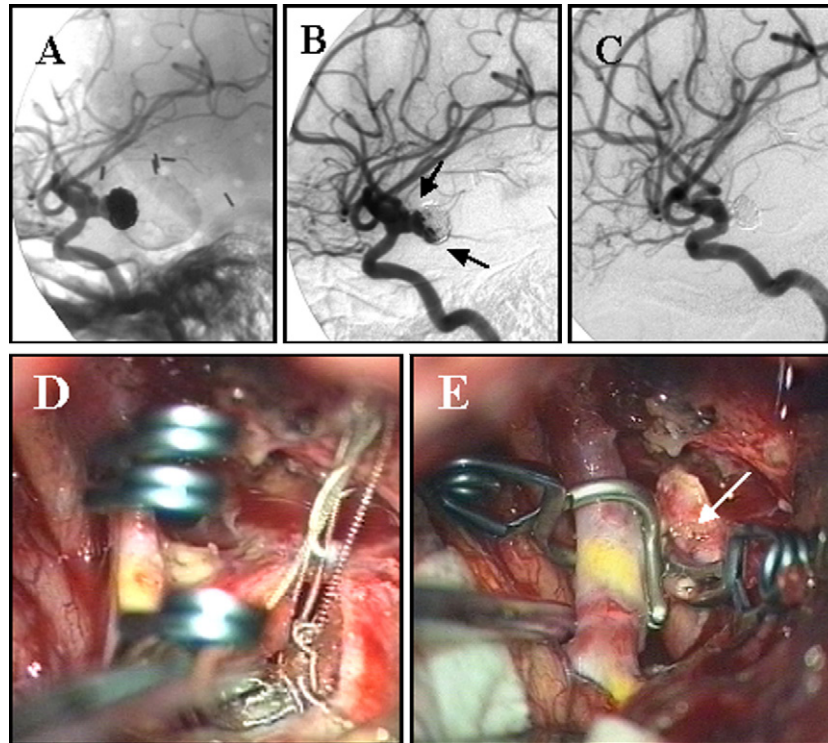


Fig. 3. (A) Preembolization lateral angiogram showing a right large PcomA aneurysm. (B) Follow-up angiogram performed 3 months after embolization; the coils have compacted the body and fundus of aneurysm, leaving a portion of the neck patent together with two newly formed aneurysms (arrows). (C) After clipping of the aneurysm and partial removal of coils, angiogram demonstrating complete obliteration of PcoA aneurysm. (D) Intraoperative photograph showing temporary occlusion of right ICA and removal of coils with thrombotic material. (E) Intraoperative microscopic view after clip application. Arrow indicates the remained aneurysmal sac.

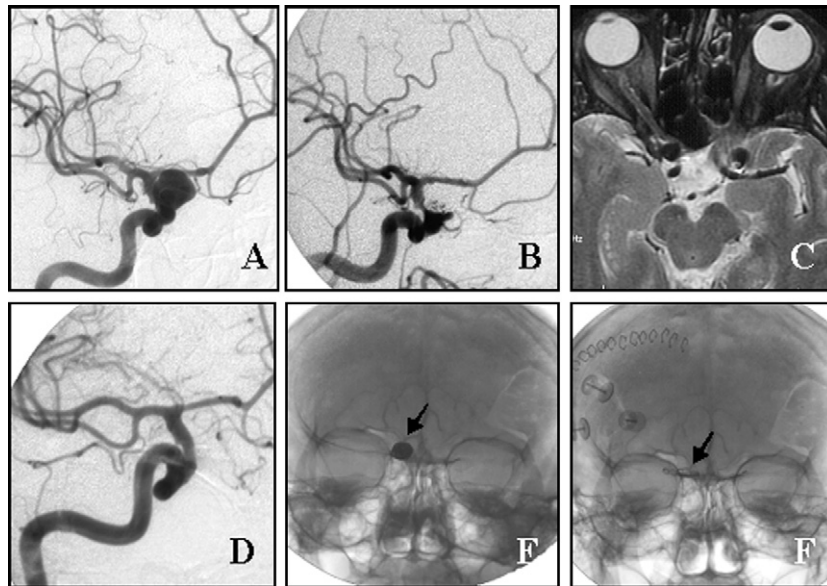


Fig. 4. (A) Diagnostic arteriogram revealing a right ophthalmic artery aneurysm. (B) Twenty-two month after embolization, patient developed decreased right visual acuity. Two-year post-coiling arteriogram demonstrating 90% occlusion of aneurysm. (C) Preoperative MRI showing the compressed right optic nerve by the coils ball. (D) Postoperative arteriogram demonstrating complete obliteration of aneurysm. (E and F) Pre- and post-operative skull X-ray showing the position of packing coils and the position of clips after coil removal, respectively (arrows).

3.4. Case 5 (optic nerve compression)

A 61-year-old female was presented with asymptomatic multiple aneurysms (a right ophthalmic artery aneurysm and a left PcomA aneurysm). The patient underwent GDC embolization of a right OphA aneurysm (Fig. 4A) and a surgical clipping of a left PcomA aneurysm. Two-year follow-up angiography revealed a 90% obliteration of the right OphA (Fig. 4B), and the patient developed the decreased visual acuity and diplopia of the right eye due to the optic nerve compression (Fig. 4C). Right pterional craniotomy and extradural drilling of the right anterior clinoid process was performed. The coils with an associated thrombus were removed through an incision on the aneurysmal dome after temporary occlusion of right ICA. Postoperative angiography revealed the complete exclusion of the aneurysm (Fig. 4D). The patient

made a good recovery from surgery. The right visual acuity was improved, but her diplopia remained.

3.5. Case 6 (endovascular occlusion of the parent artery)

A 58-year-old head injury patient was referred from another institution with an incidentally found anterior communicating artery (AcomA) aneurysm (Fig. 5A). With informed consent, the patient underwent coiling of the aneurysm. A left A2 occlusion caused by the dense compaction of coils was seen on immediate post-coiling arteriogram (Fig. 5B). To prevent the cerebral infarction, the patient underwent an emergency surgical intervention via a right pterional craniotomy. Temporary occlusions of both sides of A1 and right A2 arteries were required. The

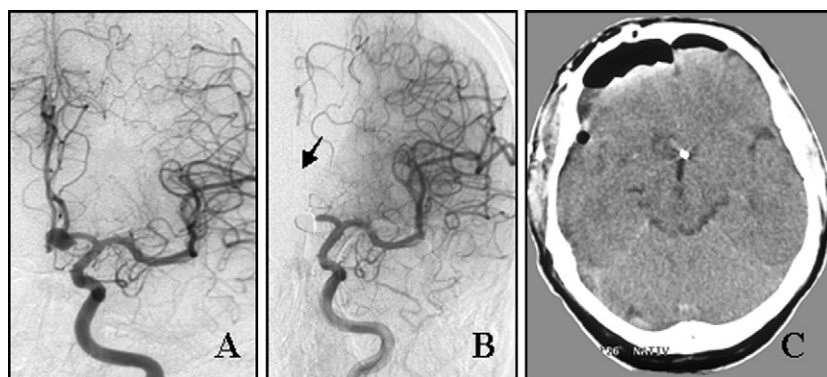


Fig. 5. (A) Preembolization arteriogram demonstrating the left anterior communicating artery aneurysm. (B) Immediate postembolization arteriogram showing a dense packing of aneurysm and an occlusion of left A2. (C) Postoperative CT scan demonstrating no hemispheric infarction.

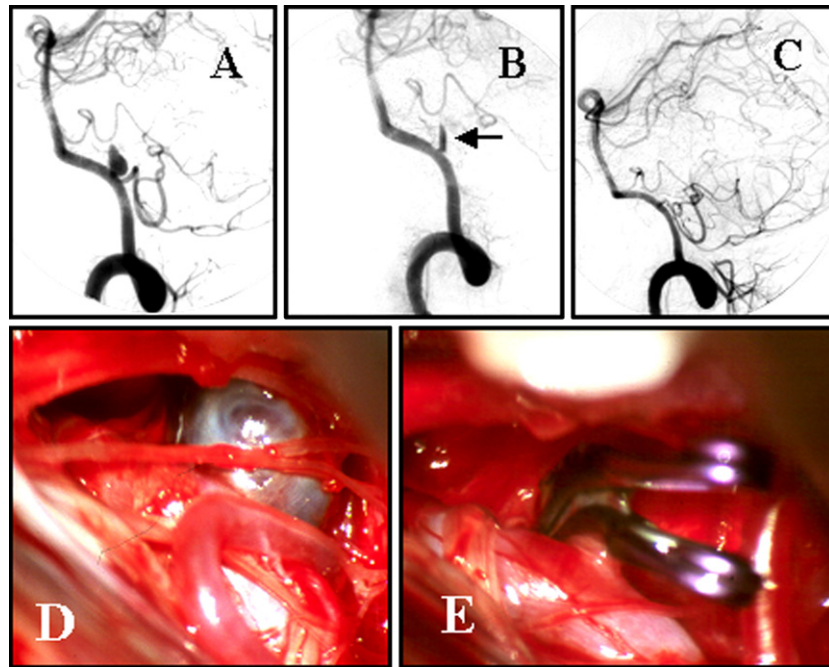


Fig. 6. (A) Left vertebral digital subtraction angiogram (DSA) demonstrating VA–PICA aneurysm. (B) Left PICA cannot be seen on immediate postembolization arteriogram due to the thrombus formation in the aneurysm and its propagation to the left proximal PICA (arrow). (C) Arteriogram obtained after aneurysm clipping and thrombectomy, complete aneurysm obliteration has been achieved. (D) Fundus of aneurysm is distended by the whole thrombus after an unsuccessful coil embolization. (E) Intraoperative photograph after aneurysm clipping and thrombectomy.

aneurysm fundus was incised, and the coils were extracted. Subsequently, the left A2 was revascularized by surgical thrombectomy. Finally the aneurysm was occluded with a clip. One month after surgery, the patient returned to his daily works.

3.6. Case 7 (propagation of thrombosis causes vascular occlusion)

A 37-year-old female was presented with a H&H III SAH secondary to left PICA aneurysm (Fig. 6A). Endovascular therapy was attempted, but the coil had to be removed due to no proper coil available for the aneurysm. Immediate post-intervention arteriogram revealed a thrombosis of left PICA, and an endovascular therapy could not reestablish the lumen patency (Fig. 6B). This was a result of the thrombus formation in the aneurysm and its propagation to the left proximal PICA. After the endovascular procedure, the patient underwent immediate surgical revascularization and clipping of aneurysm using a left far lateral (transcondylar) approach. Postoperative course was uneventful. Postoperative angiogram revealed the revascularized left PICA and the complete obliteration of aneurysm (Fig. 6C). The patient returned to professional career after 3 months.

3.7. Case 8 (intracerebral hematoma)

A 49-year-old female patient was presented with a H&H II SAH. Cerebral arteriogram revealed a left middle cerebral

artery (MCA) aneurysm, and the aneurysm was obliterated by coils. Pretreatment CT showed no intracranial hematoma. Three hours after intervention, the patient awoke from sedation, and a right hemiplegia and hemihypesthesia were noted. Posttreatment CT scan revealed a large right basal ganglia hematoma (5 cm × 6 cm) with a 7 mm midline shift. Patient underwent an emergency craniotomy, and the clot was removed. The previously coiled aneurysm was inspected. Neither coil perforation nor leakage of blood from the site of aneurysm was observed. Subsequently, the patient developed hydrocephalus and required a shunt placement. One-year after operation, completely occluded aneurysm could be demonstrated on follow-up angiogram, but patient still experienced a grade IV/V hemiparesis.

4. Results

4.1. Surgical findings

The intraoperative appearance of aneurysm sac was translucent and distended by coils in seven cases (cases 1–6, 8) (Fig. 1C). In case 7, the fundus of aneurysm was distended by the whole thrombus after an unsuccessful coil embolization (Fig. 6D). Whereas the temporary occlusion was inevitably performed in five cases (cases 3–7) during the clipping procedures, two aneurysms were clipped without temporary occlusion of parent vessel (cases 1 and 2). In consideration of the time interval between the embolization and

surgery which may anticipate the risk of irreparable vessel tear if performing the coil extraction, all coils were left in one patient (case 3) after the surgical obliteration of aneurysm. Partial or complete removal of coils was performed in five cases using microscissors (cases 1, 2, 4–6).

4.2. Postoperative course and outcome

The average follow-up period for this series was 64.25 months (range: 18–84 months). All patients experienced an uneventful postoperative course. In two emergent revascularized cases (cases 6 and 7), cerebral infarction was not detected on postoperative CT scans. In all patients, successful obliteration of the aneurysm was confirmed by postoperative angiography. Six individuals had an excellent outcomes and returned to their professional activities (cases 1–4, 6, 7). In case 5, the visual acuity improved but the diplopia remained. One patient experienced a severe right hemiparesis (grade IV/V) and hemihypesthesia (case 8).

5. Discussion

Endovascular intervention for both ruptured and unruptured intracranial aneurysm is gaining wide acceptance as an alternative treatment [1,8,9,11,14] or as a complementary therapy to neurosurgical procedures especially in the management of complex intracranial aneurysms [16]. Although numbers of successful coiling procedures have elevated according to the increasing experience and improved technology [13], there are also increasing numbers of patient referred for further neurosurgical treatment due to neck remnants, regrowth or persistent mass effect as well as complications after endovascular procedures [6]. However, microsurgical clipping is uncommonly necessary for previously coiled aneurysms. In our present study, we described several circumstances requiring surgical intervention after GDC coiling of aneurysms by dividing them into three groups.

5.1. Surgical treatment of residual neck and regrowth of previously coiled aneurysm

Studies of long-term results after GDC coiling revealed that 80% of treated aneurysms were almost totally occluded (95%) [22], or stable angiographic occlusion was evident in more than 85% of aneurysm [2,13]. Therefore, at least 15–20% of previously coiled patients may exhibit growth of a residual neck, if final occlusion is not accomplished by thrombosis, fibrosis and endothelialization of the aneurysmal neck. Especially, younger people are at higher risk of developing larger aneurysms possibly originating of small remnants [17]. Although the long-term natural history of incompletely coiled aneurysms remains unknown [12], growth of residual neck and refilling of the fundus after coiling had been described [12,25]. When an occlusion after endovascular

treatment is incomplete, and the aneurysm is considered as an insecure, a multidisciplinary decision-making process should be carried out. Some authors recommended that an additional embolization procedure should be performed whenever it is possible, if the endovascular technique is not feasible, a surgical procedure may be considered [4,10,25]. In four of our cases (cases 1–4), the neuroradiologist regarded further endovascular intervention as too dangerous. At present, these problems might be solved with the sophisticated stent technology and increasing experiences of neurointerventionists.

Surgical clipping of previously coiled of aneurysm is not simple and may be hazardous. When clipping of the aneurysmal neck is difficult because loops of the coils are localized within the neck region or are even herniated into the parent vessel, some authors have proposed the removal of the protruding coils [3,12,25] or performing follow-up angiography of the aneurysm until the neck is coil-free [10,23]. In addition, other techniques such as ligation of the neck, coagulation of the fundus and additional wrapping may be useful [4]. In some instances, the coils should be left in the aneurysm if they have been placed in the aneurysm for a long time in order to prevent vessel tear occurring after coil extraction [23]. According to our experience, we would recommend the following strategy:

- (1) If the coils cause a mass effect on vital structures, the coils should be removed (cases 5 and 6).
- (2) If the coils migrate into the parent vessel or into the neck of aneurysm precluding the clip placement, the coils should be extracted (cases 1, 2, 4).
- (3) If the coils have been placed for a rather long period, we consider that they may be strongly adherent to the wall of the aneurysm or the parent vessel, and in such situation coil extraction may cause irreparable vessel tear. In such a situation, we would rather leave remnant coils in situ (cases 1–5).

After occlusion of aneurysm, patients should undergo follow-up angiography to visualize the obliteration and the possible regrowth of aneurysm.

5.2. Surgical treatment of persistent mass effect on cranial nerve or brain parenchyma

Aneurysms at specific locations may occasionally cause neurological symptoms due to their mass effect [18]. Such patients might require surgical decompression. For instance, previously embolized large or giant paraclinoid aneurysms can cause local mass effect to the optic nerve (case 5). In previously embolized aneurysms, the goals of treatment are to reduce the mass effect as well as to prevent hemorrhage. The success rate of surgery is variable, as the damage may be irreversible, and surgery itself may produce complications affecting the same structure [18,23]. In the treatment of optic nerve compression by coil compaction, we decided to perform surgical clipping of the aneurysm, coil extraction

and decompression of the optic nerve in order to rescue the impaired vision. In the literature, 37 % of the large or giant aneurysms tended to shrink after an embolization, however, it took a 2–12 months period [24]. Therefore, we decided to treat these patients, in order to reach an early decompression and not to take the risk for a subacute but irreversible damage to the optic nerve.

Rebleeding after coiling of ruptured cerebral aneurysms may require emergency surgical intervention and can be classified into early and late type according to the studies of Sluzewski and Jan van Rooij [20,21]. The incidence of both early (1.4%) and late (1.27%) rebleeding is low, but is a major concern due to its high mortality rate [20,21]. Similar results of late rebleeding rates between 1% and 2% have been reported elsewhere [1,11,14]. In our series, one individual (case 8) developed hemiparesis after endovascular intervention as a result of a large intracerebral hematoma and underwent emergency craniotomy. The reason of this bleeding could not be verified even under direct inspection of the coiled aneurysm. The hemorrhage might have been taken place during the induction of the narcosis for the endovascular treatment, because the patient presented with no hemiparesis, and the pre-interventional CT scan was normal. Additionally, during the intraprocedural angiogram there was no leakage of contrast media detected, which might have indicated a leakage. The aneurysm was well packed with coils which could be demonstrated on postinterventional angiogram and under direct surgical inspection. In assessing management of this particular case, removal of intracerebral hematoma and surgical inspection of the embolized aneurysm was considered appropriate enough to treat the increased intracranial pressure and to verify the cause of rebleeding. Close patient's observation and imaging follow-up after endovascular therapy (in this case: the immediate posttreatment CT) may help alleviating unfavorable consequences.

5.3. Surgical treatment of vascular complications after an endovascular procedure

Vascular complications associated with endovascular treatment of aneurysms include intracranial hemorrhage and ischemic sequelae. Intracranial hemorrhage may occur due to aneurysm rupture and vessel perforation from microcatheter or guidewire [7,10], or erosion of the aneurysm wall from compact coils [6]. The rupture can frequently be sealed with the rapid deposition of further coils into the aneurysm lumen and immediate administration of protamine, and surgical evacuation may be necessary in extreme situations [10]. Embolization can be continued in most cases, and most patients with treatment-related SAH survive without serious sequelae [7].

Ischemic symptoms following coil embolization may be acute or delayed. Patients can develop the ischemic symptoms as a result of coil migration in parent vessels [6] or from persistent mass effect of coil impaction on parent ves-

sels (case 6). In addition, thrombosed parent vessels can also develop immediately after a failed attempt of embolization (case 7). There is no doubt, that thrombosed parent might be reperfused with intravenous platelet GP IIb/IIIa. However, emergency surgery remains the treatment of choice in these cases, when an endovascular therapy could not reestablish the lumen. The coils with associated thrombus (case 6) or fresh thrombus (case 7) could be removed without difficulty through an incision at the aneurysm dome after temporary occlusion of parent vessel. In some instances which evolve hemispheric ischemia following ICA occlusion, emergency extracranial–intracranial bypass may be indicated to restore cerebral blood flow [10]. The likelihood of a successful outcome increases if the revascularized procedure is performed within 6 h [5], or immediately following intraprocedural occlusion as demonstrated in our two patients. Therefore, a neurosurgical team should be available to perform an emergency surgery following endovascular complications in a neurovascular center.

6. Conclusion

In spite of the widespread of endovascular management of aneurysm, neurosurgical treatment remains a viable option for treating previously coiled aneurysms. Surgical treatment is uncommonly required when an acute complication arises during endovascular treatment, or when there is a dynamic change of the aneurysm configuration over time that is considered to be insecure without feasible endovascular therapy option. Immediate revascularization and decompression of a mass effect remain the unique advantages of the surgical therapy. We believe that a modern neurovascular center should consist of a well-cooperating interventional and surgical team that discusses every single case in details and looks for the optimal treatment in individual single patient. This neurovascular team should be prepared to change the treatment regimen in emergency cases, if necessary at any time.

Acknowledgement

Wuttipong Tirkaotai is a fellow of Alexander-von-Humboldt Foundation in the years 2005–2006.

References

- [1] Bavinszki G, Killer M, Gruber A, Reinprecht A, Gross CE, Richling B. Treatment of basilar artery bifurcation aneurysms by using Guglielmi detachable coils: a 6-year experience. *J Neurosurg* 1999;90:843–52.
- [2] Byrne JV, Sohn MJ, Molyneux AJ, Chir B. Five-year experience in using coil embolization for ruptured intracranial aneurysm: outcomes and incidence of late rebleeding. *J Neurosurg* 1999;90:656–63.
- [3] Civit T, Auque J, Marchal JC, Bracard S, Picard L, Henri H. Aneurysm clipping after endovascular treatment with coils: a report of eight patients. *Neurosurgery* 1996;38:955–61.

- [4] Conrad MD, Pelissou-Guyotat I, Morel C, Madarassy G, Schonauer C, Deruty R. Regrowth of residual ruptured aneurysms treated by Guglielmi's detachable coils which demanded further treatment by surgical clipping: report of 7 cases and review of the literature. *Acta Neurochir (Wien)* 2002;144:419–26.
- [5] Crowell RM. Emergency cerebral revascularization. *Clin Neurosurg* 1986;33:281–305.
- [6] Deinsberger W, Mewes H, Traupe H, Boeker DK. Surgical management of previously coiled intracranial aneurysms. *Br J Neurosurg* 2003;17:149–54.
- [7] Doerfler A, Wanke I, Egelhof T, Dietrich U, Asgari S, Stolke D, et al. Aneurysmal rupture during embolization with Guglielmi detachable coils: causes, management, and outcome. *Am J Neuroradiol* 2001;22:1825–32.
- [8] Gnanalingham KK, Apostolopoulos V, Barazi S, O'Neill K. The impact of the international subarachnoid aneurysm trial (ISAT) on the management of aneurysmal subarachnoid haemorrhage in a neurosurgical unit in the UK. *Clin Neurol Neurosurg* 2006;108:117–23.
- [9] Gruber A, Killer M, Bavinski G, Richling B. Clinical and angiographic results of endosaccular coiling treatment of giant and very large intracranial aneurysms: a 7-year, single-center experience. *Neurosurgery* 1999;45:793–804.
- [10] Gurian JH, Martin NA, King WA, Duckwiler GR, Guglielmi G, Vinuela F. Neurosurgical management of cerebral aneurysms following unsuccessful or incomplete endovascular embolization. *J Neurosurg* 1995;83:843–53.
- [11] Hope JK, Byrne JV, Molyneux AJ. Factors influencing successful angiographic occlusion of aneurysms treated by coil embolization. *Am J Neuroradiol* 1999;20:391–9.
- [12] Horowitz M, Purdy P, Kopitnik T, Dutton K, Samson D. Aneurysm retreatment after Guglielmi detachable coil and nondetachable coil embolization: report of nine cases and review of the literature. *Neurosurgery* 1999;44:712–9.
- [13] Kawabe T, Tenjin H, Hayashi Y, Kakita K, Kubo S. Midterm prevention of rebleeding by Guglielmi detachable coils in ruptured intracranial aneurysms less than 10 mm. *Clin Neurol Neurosurg* 2006;108:163–7.
- [14] Kuether TA, Nesbit GM, Barnwell SL. Clinical and angiographic outcomes, with treatment data, for patients with cerebral aneurysms treated with Guglielmi detachable coils: a single-center experience. *Neurosurgery* 1998;43:1016–25.
- [15] Ladouceur DL. Transcranial clipping of recurrent cerebral aneurysms after endovascular treatment. *Stroke* 1993;24:1087–9.
- [16] Lawton MT, Quinones-Hinojosa A, Sanai N, Malek JY, Dowd CF. Combined microsurgical and endovascular management of complex intracranial aneurysms. *Neurosurgery* 2003;52:263–74.
- [17] Lin T, Fox AJ, Drake CG. Regrowth of aneurysm sacs from residual neck following aneurysm clipping. *J Neurosurg* 1989;70:556–60.
- [18] Malisch TW, Guglielmi G, Vinuela F, Duckwiler G, Gobin YP, Martin NA, et al. Unruptured aneurysms presenting with mass effect symptoms: response to endosaccular treatment with Guglielmi detachable coils. Part I. Symptoms of cranial nerve dysfunction. *J Neurosurg* 1998;89:956–61.
- [19] Mizoi K, Yoshimoto T, Takahashi A, Nagamine Y. A pitfall in the surgery of a recurrent aneurysm after coil embolization and its histological observation: technical case report. *Neurosurgery* 1996;39:165–9.
- [20] Sluzewski M, van Rooij WJ. Early rebleeding after coiling of ruptured cerebral aneurysms: incidence, morbidity, and risk factors. *Am J Neuroradiol* 2005;26:1739–43.
- [21] Sluzewski M, van Rooij WJ. Late rebleeding of ruptured intracranial aneurysms treated with detachable coils. *Am J Neuroradiol* 2005;26:2542–9.
- [22] Thornton J, Debrun GM, Aletich VA, Bashir Q, Charbel FT, Ausman J. Follow-up angiography of intracranial aneurysms treated with endovascular placement of Guglielmi detachable coils. *Neurosurgery* 2002;50:239–50.
- [23] Thornton J, Dovey Z, Alazzaz A, Misra M, Aletich VA, Debrun GM, et al. Surgery following endovascular coiling of intracranial aneurysms. *Surg Neurol* 2000;54:352–60.
- [24] Tsuura M, Terada T, Nakamura Y, Nakai K, Itakura T. Magnetic resonance signal intensity and volume changes after endovascular treatment of intracranial aneurysms causing mass effect. *Neuroradiology* 1998;40:184–8.
- [25] Zhang YJ, Barrow DL, Cawley CM, Dion JE. Neurosurgical management of intracranial aneurysms previously treated with endovascular therapy. *Neurosurgery* 2003;52:283–95.