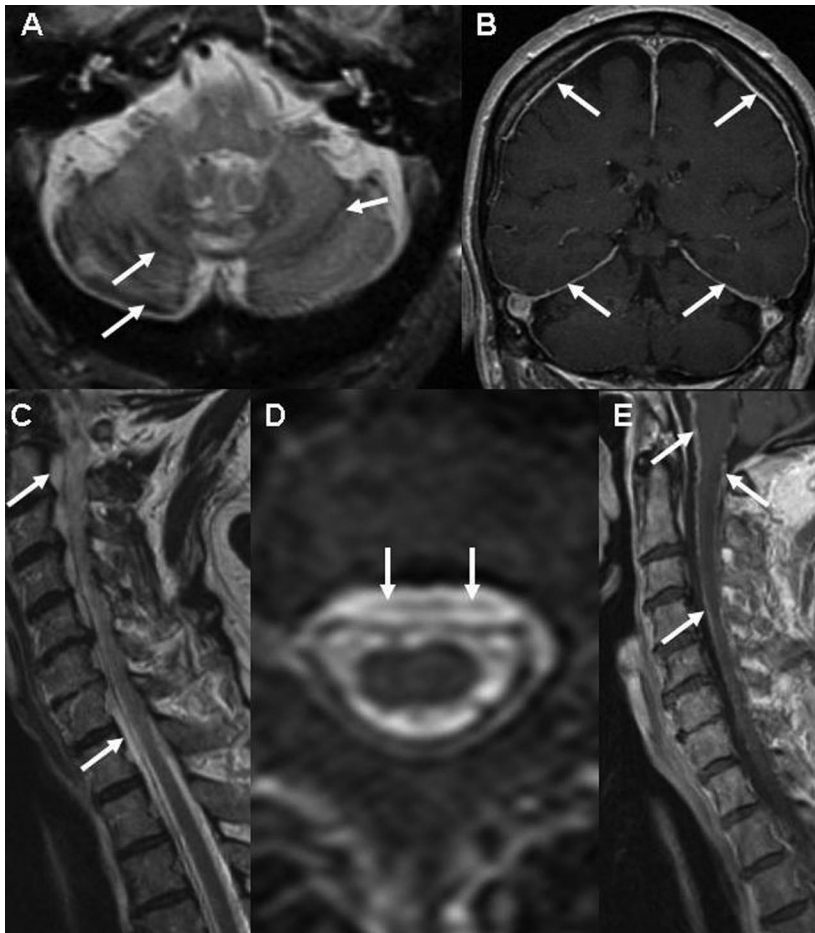

(A) T2-weighted axial image from a head MRI shows hemosiderin deposition along the cerebellar folia. (B) T1-weighted coronal head MRI with contrast shows prominent dural enhancement. (C, D) Sagittal (C) and axial (D) T2-weighted images from a spine MRI shows the extraarachnoid fluid collection in the spinal canal ventral to the cord. (E) Sagittal T1-weighted image from a spine MRI with contrast shows the abnormal linear enhancement along the surface of the cord.

siderable elevation in the spinal fluid RBC count.<sup>6</sup> This likely relates to vascular engorgement that accompanies CSF hypovolemia. Imaging evidence of engorgement of intradural and epidural veins may be seen with CSF hypovolemia.<sup>6,7</sup> Similar findings have been noted in SS.<sup>2</sup> The workup in patients with SS often includes angiography directed at finding a possible bleeding source. An

obvious bleeding source is generally not recognized. In a similar case of SS reported earlier, vascular engorgement seen on spine MRI led to angiography with negative results.<sup>2</sup>

The frequent association of these fluid-filled cavities with SS suggests that the associated dural defect may be the bleeding source. Friable vessels in the dural defect could be the source. Alternatively, as suggested by this patient with SS and CSF hypovolemia, the CSF RBCs may be due to exudation from engorged vessels. Awareness of this may obviate the need for angiography and focus therapy directed at identification and repair of the dural defect.

From the Departments of Neurology (N.K., A.M., A.A.R., J.E.A., B.M.) and Radiology (P.K.), Mayo Clinic, Rochester, MN.

Disclosure: The authors report no conflicts of interest.

Received January 19, 2007. Accepted in final form March 15, 2007.

Address correspondence and reprint requests to Dr. Neeraj Kumar, Department of Neurology, Mayo Clinic, 200 First Street SW, Rochester, MN 55905; kumar.neeraj@mayo.edu

Copyright © 2007 by AAN Enterprises, Inc.

## REFERENCES

1. Kumar N, A C-GA, Wright RA, Miller GM, Piepgras DG, Ahlskog JE. Superficial siderosis. *Neurology* 2006; 66:1144–1152.
2. Wilden JA, Kumar N, Murali HR, Lindell EP, Davis DH. Unusual neuroimaging in superficial siderosis. *Neurology* 2005;65:489.
3. Kumar N, Lindell EP, Wilden JA, Davis DH. Role of dynamic CT myelography in identifying the etiology of superficial siderosis. *Neurology* 2005;65:486–488.
4. Burk K, Skalej M, Dichgans J. High prevalence of CSF-containing cysts in superficial hemosiderosis of the central nervous system. *J Neurol* 2001;248:1005–1006.
5. Kumar N, Bledsoe JM, Davis DH. Intracranial fluid-filled collection and superficial siderosis. *J Neurol Neurosurg Psychiatry* 2007;78:652–653.
6. Mokri B. Low cerebrospinal fluid pressure syndromes. *Neurol Clin* 2004;22:55–74.
7. Burtis MT, Ulmer JL, Miller GA, Barboli AC, Koss SA, Brown WD. Intradural spinal vein enlargement in craniocervical hypotension. *AJNR Am J Neuroradiol* 2005; 26:34–38.

P. Mariën, PhD  
J. Verhoeven, PhD  
R. Brouns, MD  
L. De Witte, MA  
A. Dobbeleir, PhD  
P.P. De Deyn, MD,  
PhD

## APRAXIC AGRAPHIA FOLLOWING A RIGHT CEREBELLAR HEMORRHAGE

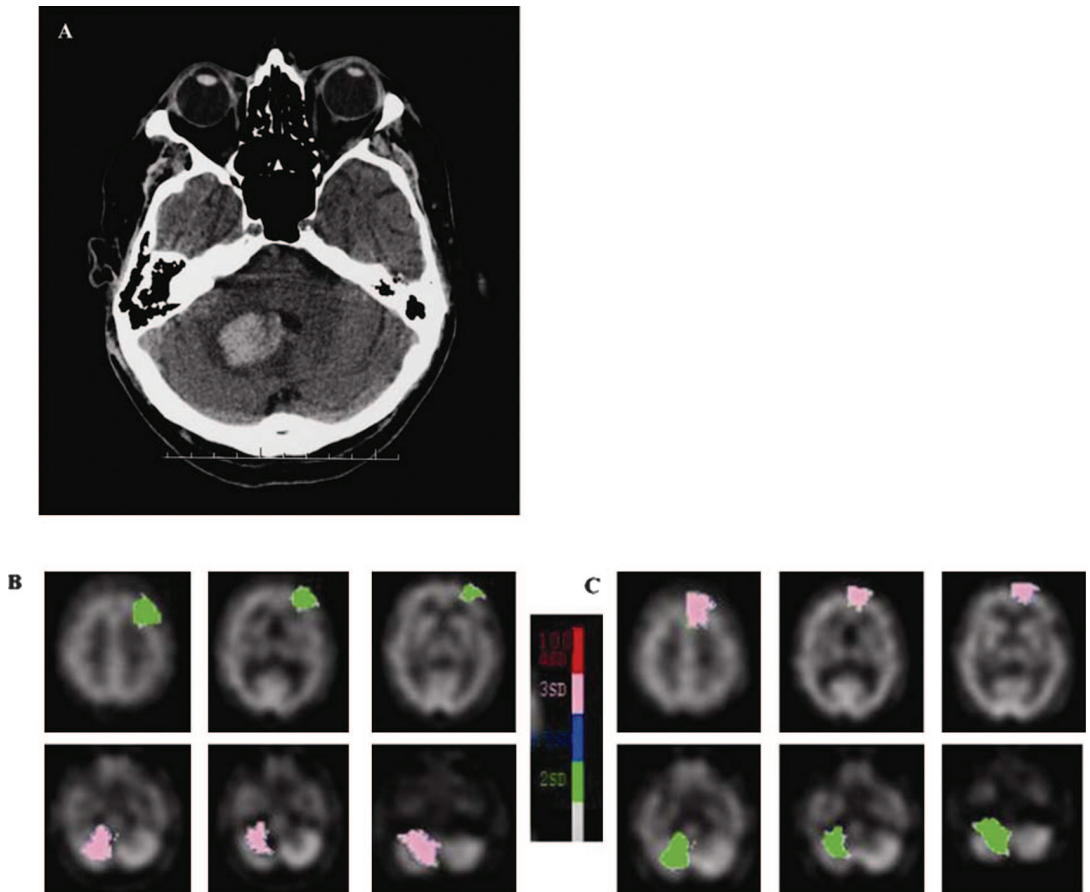
Apraxic agraphia follows disruption of skilled movement plans of writing and is characterized by distorted, hesitant, incomplete, and imprecise letter formation. The causative lesion is located in the superior parietal lobe (storage of graphomotor plans) or the dorsolateral and medial part of prefrontal

cortex (conversion of graphomotor plans to motor commands).<sup>1</sup> Recently, the condition was also reported after left dorsomedial thalamic infarction with reduced oxygen metabolism in left premotor areas.<sup>2</sup>

**Case report.** A 72-year-old right-handed engineer acutely developed postural instability and gait

CT scan of the brain disclosing a hemorrhage in the right cerebellar hemisphere involving cortex and the medullary core (A). Quantified Tc-99m-ethyl cysteinate dimer SPECT studies conducted 1 (B) and 6 months (C) after onset show a significant decrease of perfusion in the right cerebellar hemisphere associated with a hypoperfusion in the medial and lateral regions of the prefrontal left hemisphere (crossed cerebellocerebral diaschisis).

**Figure 1** CT scan and quantified Tc-99m-ethyl cysteinate dimer SPECT studies




disturbances. Neurologic examination showed a pure cerebellar deficit with distinct midline cerebellar dysfunction and less pronounced right appendicular ataxia. Apart from implantation of a pacemaker for sick sinus syndrome, his medical history was unremarkable. CT scan of the brain disclosed a hemorrhagic lesion in the right cerebellar hemisphere involving cortex and the medullary core (figure 1A). No supratentorial lesions were detected by repeat CT at 3 and 6 months after onset.

Neurocognitive functions were investigated 10 days and 3, 6, and 12 months after onset. Except for a dysexecutive disorder, no deficits were found. The ability to suppress a competing and more automatic response set (Stroop; <5th percentile) and frontal planning (Wisconsin Card Sorting Test; 0 categories in 128 trials) were severely disrupted. Mood and behavior were marked by persistent “prefrontal-like” disturbances such as lack of spontaneity, loss of initiative, flattened affect, and apathy. Although the patient was not depressed, he withdrew from his environment and avoided social contacts. Cognitive follow-up investigations did not reveal a progressive decline, and in agreement with family

report, no deterioration of cognitive and behavioral functioning was found after careful inquiry during follow-up.

Language assessments showed reduced spontaneous speech and deficient scores (>−2 SD) on the Token Test, auditory word comprehension test of the Aachen Aphasia Test (AAT), and visual confrontation naming tasks (AAT; Boston Naming Test). Agrammatism affected spontaneous speech. Articulation, repetition, oral reading, and reading comprehension were normal. Spontaneous and dictatorial writing of lowercase letters (0/15) and numbers (0/15) resulted in strings of illegible scrawls (figure 2A). Legibility only slightly improved when the patient wrote in uppercase letters (figure 2B). Quality did not improve when the patient wrote with the left hand. Mental spelling and typing of nonwords and words from different morphologic classes varying in length, imageability, and frequency were intact (Psycholinguistic Assessment of Language Processing in Aphasia). Reassessment of language functions 1 and 6 months after onset revealed remission of aphasic disturbances but apraxic symptoms persisted in writing (figure 2, C and D). To assess legibility, the patient copied a text from which 80 words were ex-

Handwriting sample illustrating the characteristic features of apraxic agraphia: writing of lower (A) and upper (B) case words to dictation at 1 month and copying of a premorbidly written sample (C) at 6 months after onset (D).



cised and randomly ordered into a list. Thirty-five students read and copied each word. The average incorrect recognition rate was 36.79% (SD = 8.16). For the same list of words written by an age- and education-matched control, an average incorrect recognition rate of 0.61% (SD = 0.7) was obtained.

Tc-99m-ethyl cysteinate dimer (ECD) SPECT perfusion scans were acquired 1 and 6 months after stroke. Transaxial images with a pixel size of 3.56 mm were anatomically standardized using SPM and compared with a standard normal and SD image obtained from 15 normal ECD perfusion studies. Using a 31-region-of-interest template, the Z-scores (SD) were then calculated for each region. A regional Z-score of >2.0 is considered significant. In comparison with normal database findings, the quantified baseline ECD SPECT studies at months 1 and 6 after onset showed a significant decrease of perfusion in the right cerebellar hemisphere (−3.91 and −2.02 SD) as well as a hypoperfusion in the medial and lateral regions of the prefrontal left hemisphere (−2.01 and −3.0 SD) (figure 1, B and C).

**Discussion.** After a right cerebellar hemorrhage, the patient presented apraxic agraphia, minor aphasia, dysexecutive symptoms, and behavioral and affective changes. The aphasia completely receded within the acute phase of hemorrhage, but apraxic agraphia, executive dysfunctions, and behavioral changes persisted during 1-year follow-up.

As in our patient, several studies have recorded disruption of language dynamics, semantics, and syntax after damage to the right cerebellar hemisphere, and the number of reports of patients with “frontal-like” affective and emotional disturbances due to cerebellar lesions is increasing.<sup>3,4</sup> Although functional neuroimaging studies have consistently shown involvement of the right cerebellar hemisphere in writing, neurobehavioral evidence extending the role of the cerebellum beyond the pure motor control level is scarce.<sup>5</sup> Patients have been reported with typical features of spatial agraphia (a peripheral writing disorder usually following nondominant hemisphere lesions) after cerebellar lesions, but descriptions of apraxic agraphia after cerebellar damage do not exist.<sup>6</sup> Given the perfusion deficits in the structurally unaffected left prefrontal cortex, our findings indicate that focal damage to the right cerebellar hemisphere may induce apraxic agraphia secondary to crossed cerebello-cerebral diaschisis.<sup>7</sup>

*From the Departments of Neurology (P.M., R.B., L.D.W., P.P.D.D.) and Nuclear Medicine (A.D.), ZNA Middelheim General Hospital, Antwerp; Laboratory of Neurochemistry and Behavior (P.M., R.B., P.P.D.D.), Institute Born-Bunge, University of Antwerp; Department of Linguistics (P.M.), Vrije Universiteit Brussel, Brussels, Belgium; and Department of Language and Communication Science (J.V.), City University, London, UK.*

*Supported by grant G.0209.05 of the Fund for Scientific Research–Flanders (F.W.O.–Vlaanderen), by Nationale Vereniging tot Steun aan Gehandicapte Personen (NVSG-ANAH) and Stichting Integratie Gehandicapten (SIG).*

*Disclosure: The authors report no conflicts of interest.*

*Received August 25, 2006. Accepted in final form March 22, 2007.*

*Address correspondence and reprint requests to Prof. Peter Mariën, Department of Neurology, ZNA Middelheim Hospital, Lindendreef 1, B-2020 Antwerp, Belgium; peter.marien@zna.be*

Copyright © 2007 by AAN Enterprises, Inc.

## ACKNOWLEDGMENT

The authors thank Prof. L.A. Vignolo for his helpful comments and advice.

## REFERENCES

1. Basso A, Taborelli A, Vignolo LA. Dissociated disorders of speaking and writing in aphasia. *JNNP* 1978;41:556–563.
2. Ohno T, Bando M, Nagura H, Ishii K, Yamanouchi H. Apraxic agraphia due to thalamic infarction. *Neurology* 2000;54:2336–2339.
3. Schmahmann JD, Sherman JC. The cerebellar cognitive affective syndrome. *Brain* 1998;121:561–579.



4. Mariën P, Engelborghs S, Fabbro F, De Deyn PP. The lateralized linguistic cerebellum: a review and a new hypothesis. *Brain Lang* 2001;79:580–600.
5. Katanoda K, Yoshikawa K, Sugishita M. A functional MRI study on the neural substrates for writing. *Hum Brain Mapp* 2001;13:34–42.
6. Silveri MC, Misciagna S, Leggio MG, Molinari M. Spatial dysgraphia and cerebellar lesion: a case report. *Neurology* 1997;48:1529–1532.
7. Broich K, Hartmann A, Biersack HJ, Horn R. Crossed cerebello-cerebral diaschisis in a patient with cerebellar infarction. *Neurosci Lett* 1987;83:7–12.

F. Fluri, MD  
 P. Lyrer, MD  
 A. Gratwohl, MD  
 A.E. Raetz-Bravo, MD  
 A.J. Steck, MD

### LEAD POISONING FROM THE BEAUTY CASE: NEUROLOGIC MANIFESTATIONS IN AN ELDERLY WOMAN

We report a patient with lead intoxication who had both acute encephalopathy and motor neuropathy. This case illustrates how difficult it can be to find the source of a lead intoxication because patients may not be aware of lead exposure.

**Case report.** A 68-year-old woman was admitted to our hospital in October 2003, with a 1-month history of fatigue, vomiting, and abdominal pain. Clinical examination revealed hypertension as a new finding but was otherwise normal. Blood test showed a macrocytic anemia and basophilic stippling of erythrocytes on blood smear. Vitamin B<sub>12</sub> level was 141 nmol/L (normal range [NR] 179 to 660). Erythropoietin level (30 IU/L [NR 12.0 to 23.0]) was lower than expected for a hemoglobin of 78 g/L [NR 120 to 160]). Bone marrow aspirate revealed increased dysplastic erythropoiesis. A differential diagnosis of myelodysplastic syndrome or reactive changes was made.

One month later, the patient was rehospitalized because of two tonic-clonic seizures. Neurologic examination was normal. Brain MRI showed hyperintense signal alterations of the basal ganglia (figure).

In January 2004, the patient complained about flaccid dysarthria and weakness in all four extremities, predominantly in the fingers. Neurologic examination revealed distal tetraparesis, diminished tendon reflexes, and fasciculations, whereas sensory deficits were minor. AST (51 U/L [NR 11 to 36]), ALT (56 U/L [NR 10 to 37]), and  $\gamma$ GT (64 U/L [NR 8 to 49]) were elevated. Creatinine, complete white blood cell count, and hemoglobin level were normal. Normal cytogenetics and in vitro growth of erythroid precursor cultures ruled out a myelodysplastic syndrome. Neuromyography demonstrated denervation in the bulbar and paravertebral muscles. Motor conduction was only slowed (37 to 39 m/sec) in both peroneal nerves. Muscle biopsy showed neurogenic muscle atrophy, but no signs of myopathy. Motor neuron disease was considered. The presence of basophilic stippling led us to suspect lead intoxication. Blood lead level was raised at 10.2  $\mu$ mol/L

(normal < 1.0), urine lead level at 637 nmol/L (normal < 310). Protoporphyrin in urine was 27,021 (normal < 1,068) nmol/L,  $\delta$ -aminolevulinic acid within the normal range. We sought intensively for the lead source, but without success.

Therapy with 250 mg dimercaptopropanesulfonic acid and 5% calcium EDTA daily was IV administered over 5 days. Blood lead levels fell to 3.9  $\mu$ mol/L; urinary lead level increased (4,247 nmol/L [normal < 310]). Tetraparesis improved and the patient was discharged.

In July 2004, the patient had bilateral radial palsy. Blood lead levels were elevated and the above mentioned therapy was reinitiated. Because of this re-intoxication, we carried out a home visit. In the bathroom, we found an ointment in her beauty case that the patient used on her lips when they were dry. Chemical analysis revealed a lead content of 13.4% (5.4 g) of this ointment. The patient administered this ointment regularly since March 2003.

**Discussion.** Intoxication with inorganic lead is preferentially associated with neuropathy, whereas organic lead seems to be more involved in the pathogenesis of encephalopathy. Painless motor neuropathy, often predominating in the wrist extensors, is seen at lead blood levels of >3.5  $\mu$ mol/L.<sup>1</sup> Pathophysiologically, lead intoxication probably leads to injury of the anterior horn cells or to damage of distal endings of the motor neurons which finally results in the observed degeneration of motor axons.<sup>1</sup> In patients with slight porphyrin increase, a mild sensory and autonomic neuropathy can be observed, whereas elevated levels of porphyrins are associated with a motor neuropathy.<sup>2</sup> Elevated porphyrin level and a motor neuropathy were also found in our patient. Lead intoxication may mimic the clinical features of a motor neuron disease and therefore can be misdiagnosed as amyotrophic lateral sclerosis. Basophilic stippling of erythrocytes may give a clue.

Encephalopathy is a rare complication of lead poisoning in adults and more common in children.<sup>1</sup> Features of acute encephalopathy are head-

# Neurology<sup>®</sup>

## APRAXIC AGRAPHIA FOLLOWING A RIGHT CEREBELLAR HEMORRHAGE

P. Mariën, J. Verhoeven, R. Brouns, et al.

*Neurology* 2007;69:926-929

DOI 10.1212/01.wnl.0000267845.05041.41

**This information is current as of August 27, 2007**

**Updated Information & Services**

including high resolution figures, can be found at:  
<http://www.neurology.org/content/69/9/926.full.html>

**References**

This article cites 7 articles, 4 of which you can access for free at:  
<http://www.neurology.org/content/69/9/926.full.html#ref-list-1>

**Permissions & Licensing**

Information about reproducing this article in parts (figures, tables) or in its entirety can be found online at:  
<http://www.neurology.org/misc/about.xhtml#permissions>

**Reprints**

Information about ordering reprints can be found online:  
<http://www.neurology.org/misc/addir.xhtml#reprintsus>

*Neurology*® is the official journal of the American Academy of Neurology. Published continuously since 1951, it is now a weekly with 48 issues per year. Copyright . All rights reserved. Print ISSN: 0028-3878. Online ISSN: 1526-632X.

