

References

- 1 Masson P. Hemangioendotheliome vegetant intravasculaire. *Bull Soc Anat* 1923;23:517-23
- 2 Rosai J, Ackerman LR. Intravascular atypical vascular proliferation. *Arch Dermatol* 1974;109:714-17
- 3 Romani P, Bradley NJ, Fletcher CDM. QBEND/10, a new monoclonal antibody to endothelium: assessment of its diagnostic utility in paraffin sections. *Histopathology* 1990;17:237-42
- 4 Kuo TT, Sayers P, Rosai J. Masson's 'vegetant intra-vascular hemangioendothelioma': a lesion often mistaken for angiosarcoma. *Cancer* 1976;38:1227-36
- 5 Henschen F. L'endovascularite proliferante thrombopoietique dans la lesion vasculaire locale. *Ann Anat Pathol* 1932;9:113-21
- 6 Kuo TT, Gomez LG. Papillary endothelial proliferation in cystic lymphangiomas. *Arch Pathol Lab Med* 1979;103:306-8
- 7 Lever WF, Schaumburg-Lever G. *Histopathology of the skin*. 6th edn. Philadelphia: JB Lippencott, 1983:643-4
- 8 Salyer RW, Salyer DC. Intravascular angiomatosis: development and distinction from angiosarcoma. *Cancer* 1975;36:995-1001

(Accepted 3 July 1991)

Infective endocarditis complicated by ruptured cerebral mycotic aneurysm

R L Patel FRCS¹ P Richards FRCS²
D J Chambers PhD¹ G Venn FRCS¹

¹Department of Cardiothoracic Surgery, St Thomas' Hospital, London and ²Department of Neurosurgery, Charing Cross Hospital, London

Keywords: infective endocarditis; mycotic aneurysm; cerebral aneurysm; cerebral haemorrhage

A 31-year-old man with infective endocarditis of the aortic and mitral valves underwent double valve replacement, following which he initially made an uneventful recovery. Fifteen days following surgery he developed a rapidly progressive left hemiparesis due to an intra-cerebral bleed from a ruptured mycotic aneurysm. He underwent emergency craniotomy with evacuation of intracerebral haematoma and made a complete recovery, both from neurological and cardiological point of view.

Case report

A 31-year-old man was admitted with a 4-month history of fever, night sweats, one stone weight loss, myalgia and arthritis. On examination he was pyrexial with a fever of 40°C, had splinter haemorrhages, finger clubbing, Janeway lesions, sub-conjunctival haemorrhages, splenomegaly and cardiac murmurs of aortic and mitral incompetence. A diagnosis of infective endocarditis was confirmed with the isolation of *Streptococcus viridans* in multiple blood cultures. Despite appropriate intravenous antibiotics, his fever persisted with progressive signs of cardiac decompensation necessitating emergency cardiac surgery. Both aortic and mitral valves were replaced with mechanical prostheses. He made an uneventful initial postoperative recovery with complete resolution of his pyrexia. Systemic antibiotic therapy continued in the postoperative period and anticoagulation was maintained within therapeutic range. On the twelfth postoperative day he developed recurrent fever, accompanied by rigors. Multiple blood cultures proved sterile and abruptly, on the third day of the return of fever, he developed a dense left hemiparesis, neck stiffness and left homonymous hemianopia.

CAT scan of the brain (Figure 1) revealed a large right posterior temporo-parietal haematoma. Right carotid angiogram demonstrated a distal middle cerebral mycotic

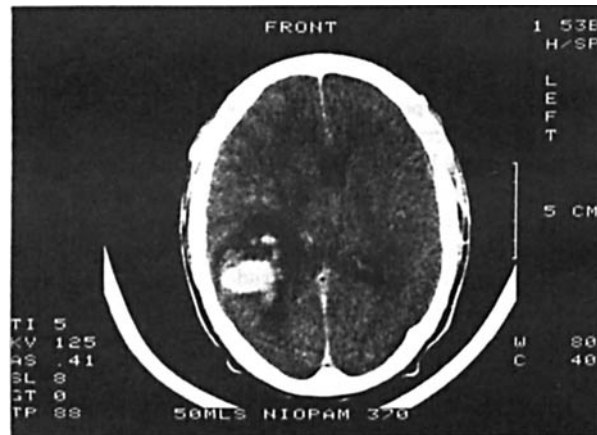


Figure 1. CAT scan of the brain showing large right posterior temporo-parietal intra-cerebral haematoma. There is surrounding oedema and shift of midline to the left

aneurysm as the source of the haematoma with two further small mycotic aneurysms related to the middle cerebral artery (Figure 2).

Despite full measures to reduce intracranial pressure, his right pupil began to dilate and an emergency craniotomy was performed. At operation a large, thick-walled, laminated haematoma was evacuated from the right parietal region. Culture of the haematoma proved sterile.

Following craniotomy he made a full neurological recovery. Six weeks after surgery four vessel cerebral angiography demonstrated complete resolution of the aneurysms demonstrated in the initial angiogram.

Discussion

Neurological sequelae are recognized as some of the most life threatening complications of infective endocarditis in both treated and untreated patients. The incidence of neurological complications of between 20% and 40% in patients with infective endocarditis has remained remarkably constant.

Mycotic aneurysms of cerebral arteries are present in 2-10% of patients with infective endocarditis and account for 2.5-6.2% of all intracranial lesions of this type¹. Those that rupture may destroy and obscure their presence during the massive haemorrhagic damage to the brain tissue that follows²⁻⁴ and carries a fatality rate of 80%². Cerebral embolization frequently precedes rupture of these mycotic aneurysms^{3,4}.

Mycotic aneurysms often begin to develop in the early stages of infective endocarditis but may not rupture until many weeks or months after apparent recovery^{5,6}. Many studies have documented, by serial angiography, the disappearance of cerebral mycotic aneurysms following successful antibiotic therapy^{4,7}.

Case presented
to Clinical
Section
12 April 1991

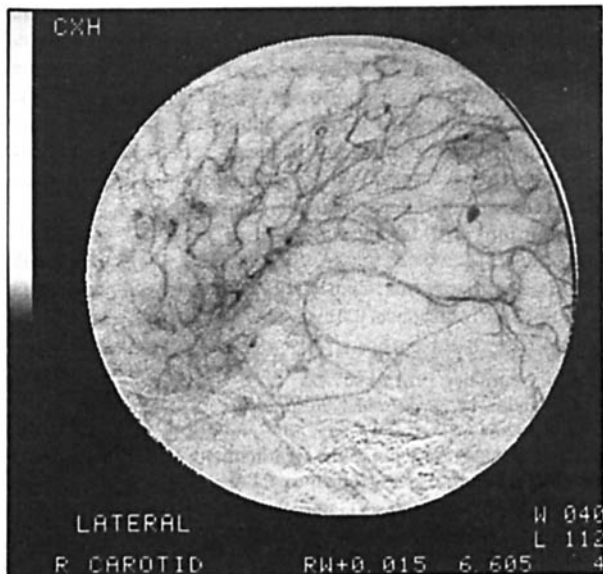


Figure 2. Right carotid cerebral angiography shows the large mycotic aneurysm in the distal branch of middle cerebral artery. The other two small aneurysms are not seen on this static picture

Those patients with infective endocarditis, who develop sterile meningitis and focal neurologic symptoms, should have prompt cerebral angiography^{1,8}. If an aneurysm is confirmed by angiography before rupture, urgent neurosurgical referral is indicated. Any peripheral aneurysm and its feeding vessels should be excised. Proximal and multiple aneurysms should be treated conservatively with serial

angiography and reserving surgery only for enlarging aneurysm. The friability of these aneurysms and their parent arteries makes surgery hazardous. As demonstrated by this case, prompt evacuation of a haematoma can lead to excellent recovery.

The dictum of Osler 'In hemiplegia in young adults or children, always think of subacute bacterial endocarditis' remains as valid today as in 1885⁹.

References

- 1 Pruitt AA, Rubin RH, Karchmer AW, Duncan GW. Neurologic complications of bacterial endocarditis. *Medicine* 1978;**57**:329-43
- 2 Bohmfalk GL, Story JL, Wissinger JP, Brown WE. Bacterial intracranial aneurysms. *J Neurosurg* 1978;**48**:369-82
- 3 Cantu RC, LeMay M, Wilkinson HA. The importance of repeated angiography in the treatment of mycotic embolic intracranial aneurysms. *J Neurosurg* 1966;**25**:189-93
- 4 Moskowitz MA, Rosenbaum AE, Tyler HY. Angiographically monitored resolution of cerebral mycotic aneurysms. *Neurology* 1974;**24**:1103-8
- 5 Lerner P. Neurologic complications of infective endocarditis. *Med Clin North Am* 1985;**69**:No.2
- 6 Bemford J, Hodges J, Warlow. Late rupture of a mycotic aneurysm after "cure", of bacterial endocarditis. *J Neurol* 1986;**233**:51-3
- 7 Suwanwela C, Suwanwela N, Charuchinda S, et al. Intracranial mycotic aneurysms of extravascular origin. *J Neurosurg* 1972;**36**:552-9
- 8 Ziment I, Johnson BL. Angiography in the management of intracranial mycotic aneurysms. *Arch Intern Med* 1968;**122**:349-52
- 9 Osler W. Gulstonian lectures on malignant endocarditis. *Lancet* 1885;**i**:415-8,459-64,505-8

(Accepted 24 July 1991)

Baclofen and carbamazepine in supraspinal spasticity

H Fodstad MD PhD B C A Ljunggren MD PhD
Division of Neurosurgery, Tawam Hospital, PO Box 15258, Al Ain, Abu Dhabi, United Arab Emirates

Keywords: baclofen; carbamazepine; brainstem seizures; spasticity

The anti-spastic drug baclofen exerts its therapeutic effect by acting as a GABA (gamma-aminobutyric acid) agonist at GABA-B receptors¹. The effect probably occurs through inhibition of release of the excitatory amino acid neurotransmitters glutamate and aspartate and/or is mediated through an increase in K⁺ fluxes in neurones. The end result is a suppression of both mono- and polysynaptic reflexes. Baclofen has a strong synergistic effect with carbamazepine. Two brainstem injured individuals with spastic quadriplegia were given baclofen and carbamazepine in combination with dramatic improvements.

Case reports

Case 1

A 31-year-old woman developed acute hydrocephalus due to aqueductal stenosis in October 1987. She received a ventriculo-peritoneal shunt which was removed the following year due to infection. During air transportation she suffered a brain herniation and arrived at a foreign hospital comatose and quadriplegic. The intracranial pressure was controlled with external drainage until a new shunt system was

inserted. In November 1988 the patient was transferred back to our institution. Upon re-admission she was totally unresponsive with a severe spastic quadriplegia including contractures of all four limbs and facial muscle spasm. CT brain showed central and cortical brain atrophy. She had two episodes of deep coma with increased general rigidity and shallow breathing (brain stem seizures?). Emergency tracheostomy was performed and the patient was rescued. Over the following months the patient's condition remained unchanged. Repeat CT examination did not show any interval change.

In July 1989 the patient was given oral baclofen (Lioresal) in increasing doses to 80 mg daily in addition to 600 mg carbamazepine (Tegretol) daily. Within 2 weeks her level of consciousness gradually started to improve and in parallel she started moving her contracted limbs. Within the next few months there was a dramatic resolution of her spasticity. She could finally be discharged home in January 1990. By then she had regained normal strength and function in all four limbs and was able to walk unassisted without any difficulty. Her mental functions had normalized and she could read, write and speak normally. Another CT brain in April 1990 did not show any interval change. From being a case of an autonomic survivor in a vegetative state with decerebrate rigidity she had become a functional individual with a fully acceptable life quality.

Case 2

A 21-year-old woman was involved in a road traffic accident in December 1989. Upon admission she was in deep coma (equal to sum Glasgow Coma Scale scores 3/15) and haemorrhagic shock. She had no palpable pulse and showed gasping respiration. An emergency laparotomy revealed rupture of liver and spleen with a mesenteric haematoma. The patient was transfused with more than 50 units of packed cells and other blood products. A CT brain in the acute stage did not disclose any major traumatic intracranial lesion. She was on continuous ventilatory support for 4

0141-0768/91/
120747-02/\$02.00/0
© 1991
The Royal
Society of
Medicine