

RIGHT-SIDED ANARCHIC (ALIEN) HAND: A LONGITUDINAL STUDY

SERGIO DELLA SALA,*† CLELIA MARCHETTI† and HANS SPINNLER‡

*Department of Clinical Neurophysiology, San Paolo Hospital, Milan; †Neuropsychology Unit, Clinica del Lavoro Foundation, Medical Centre of Rehabilitation, Veruno (NO); and ‡First Department of Neurology, University of Milan, San Paolo Hospital, Milan

(Received 29 January 1991; accepted 2 June 1991)

Abstract—A patient with a bilateral frontal vascular lesion, encroaching upon the mesial cortex on the left and damage of the *corpus callosum* showed the 'alien hand' phenomenon on the right.

The various hypotheses as to the nature of the lesion for the alien hand phenomenon to appear are discussed. It is proposed that an acute clinical condition, following a lesion of the *corpus callosum* only, should be differentiated from a chronic condition resulting from the additional fronto-mesial lesion.

INTRODUCTION

THE PHENOMENON called 'alien hand' (AH) consists of the occurrence of movements of an upper limb that are unintended although clearly directed to some purpose. The 'alien' hand, seems to act autonomously, carrying out complex movements against the subject's verbally reported will, that can interfere with the development of an intentional action that the other hand has begun. The subject is fully aware of the abnormal behaviour of one hand but he is not able to inhibit it. This is both unpleasant and frightening for him.

Doubts abound as to the crucial site of the lesion and how large it has to be for AH to appear.

Interpretations based on callosal lesion only

All the reported cases of AH that have developed after only a callosal interruption show the phenomenon on the left side [1, 9, 54]. This was interpreted as the result of the disconnection of the area devoted to complex motor activities in the left hemisphere [17, 30, 31] from the area on the right in which the motor cortex for the left hand is located. This would exclude right-handed subjects from having AH on the right. In support of this interpretation there are some patients reported with left AH whose neuro-radiological examination failed to show any additional involvement of the cortical areas [26, 51].

Interpretations based on a requirement of a double, callosal and cortical, lesion

After GOLDBERG [21] described two patients with AH on the right side, the explanation involving the *corpus callosum* (CC) only, appeared inadequate and it was proposed that a

‡Address for correspondence: Hans Spinnler, Clinica Neurologica I, Polo Didattico S. Paolo, Università degli Studi, Ospedale San Paolo alla Barona, Via A. Stanabba di Rudini 8, 20142 Milano.

double lesion, namely, both of the CC and of the fronto-mesial cortex (precisely, of the Supplementary Motor Area, SMA) contralateral to the AH meets the essential pathological requirement of AH.

Since this condition seldom occurs, it is worth describing each case, as this may contribute to a clearer definition and interpretation of AH and will possibly enable us to develop a metanalysis. We describe a 3-year follow-up of a right-handed patient with callosal and bilateral frontal vascular lesion presenting with a stable right AH.

CASE REPORT

G.C. is a 56-year-old right-handed woman who first came to us in January 1988. A year before she suffered a subarachnoid haemorrhage and was operated on 2 days later to clip two aneurisms of the anterior communicating artery. After she roused from a 20-day coma, the patient had language disorders and right hemiplegia.

The language disorders (comprehension well-preserved, spontaneous speech nearly nonexistent, repetition possible and correct) was compatible with a transcortical motor aphasia syndrome. The disorder cleared up within a few months. The motor deficit also improved and was all but gone when we first saw her.

In the first months after the operation her behavioural characteristics fitted both an adynamic (abulic–apathetic–akinetic) and moriatic ('Witzelsucht') syndrome. Both of these features subsided with time and when we began to study G.C. only slight stable abulia remained. She was forgetful in everyday life with a clear-cut deficit of ongoing memory.

As the motor symptoms cleared up, severe disturbances of organization of voluntary gestures and of bimanual coordination became apparent. The right hand frequently carried out complex activities that were not willed by G.C. These activities were clearly goal-directed and were well executed, but undesired by the patient, who used her left hand to try to stop them. For example, when the patient had a steaming cup of tea in front of her, the right hand proceeded to pick it up and bring it to her mouth, even though the patient knew that it was too hot and had just said she would wait a few moments until it had cooled. Nevertheless it needed the intervention of her left hand to replace the cup on the table. The will to do so was not sufficient to modify the directed but inappropriate behaviour of the right hand. On other occasions, when G.C. had a genital itch, the right hand scratched it vigorously, in view of other people, causing considerable embarrassment to the patient, who tried to stop the right hand with her left. These are only two examples of many such manifestations of impulsive, context-dependent autonomous behaviour of the right hand. At other times, the right hand interfered with intentional movements of the left hand, carrying out complex and organized activities that did not appear to be so closely context-dependent. For example, while the left hand was using some object, the right hand would try to grab it and use it, against the will of the patient, in some way different from the original plan. The patient considered her left hand to be the one she could trust, while the right hand, which could make motions completely without her wanting it to, was the untrustworthy one that 'always does what it wants to do'. The patient often experienced this problem with the right hand during her daily activities and in order to complete the activity she wanted to complete, she had to prevent the 'wayward' right hand from interfering, sometimes by force (by hitting it or by sitting on it). The need to take these precautions, which had only fleeting effects, and the frequent failures produced a marked feeling of frustration. In spite of the inconveniences caused by this motor behaviour of the right hand, G.C. never denied (even in response to direct questioning) that this 'alien' hand belonged to her (i.e. she had no sign of asomatognosia). She never had a depressed or anxious reaction, but was rather annoyed by her symptoms. She was well aware of the problem and that the disturbance consisted exclusively of the right-hand functioning autonomously against her will.

Neurological examination

The neurological examination in January 1988 (i.e. a year after the rupture of the aneurism) showed slight paresis of the right limbs, which could still carry out all the movements. Movements for reaching or picking up objects placed in the peri-personal space were normal. Two-handed tasks, even relatively complex ones (e.g. making a package, folding a letter and placing it in an envelope), were done correctly and with good coordination of the two hands. Sensation was normal in all modalities. The right hand showed tonic grasping; there were no other cortical disinhibition signs or perseveration of motor acts.

Neuroradiology

The CT scan carried out in May 1987, showed a bilateral fronto-basal paramedian hypodensity, involving the anterior part of the CC and extending more to the left so as to presumably encroach upon the supplementary motor area of that side (Fig. 1). This could not be confirmed by Nuclear Magnetic Resonance because of the metal clips in the patient's head.

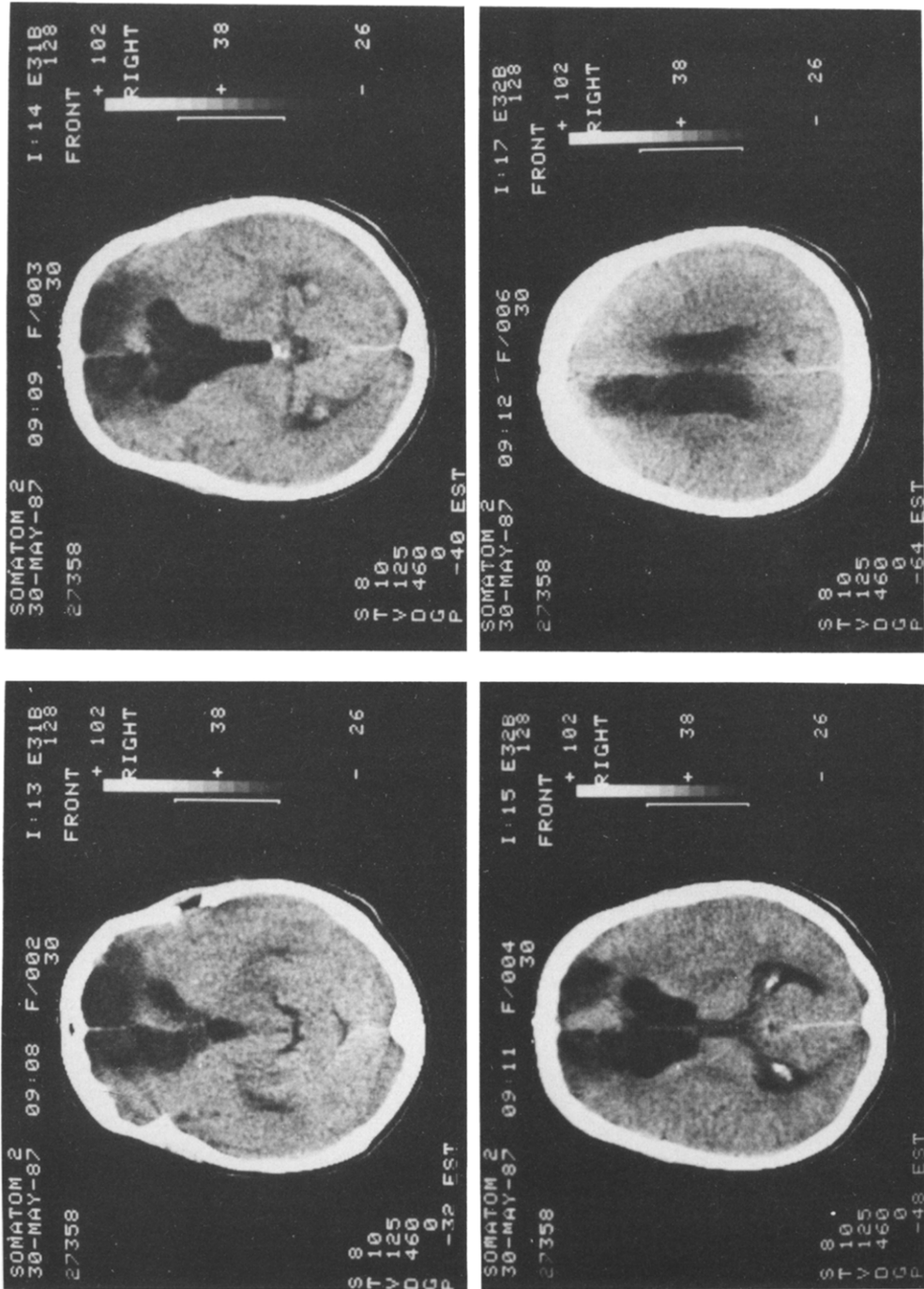


Fig. 1. CT carried out 4 months after the subarachnoid haemorrhage. The horizontal section shows the lesion of the corpus callosum and of the frontal lobes. On the left, the frontal involvement includes the mesial region.

Neuropsychological examination

A standard language examination, the Aachen Aphasia Test [14, 33] (January 1988), showed no aphasic deficit. Writing with the right hand was normal. Neither writing nor drawing evidenced perseveration.

The neuropsychological examination (see Table 1, first session) excluded global cognitive deterioration. There were memory deficits that did not fit into any classical amnesia syndrome, involving both short-term and long-term spatial and verbal memory. Autobiographical memory was also impaired; G.C. did not produce, however, confabulations. The patient scored below the cut-offs in some tests (Weigl Sorting Test, Elithorn Perceptual Maze) [15, 53] that are traditionally considered to be sensitive indices of frontal damage [48].

The alien hand

The audio-videotape of the test sessions was evaluated by two independent observers.

During some of the neuropsychological tests which required manipulation or utilization of objects, a conflict between the two hands became evident, with each of them acting according to separate and often competing programmes. The patient always felt that the right hand was a disturbing element, even when it carried out an activity more adequately than the left. The feeling that the movements of the right hand were disturbing appeared to arise from the fact that the patient consciously willed (as was clear from her spoken descriptions) only what the left hand was doing, while what the right hand was doing was always unexpected. The activities of the right hand did not lessen when the arm was moved over the midline to the left hemisphere, as they did in patient B.D. described by GOLDBERG [23], suggesting that our case did not have 'hemispatial motor neglect' [37].

There were many 'callosal phenomena'; they are listed in Table 2. Whenever possible, we used the terminology of BOGEN [9].

(1) Aphasic errors when writing with the left hand in response to dictation (aphasic agraphia of the left hand) (Fig. 2). The patient herself was aware of these errors and was surprised by them, but could not correct them with the left hand.

(2) Errors of naming objects placed in the left hand and manipulated without visual control (tactile anomia of the left hand): a pen was called a knife, a key was called a spoon, a band was called a tennis racket, a fork a spoon, a ring a lid. The objects were manipulated correctly and they were recognized, though not named, when later presented mixed with new objects. Objects were named correctly when manipulated by the right hand.

(3) Verbal orders executed by the left hand were defective (apraxia of the left hand) both when G.C. was asked to mime the action without using the real object and when she was asked to carry out gesture without significance or meaningful gestures (e.g. make the sign of the cross, give a military salute, etc.).

(4) Relatively simple arithmetic calculations, which could sometimes be performed successfully vocally, were frequently erroneous when written (spatial dyscalculia).

(5) A geometrical figure was copied correctly by both hands, but the proportions and dimensions were closer to those of the original in the copy made with the left hand.

(6) Transfer of kinesthetic information from one arm to the other outside the visual control (for example, arm extended with the forearm flexed and the closed fist placed on the homolateral shoulder) was virtually impossible for both the left and right side (9 failures in 10 proposals, whether from right to left or left to right).

Follow-up

G.C.'s AH stabilized over time, which constituted a chronic right AH. The patient herself said that it appeared within 2 months after her recovery from postoperative coma and we observed it for the first time 1 year later. The sign had not changed at an examination 2 years later.

TABLE 1. G.C.'s performance in a formal psychometric battery and healthy baselines. All scores have been adjusted for age, education and sex. Range in brackets. The tests utilized are described in SPINLER and TOGNONI [47] except for the test for prose memory [5], the test of autobiographical memory [10] and the test of the Towers of Hanoi [2]

| | G.C.'s adjusted scores (1st session) | G.C.'s adjusted scores (2nd session, interval = 29 months) | Controls' inferential 5th centile | Controls' median score |
|---|---|---|---|---------------------------|
| <i>Control functions</i> | | | | |
| Attention | 30* | 41.5 | 30 | 49 |
| Selective attention: | | | | |
| Digit cancellation test (0-60) | | | | |
| Inverted copying of gestures (0-24) | 24 | 17.25 | 18.25 | 23.25 |
| <i>Intelligence and executive functions</i> | | | | |
| Verbal judgement (0-60) | 43.25 | 58.25 | 32 | 50 |
| Raven's progressive matrices set A, B, C, D (0-48) | 16.75 | 20.75 | 14.75 | 28.75 |
| Weigl's sorting test (0-15) | 2* | 4* | 4.25 | 10.75 |
| Elithorn's perceptual maze test | 0* | 4.75* | 7.25 | 14.25 |
| Towers of Hanoi test (0-18.80) | 17.86 | 18.02 | 9 | 18 |
| Fluency on semantic cue (0-inf) | 9.75 | 12.25 | 7 | 17 |
| Free word association (0-inf) | 4.25 | 7.75 | 3.75 | 9.50 |
| <i>Instrumental functions</i> | | | | |
| <i>Memory</i> | | | | |
| Verbal forward span (0-inf) | 2.50* | 3.5 | 2.75 | 4.50 |
| Spatial forward span (0-10) | 3* | 5 | 3.50 | 4.75 |
| Supra-span verbal learning | 8* | 40 | 36 | 111 |
| Buschke-Fuld's selective reminding technique (0-180) | | | | |
| Supra-span spatial learning (Corsi's test) (0-29.16) | 5.25* | 9.07 | 6.50 | 20 |
| <i>Serial position curve</i> | | | | |
| Primacy (0-70) | 12 | 7 | 4.50 | 15.50 |
| Recency (0-30) | 11.50 | 16.50 | 7.50 | 18.50 |
| Prose memory (0-150) | 3* | 6* | 24 | 60 |
| Autobiographical memory (0-45) | 14* | — | 19 | 38 |
| <i>Language</i> | | | | |
| Token test (0-36) | 26.75 | 32.25 | 26.25 | 33 |
| Sentence generation from two unrelated nouns (0-18) | 14 | 14 | 6.25 | 13.75 |
| <i>Praxis</i> | | | | |
| <i>Ideomotor apraxia</i> | | | | |
| Right hand (0-72) | 62 | 62 | 52 | 69 |
| Left hand (0-72) | 52* | 56 | 52 | 69 |
| <i>Visual perception</i> | | | | |
| Length of segment discrimination (0-32) | 21 | 26 | 17 | 26 |
| Scrawls discrimination (0-32) | 23 | 19 | 20.75 | 31.25 |
| Street's completion test (0-14) | 7.50 | 8.5 | 2 | 7.25 |

*Pathological score, i.e. below the 5th centile of the normal distribution.

TABLE 2. G.C.'s performance in tasks devised to show a callosal syndrome

| Agraphia | Right hand No | Left hand Yes |
|--|------------------|------------------|
| Tactile anomia | 10/10 | 5/10 |
| Ideomotor apraxia in response to verbal command: | | |
| Pretend object utilization | 9/10 | 0/10 |
| Intransive movements | 9.5/10 | 7/10 |
| Meaningful gestures | 10/10 | 4.5/10 |
| Constructional apraxia | 14/14 | 14/14 |
| Spatial acalculia | | Yes |
| Cross-replication of arm and hand postures out of visual control | 1/10 | 1/10 |

The patient was not able to find strategies that would avoid or stop the conflict between the two hands, which could be resolved only temporarily by using force. Even the suggestion [21, 23] that she should 'talk to the hand' did not prove effective.

Three years after the subarachnoid hemorrhage, all the signs of callosal disconnection that we have described were still present. The ideomotor apraxia on imitation [15], of the left hand, seen in the first examination, had improved noticeably (Table 1). The cognitive profile showed marked improvement in memory function and partial improvement in the so-called frontal tests (Table 1). However, there was still everyday evidence of disturbances of ongoing memory and her behaviour varied between inertia and facetiousness.

DISCUSSION

The anarchic hand

Our patient with chronic right-sided AH had an extensive lesion of the *corpus callosum* (CC) and the fronto-mesial cortex on both sides. It is reasonable to think that the supplementary motor area (SMA) was more likely to be compromised on the left, given the larger mesial lesion on that side. The activities of the right hand were considered by the patient to be unwanted, and this feeling did not change with time. The autonomous movements were correct from the praxic viewpoint, they were neither aimless nor ataxic, not identifiable as dyskinesias. The patient disavowed the movements carried out by the right hand even when they fit the requirements of the tasks carried out. This behaviour cannot be interpreted as the consequence of hemispheric cognitive incompetence for some responses of the right hand, as was considered to be the case for LORING *et al.*'s case J.M. [32].

G.C. never considered that the AH that she could not control was not really hers; in fact, as in most cases in the literature, she always recognized the arm as hers. We agree with GOLDBERG [23] that the term 'alien hand' is less appropriate than the term 'wayward hand' or, in view of the complete autonomy of the arm and its disruptive effect on the daily activities of patients who have one, perhaps the best would be 'anarchic hand'.

The interpretation of AH is made complicated even by linguistic misunderstanding. This same term has been used to describe phenomena that have little in common. BOGEN [9], for example, defined AH as a hand that 'behaves in a way which the patient finds foreign or at least uncooperative' (p. 313) and, with almost imperceptible shades of meaning, differentiates this from 'intermanual conflict' (p. 312), defined as a situation in which one hand 'is acting at cross purposes to the other', sometimes to the point of engaging in a real struggle

| STIMULI | GC'S WRITTEN RESPONSES (RIGHT HAND) | GC'S READING OF RIGHT HAND RESPONSES | GC'S WRITTEN RESPONSES (LEFT HAND) | GC'S READING OF LEFT HAND RESPONSES |
|-------------------------|--|---|---------------------------------------|--|
| LAMPADA (lamp) | - lampada | LAMPADA | - beresimta | BERESIMTA |
| ELICOTTERO (helicopter) | - elicottero | ELICOTTERO | - elisince | ELISINACE |
| ZANZARA (mosquito) | - zanzara | ZANZARA | - zinesim | ZINESISM |
| COLLANA (necklace) | - collana | COLLANA | - custina | CUSTINA |
| MINESTRA (soup) | - minestra | MINESTRA | - misistrina | MISISTRINA |
| FARFALLA (butterfly) | - farfalle | FARFALLA | - fustrella | FUSTRELLA |
| FORBICI (scissors) | - forbici | FORBICI | - fusciniata | FUSCININTA |
| ASCIUGAMANO (towel) | - asciugamano | ASCIUGAMANO | - tusciuspa | TUSCIUSPA |
| FIDANZATO (fiancee) | - fidanzato | FIDANZATO | - finscotu | FINSCOTU |
| PENTOLA (pot) | - pentola | PENTOLA | - matsula | MATSULA |

FIG. 2. Some examples of words written by G.C. with the left hand. In addition to the reasonable clumsiness due to lack of experience in writing with the nondominant hand, there are many obvious paraphasias. It is noteworthy that all resulting responses are non-words. The patient correctly read what she had wrongly written, but was not able to correct it graphically, with the left hand.

with the other, and from 'autocriticism', which consists of an 'expression of astonishment' (p. 313) by the patient who sees that one hand appears to be provided with its own autonomous volition and refers to it as it is not driven by his will: 'the hand did such and such'.

In reviewing previous reports, it turns out that the above-mentioned terms are often used interchangeably for very different situations: spontaneous and involuntary grasping by one hand of everything near it (with a need for the other hand to intervene to stop it from taking up things that the subject does not want) [24, 35], intervention of one hand to correct activities that are or are considered to be wrong [32], the experience of the impossibility of exerting voluntary control of uncoordinated movements by one hand in the case of optic

ataxia [29] or even the involuntary movements of one hand during the course of corticobasal degeneration [20, 40, 41].

Usually these phenomena are described within variegated picture of acute interhemispheric disconnection symptoms and they are usually related to the '*Main Etrangère*' of BRION and JEDYNAK [11] or to the 'Diagnostic Dyspraxia' of AKELAITIS [1]. However, there are obvious differences. The *main étrangère* described by BRION and JEDYNAK [11] consisted of a lack of recognition by the subject of his or her left hand when asked to touch it with the right hand without visual control. That is, the patients recognized one hand, but were not aware that they were dealing with their own left hand, in a kind of hemisomatoagnosia limited to the hand and to the tactile modality only. No movements that were not voluntary and not controlled by the subject were included in this picture. The 'Diagnostic Dyspraxia' of AKELAITIS [1] consisted, instead, of a fleeting appearance, during the short period immediately following a callosotomy, of motor activity that contradicted what the subject wanted to do. This phenomenon appeared in the patient as a strong conflict between the two hands, with the left hand systematically undoing what the right hand had just finished doing.

Anatomo-functional correlating hypothesis of AH

Table 3 summarizes the information about many of the patients with AH described in the literature. It also includes cases for whom it is not possible to speak of AH in the strict sense, but who had one or more of the phenomena associated with it. There is an extensive Japanese literature that has not been mentioned on the table; the reader is referred to a recent paper by TANAKA *et al.* [49].

We considered it useful to include the largest amount of clinical information for each patient in this table. Attribution of a given symptom to a patient was based on the description of the authors rather than on what they named the symptom. When the authors did not include enough information to make this possible (e.g. CHAN *et al.* [12]), we used the term the authors had used. We used the above-mentioned definitions of BOGEN [9] for AH, intermanual conflict and autocriticism. By 'mirror movements' we mean situations in which both arms cannot carry out different and complementary activities harmoniously, but are bound to mirror each other. The 'callosal signs' are those commonly reported for the syndrome of interhemispheric disconnection (see BOGEN, 1979 [9]). In detail, for the patients considered in Table 3 they were: tactile anomia of the left hand [8, 11, 24, 26, 28, 36, 49–51], apraxia of the left hand [8, 12, 24, 26, 36, 51], agraphia of the left hand [8, 11, 12, 26, 28, 36, 51], right constructive apraxia [11, 25, 28, 51], left relative pseudo-hemianopsia [11], lack of ability in cross-replicating hand postures [11, 12, 28], extinction in dichotic hearing of stimuli presented to the left ear [25], spatial discalculia [28] and anomia for objects presented in the left visual field [4]. The patient described by SHAHANI [45] is not set forth in Table 3 inasmuch as he did not present with clear-cut alien behaviour. This is at odds with the frequent report of this case [21] among the 'alien' references.

Analysing the data in Table 3, it is possible to formulate some localizing hypotheses from the literature on AH, hypotheses already mentioned in the Introduction.

(1) The hypothesis that a circumscribed lesion of the CC is sufficient is based essentially on the fact that the earliest descriptions of AH were made after surgical callosotomy and the phenomenon was found along with signs of acute interhemispheric disconnection [1, 9, 54]. This hypothesis seemed to have been confirmed by some cases with vascular lesions [6, 28, 51] which did not have cortical lesions that could be detected by neuroradiological methods.

Cases with left AH fit within a theoretical explanation, stemming from the apraxia domain,

TABLE 3. Lay-out of findings reported in 35 patients presenting 'alien hand' and/or *main étrangère*, intermanual

| Author | Number of patients | Lesion | Preferred hand | Grasp reflex | Spontaneous grasping | Mirror movements | Callosal signs |
|---|--------------------|---|----------------|--------------|----------------------|------------------|-----------------------|
| AKELAITIS, 1944 [1] | 1 | Surgical division of body and posterior half of genu of the CC | | | | | |
| BRION & JEDINAK, 1972 [11] | 1 | Callosal tumor | | | | | + |
| | 2 | Callosal tumors | | | | | + |
| | 1 | Left pericallosal angioma | | | | | + |
| WILSON <i>et al.</i> , 1977 [54] | 1 | Surgical division of the CC | | - | | | + |
| BARBIZET <i>et al.</i> , 1978 [4] | 1 | Clinical diagnosis of Marchiafava Bignami disease | | | | | + |
| BEUKELMAN <i>et al.</i> , 1980 [8] | 1 | CT: diminished density between the anterior horns of the lateral ventricles | | | | | + |
| GOLDBERG <i>et al.</i> , 1981 [21] | 1 | CT: left fronto-mesial cortex infarction | R | + | (R) | + | (R) |
| | 1 | CT: left fronto-mesial cortex infarction | R | + | (R) | + | (R) |
| WATSON & HEILMAN 1963 [51] | 1 | CT: hemorrhage extending from the genu to the splenium of the CC. Coronal reconstructions showed this to extend above the CC | R | - | - | + | + |
| GOLDENBERG <i>et al.</i> , 1985 [24] | 1 | CT: infarction of the anterior two thirds of the CC, of both cingulate gyri and the white matter underlying the upper and mesial parts of frontal lobes | R | + | (BIL) | + | (L) |
| WATSON <i>et al.</i> , 1986 [52] | 1 | CT: low density of the left mesial hemisphere and genu and anterior body of the CC | R | + | (R) | + | (R) |
| | 1 | CT: low density in the distribution of the left anterior cerebral artery not involving the CC | R | + | (R) | | |
| LEVINE & RINN, 1986 [29] | 1 | CT: large right basal temporo-occipital and small ventral postero-lateral thalamic infarcts | R | | | | |
| GOLDBERG, 1987 [23] | 1 | CT, NMR: extensive infarction of the mesial surface of the right frontal lobe and of the body of the CC | R | + | (L) | + | (L) |
| GRAFF-RADFORD <i>et al.</i> , 1987 [26] | 1 | NMR: hemorrhage in the genu and most of the body of the CC; no evidence of infarction in the SMA | R | | | | + |
| MAGNANI <i>et al.</i> , 1987 [35] | 1 | CT: reduced density in the mesial face of the left hemisphere, two thirds of the anterior portion of the CC and part of the parietal lobe | | + | (R) | + | (R) |
| | 1 | CT: recent ischemic lesion of the white matter in the left fronto-mesial region; a previous lesion in the left caudate nucleus and cortical atrophy | | + | (BIL) | + | (BIL) |
| McNABB <i>et al.</i> , 1988 [36] | 1 | CT: extensive infarction of the left superior, fronto-mesial and parietal cortex and of the genu and body of CC | R | + | (R) | + | (R) |
| | 1 | No information | R | | | | Coordination problems |
| | 1 | No information | R | + | (R) | + | (R) |
| | 1 | No information | R | + | (R) | + | (R) |
| CHAN & ROSS, 1988 [12] | 1 | CT: ischemic infarction involving right anterior cingulate gyrus and SMA. CC only minimally involved | R | - | - | | |
| | 3 | CT: infarction on the left SMA, anterior cingulate gyrus and anterior CC | R | + | (R) | | + |
| | 1 | CT: infarction in the right SMA, anterior cingulate gyrus and anterior CC | R | + | (L) | | + |
| | 1 | CT: infarction in the right SMA, anterior cingulate gyrus and anterior CC | R | + | (L) | | + |
| BANKS <i>et al.</i> , 1989 [3] | 1 | Autopsy: bilateral frontal damage (> on the right side) and callosal damage; additional damage on the right basal ganglia and thalamus | R | | + | (L) | + |
| | 1 | CT: hemorrhage in the fronto-mesial lobes bilaterally; damage to the genu and anterior portion of the CC | R | | | | |
| LEIGUARDA <i>et al.</i> , 1989 [28] | 1 | CT: hemorrhage involving the CC from the dorso-rostral position of the genu to the most caudal part of the body | R | + | (R) | | + |
| | 1 | CT: hemorrhage extending from the dorsal part of the genu to the caudal third of the CC | A | + | (BIL) | | + |
| | 1 | CT: extensive hemorrhage from the rostral part of the genu to the dorsal splenium of the CC | R | + | (R) | + | (L) |
| LORING <i>et al.</i> , 1989 [32] | 1 | Surgical section of the CC | R | | | | + |
| | 1 | NMR: division of the CC, no additional lesion | | | | | |
| TANAKA <i>et al.</i> , 1990 [49, 50] | 1 | NMR: small ischemic stroke of the anterior two-thirds of the CC of the cingulate gyrus and of the mesial superior frontal gyrus of both hemispheres (SMAs claimed to be spared) | R | - | - | + | +(?) |
| DELLA SALA <i>et al.</i> , 1991 | 1 | CT: bilateral frontal infarction involving the CC. On the left side, lesion extending to SMA | R | + | (R) | - | + |

+ : Sign present; - : sign absent; +? : questionable sign presence; (R): right-sided; (L): left-sided; (BIL): bilaterally sided; A: ambidextrous; (R)*: the right hand also occasionally showed alien behaviour.

conflict and autocriticism. When information is missing, corresponding space is left blank

| Alien hand | First assessment | Last assessment | Lesion/referral interval | Intermanual conflict | Autocriticism | Main étrangère | Motor perseverations | Transcortical motor aphasia | Miscellaneous data |
|------------|------------------|-----------------|--------------------------|----------------------|---------------|----------------|----------------------|-----------------------------|--|
| | | | | + | | | | | Left hemiparesis and sensory changes: slurring of speech. Schizoid pattern on Rorschach test. Sometimes she would set off in one direction but then she would find herself going in the opposite direction |
| | | | | | + (L) | | | | |
| | | | | | + (L) | | | | |
| | | | | | + (L) | | | | |
| | | | | + | | | | | |
| | | | | (fleeting) | | | | | + (fleeting) Angiography and cerebral CT normal |
| + (L) | | | | + | | | | | |
| | | | | + | | | | | Activities of the left extremities were not improved by verbal cueing |
| + (R) | 21 days: + | 35 days: - | | + | | | + (R) | + | Right arm paresis, right leg paralysis |
| + (R) | 21 days: + | | | | + | | + (R) | + | |
| + (L) | 3 days: + | 44 days: + | | + | | | - | + | Bilateral weakness of legs, the right being weaker than the left |
| + (L) | 180 days: + | | | + | | | | + | Bilateral leg paresis; double incontinence |
| | + (R) | 40 days: + | 90 days: - | | | | | + | Increased reflexes of the right leg and right extensor plantar response |
| | | | | | | | | + | Right leg weakness |
| | | | | | + (L) | | | | |
| + (L) | | | | | | | | - | Ataxic left hand: visual control did not improve performance. Left hemianopia, left spatial neglect; left sensory loss. The patient first thought of the left hand as naughty, then conceived it as a baby |
| + (L) | | | | | | | | | The patient felt as if her left leg did not belong to her. Left leg weakness and 'inconsistent' ability to move the left arm |
| + (R) | | | | | | | | Mutism for 4 weeks | |
| + (R) | | | | + | | | + (R) | + | Right leg weakness, right extensor plantar response |
| | | | | + | | | | + | Patient mutacic, as in a state of catatonia with improvement of vigilance, could repeat words and phrases |
| + (R) | 42 days: + | | | + | | | + (L) | + | Right arm paresis, right leg paralysis |
| + (R) | | | | + ? | | | + (BIL) | Hesitation | Right leg weakness. In bimanual task, the two hands appeared to act quite independently of each other |
| + (R) | | | | + ? | | | | + | Right leg weakness |
| + (L) | | | | | | | | + | Left leg paralysis, left extensor plantar response. Tendency to make fewer movements with the left hand |
| + (L) | | | | | | | | + | |
| + (L) | | | | | | | | + | Paresis more severe in the leg contralateral to the site of the lesion |
| - | | | | | | | | + | |
| + (L) | | 13 years: - | | + | | | + (L) | - | |
| + (L) | | | | | | | + (L) | + | Abulic. Left alien foot. Bilateral plantar extensor response |
| + (L) | | | | + | | | | + | Bilateral leg weakness, left extensor plantar response |
| - | | | | | | | | + | Left crural hyperreflexia, left extensor plantar response |
| + (L) (R)* | 15 days: + | | | + | + | | | + | Left crural hyperreflexia, left extensor plantar response |
| | | | | | + | | | | Intermanual competition: the right hand corrected written verbal errors made by the left hand, and vice versa |
| + (L) | 3 months: + | 7 months: - | | + | | | | + | Left hand apraxia |
| | | | | | | | | | Right hand dysgraphia |
| | | | | | | | | | Extinction of the right ear on dichotic listening |
| + (R) | 1 year: + | 3 years: + | | + | - | - | + | | |

of a disconnection between the areas of programming on the left and those on the right for carrying out movements with the left hand. However, this does not apply to right AH of right-handed people.

All patients with right AH have been found to have lesions that extend beyond the CC. In Table 3 there is only one partial exception to this: LEIGUARDA *et al.*'s [28] patient No. 3 had a right hand that occasionally behaved like the left AH.

(2) The hypothesis of a double, contemporaneous lesion of the CC and of the fronto-mesial cortex of the hemisphere contralateral to the AH was proposed after the first description [21] of two patients with right AH. This hypothesis states that AH is the result of an imbalance, in the hemisphere contralateral to the affected hand [22], between activity of the SMA—that directs intentional movements due to the inner context (so-called 'predictive' movements) [7, 18, 27]—and the activity of a lateral system, probably sited in the arcuate premotor area, which organizes automatic movements in response to external stimuli (so-called 'responsive' movements) [39, 42]. There are some clinical confirmations of this in Table 3 [21, 35, 52], especially one anatomopathological finding [3] and one electrophysiological finding [36].

(3) There is a final hypothesis that seems to be a compromise between the two, put forward, though incidentally, by LEIGUARDA *et al.* [28] (p. 1033). AH might occur because of an isolated callosal interruption and in this case it would be seen in the arm ipsilateral to the language and praxis dominant hemisphere, whereas the phenomenon would appear in the arm contralateral to the lesioned hemisphere if the lesion was also cortical. This possibility, however, appears to be contradicted by many cases and among them also by case No. 3 of the same authors.

Except for our case G.C. who had marked stability of the right AH (follow-up of 3 years), BANKS *et al.*'s [3] case No. 1 and TANAKA *et al.*'s [49] no other case to our knowledge (see Table 3) has been studied longitudinally: sometimes AH is described as fleeting and sometimes as persistent. GOLDBERG *et al.* [21] suggested that the fleeting AH that appears after surgical callosotomy [55] might be the result of cortical damage due to displacement during the operation of hemispheric structures contiguous to the CC. A similar explanation might be given for stroke patients with acute AH, hypothesizing passing functional damage (compression due to oedema) of the frontal structures: this was confirmed by 'cortical signs' in the patients described above.

We propose the alternative hypothesis that only the callosal lesion is necessary for the appearance of AH, but that to continue there must also be a fronto-mesial lesion encroaching upon the SMA contralateral to the AH. The fronto-mesial lesion would be the basis of the lack of compensation of the acute syndrome and cause the 'chronic AH syndrome'. Analogous mechanisms of compensation, possibly subcortical [34, 43, 44], have been hypothesized for other signs of callosal disconnection that tend to be compensated to a remarkable degree within a few months after operation [9]. However, no ideal case to demonstrate this hypothesis has as yet been reported. Ideally such a case would be one with two-step damage: appearance of and regression of AH after a callosal lesion; reappearance and stabilization of AH after a later fronto-mesial lesion. This would be analogous to the situation that helped to demonstrate the partial right hemispheric compensation of an aphasia that appeared and partially regressed after a lesion of the left hemisphere and worsened again after a later lesion in the right hemisphere [6, 25, 38] or the existence of a distributed network subserving the direction of spatial attention instead of a single parietal locus [13].

Our case suggests that AH is a 'frontal hand', being characterized by a 'frontal' context-

driven disinhibition (impulsiveness) [46]. We are not dealing with two wills, that of the right hemisphere and that of the left hemisphere, in which only one is accessible to the patient is verbal report and the other acts as a 'well-kept secret', but with an erroneous control of actions: in one hemisphere the internal/external balance being normal and the other imbalanced because the internal is virtually absent.

In conclusion, the AH can be conceived as a fragment of the frontal syndrome, demonstrating the possibility of separate lesions within a complex and extensive system of functional representation; such a system is very likely to encompass the fronto-mesial areas.

Analysis of the cases in the literature and of our longitudinally studied case supports the hypothesis of a fractionation of AH in an acute and a chronic form. It is only for the appearance of chronic form that, in agreement with GOLDBERG [21] it is necessary to have a double lesion, that is a lesion of the CC along with a lesion of the fronto-mesial cortical areas (possibly of the SMA).

Acknowledgements—We thank Mirella Crevacore for her editorial help, Gillian Jarvis who helped with the English version of the paper, Anna Basso, Ph.D., who kindly addressed the patients to us, and two anonymous referees for their comments. Research partly supported by grant to H.S. Nr. 87.00233.04.115.12234 of the Consiglio Nazionale delle Ricerche.

REFERENCES

1. AKELAITIS, A. J. Studies on the *corpus callosum*, IV: Diagonistic dyspraxia in epileptics following partial and complete section of the *corpus callosum*. *Am. J. Psych.* **101**, 594–599, 1944/45.
2. ALLAMANO, N., DELLA SALA, S., LAIACONA, M., PASETTI, C., and SPINNLER, H. The Towers of Hanoi Test, normative data. *Ital. J. neurol. Sci.* **8**, 111–120, 1987.
3. BANKS, G., SHORT, P., MARTINEZ, A. J., LATCHAW, R., RATCLIFF, G. and BOLLER, F. The Alien Hand Syndrome. Clinical and postmortem findings. *Archs Neurol.* **46**, 456–459, 1989.
4. BARBIZET, J., DEGOS, J. D., LEJEUNE, A. and LEROY, A. Syndrome de dysconnection inter-hémisphérique avec dyspraxie diagonistique au cours d'une maladie de Marchiafava-Bignami. *Rev. Neurol.* **134**, 781–789, 1978.
5. BARIGAZZI, R., DELLA SALA, S., LAIACONA, M., SPINNLER, H. and VALENTI, V. Esplorazione testistica della Memoria di Prosa. *Ricerche di Psicologia* **1**, 49–80, 1987.
6. BASSO, A., GARDELLI, M., GRASSI, M. P. and MARIOTTI, M. The role of the right hemisphere in recovery from aphasia. Two case studies. *Cortex* **25**, 555–566, 1989.
7. BERNSTEIN, N. A. The coordination and regulation of movement. Pergamon Press, Oxford, 1967.
8. BEUKELMAN, D. R., FLOWERS, C. R. and SWANSON, P. D. Cerebral disconnection associated with anterior communicating artery aneurysm: implications for evaluation of symptoms. *Archs Phys. Med. Rehabil.* **61**, 18–23, 1980.
9. BOGEN, J. E. The callosal syndrome. In *Clinical Neuropsychology*, K. M. HELLMAN and E. VALENSTEIN (Editors). Oxford University Press, London & New York, 1979.
10. BORRINI, G., DALL'ORA, P., DELLA SALA, S., MARINELLI, L. and SPINNLER, H. Autobiographical memory. Sensitivity to age and education of a standardized enquiry. *Psychol. Med.* **19**, 215–224, 1989.
11. BRION, S. and JEDYNAK, C. P. Trouble du transfert interhémisphérique à propos de trois observations de tumeurs du corps calleux: le signe de la main étrangère. *Rev. Neurol.* **126**, 257–266, 1972.
12. CHAN, J.-L. and ROSS, E. D. Left-handed mirror writing following right anterior cerebral artery infarction: evidence for nonmirror transformation of motor programs by right supplementary motor area. *Neurology* **38**, 59–63, 1988.
13. DAFNER, K. R., AHERN, G. L., WEINTRAUB, S. and MESULAM, M. M. Dissociated neglect behavior following sequential strokes in the right hemisphere. *Ann. Neurol.* **28**, 97–101, 1990.
14. DE BLESER, R., BAYER, J. and LUZZATTI, C. Die cognitive Neuropsychologie der Schriftsprache. Ein Ueberblick zwei deutscher Fallbeschreibungen. In *Grammatik und Cognition. Linguistische Berichte*, Suppl. 1, J. BAYER (Editor), pp. 118–162. Westdeutscher Verlag, Wiesbaden, 1987.
15. DE RENZI, E., MOTTI, F., and NICHELLI, P. Imitating gestures: a quantitative approach to ideomotor apraxia. *Archs Neurol.* **37**, 6–18, 1980.
16. ELITHORN, A. Intelligence perceptual integration and the minor hemisphere. *Neuropsychologia* **2**, 327–332, 1964.
17. FAGLIONI, P. and BASSO, A., Historical perspectives on neuroanatomical correlates of limb apraxia. In

- Neuropsychological Studies of Apraxia and Related Disorders*, E. A. ROY (Editor), pp. 3–44. North-Holland, Amsterdam, 1985.
18. FLOWERS, K. Lack of prediction in the motor behaviour of parkinsonism. *Brain* **101**, 35–52, 1978.
 19. GESCHWIND, N. and DAMASIO, A. R. *Apraxia. Handbook of Clinical Neurology*, Vol. 1 (45): *Clinical Neuropsychology*, J. A. M. FREDERIKS (Editor). Elsevier Science Publishers, Amsterdam, 1985.
 20. GIBB, W. R. G., LUTHERT, P. J., and MARSDEN, C. D. Corticobasal degeneration. *Brain* **112**, 1171–1192, 1989.
 21. GOLDBERG, G., MAYER, N. H. and TOGLIA, J. U. Medial frontal cortex infarction and the alien hand sign. *Archs Neurol.* **38**, 683–686, 1981.
 22. GOLDBERG, G. Supplementary motor area structure and function: Review and hypotheses. *Behav. Brain Sci.* **8**, 567–616, 1985.
 23. GOLDBERG, G. From intent to action. Evolution and function of the premotor system of the frontal lobe. In *The Frontal Lobes Revisited*, E. PERECMAN (Editor). IRBN Press New York, New York, 1987.
 24. GOLDENBERG, G., WIMMER, A., HOLZNER, F. and WESSELY, P. Apraxia of the left limbs in a case of callosal disconnection: the contribution of medial frontal lobe damage. *Cortex* **21**, 135–148, 1985.
 25. GOWERS, W. R. Lectures on the diagnosis of diseases of the brain, pp. 131–132. Churchill, London, 1887.
 26. GRAFF-RADFORD, N. R., WELSH, K. and GODERSKY, J. Callosal apraxia. *Neurology* **37**, 100–105, 1987.
 27. GREGORY, R. L. On how little information controls so much behaviour. *Ergonomics* **13**, 25–35, 1970.
 28. LEIGUARDA, R., STARKSTEIN, S. and BERTHIER, M. Anterior callosal hemorrhage. A partial interhemispheric disconnection syndrome. *Brain* **112**, 1019–1037, 1989.
 29. LEVINE, D. N. and RINN, W. E. Opticosensory ataxia and alien hand syndrome after posterior cerebral artery territory infarction. *Neurology* **36**, 1094–1097, 1986.
 30. LIEPMANN, H. The syndrome of apraxia (motor asymboly) based on a case of unilateral apraxia. (Translation by W. H. O. BOHNE, K. LIEPMANN and D. A. ROTTENBERG from: *Monatschr. Psychiatrie Neurol.* **8**, 15–44, 1900.) In *Neurological Classics in Modern Translation*. D. A. ROTTENBERG and F. H. HOCHBERG, pp. 155–183. Hafner Press, New York, 1977.
 31. LIEPMANN, H. and MASS, O. Fall von linksseitiger Agraphie und Apraxie bei rechtsseitiger Lahmung. *Journal für Psychologie und Neurologie* **10**, 214–227, 1907.
 32. LORING, D. W., MEADOR, K. J. and PEET, G. P. Differential-handed response to verbal and visual spatial stimuli: evidence of specialized hemispheric processing following callosotomy. *Neuropsychologia* **27**, 811–827, 1989.
 33. LUZZATTI, C., WILLMES, K., BISIACCHI, P., DE BLESER, R., MAZZUCCHI, A., POSTERARO, L., TARICCO, M. and FAGLIA, L. L'Aachener Aphasie Test (AAT). II. Qualità psicometriche della versione italiana del test. *Archivio di Psicologia, Neurologia e Psichiatria* **48**, 480–519, 1987.
 34. MACKAY, D. M. and MACKAY, V. Explicit dialogue between left and right half-systems of split brains. *Nature (London)* **295**, 690–691, 1982.
 35. MAGNANI, G., MAZZUCCHI, A., POLETTI, A., SCODITTI, U. and PARMA, M. Involuntary grasping and groping responses to space-related visual stimuli. *Movement Disord.* **2**, 9–23, 1987.
 36. MCNABB, A. W., CARROLL, W. M. and MASTAGLIA, F. L. 'Alien hand' and loss of bimanual coordination after dominant anterior cerebral artery territory infarction. *J. Neurol. Neurosurg. Psychiatry* **51**, 218–222, 1988.
 37. MEADOR, K. J., WATSON, R. T., BOWERS, D. and HEILMAN, K. M. Hypometria with hemispatial and limb motor neglect. *Brain* **109**, 293–305, 1986.
 38. NIELSEN, J. M. *Agnosia, Apraxia, Aphasia: Their Value in Cerebral Localization*. Hoeber, New York, 1936.
 39. PAILLARD, J. The contribution of peripheral and central vision to visually guided reaching. In *Analysis of Visual Behaviour*, D. J. INGLE, M. A. GOODALE and R. J. W. MANSFIELD (Editors). MIT Press, Cambridge, 1982.
 40. REBEIZ, J. J., KOLODNY, E. H. and RICHARDSON, E. P. Corticodentatonigral degeneration with neuronal achromasia: a progressive disorder of late adult life. *Trans. Am. Neurol. Assoc.* **92**, 23–36, 1967.
 41. REBEIZ, J. J., KOLODNY, E. H. and RICHARDSON, E. P. Corticodentatonigral degeneration with neuronal achromasia. *Archs Neurol.* **18**, 20–33, 1968.
 42. RIZZOLATTI, G., MATELLI, M. and PAVESI, G. Deficits in attention and movement following the removal of postarcuate (area 6) and prearcuate (area 8) cortex in macaque monkeys. *Brain* **106**, 655–673, 1983.
 43. SERGENT, J. Subcortical coordination of hemisphere activity in commissurotomy patients. *Brain* **109**, 357–369, 1986.
 44. SERGENT, J. Furtive incursions into bicameral minds. Integrative and coordinating role of subcortical structures. *Brain* **113**, 537–568, 1990.
 45. SHAHANI, B., BURROWS, P. and WHITTY, C. W. M. The grasp reflex and perseveration. *Brain* **93**, 181–192, 1970.
 46. SHALLICE, T., BURGESS, P. W., SCHON, F., BAXTER, D. M. The origins of utilization behaviour. *Brain* **112**, 1587–1598, 1989.
 47. SPINNLER, H. and TOGNONI, G. (Editors). *Taratura e standardizzazione italiana di test neuropsicologici. Ital. J. Neurol. Sci. (Suppl. 6)*, 1987.
 48. STUSS, D. T. and BENSON, D. F. *The Frontal Lobes*. Raven Press, New York, 1986.
 49. TANAKA, Y., IWASA, H. and YOSHIDA, M. Diagonistic dyspraxia: case report and movement-related potentials. *Neurology* **40**, 657–661, 1990.

50. TANAKA, Y., IWASA, H. and OBAYASHI, T. Right hand agraphia and left hand apraxia following callosal damage in a right-hander. *Cortex* **26**, 665–671, 1990.
51. WATSON, R. T. and HEILMAN, K. M. Callosal apraxia. *Brain* **106**, 391–403, 1983.
52. WATSON, R. T., FLEET, W. S., GONZALEZ-ROTHI, L. and HEILMAN, K. M. Apraxia and the supplementary motor area. *Archs Neurol.* **43**, 787–792, 1986.
53. WEIGL, E. On the psychology of so called processes of abstraction. *Ztsch. Psychol.* **103**, 245. Translated in *J. Abnorm. Soc. Psychol.* **36**, 3–33, 1927.
54. WILSON, D. H., REEVES, A. GAZZANIGA, M. and CULVER, C. Cerebral commissurotomy for control of intractable seizures. *Neurology* **27**, 708–715, 1977.
55. WILSON, D. M., REEVES, A. and GAZZANIGA, M. Division of the *corpus callosum* for uncontrollable epilepsy. *Neurology* **28**, 649–653, 1978.