

Repeating through the insula: evidence from two consecutive strokes

Antonio Carota^a, Jean-Marie Annoni^a and Paola Marangolo^b

^aDepartment of Neurology, University Hospital of Lausanne (CHUV), CH-1011 Lausanne, Switzerland and ^bNeuropsychology Research Center, IRCCS Fondazione Santa Lucia, Rome, Italy

Correspondence to Dr Paola Marangolo, Centro Ricerche di Neuropsicologia, IRCCS Fondazione Santa Lucia, Via Ardeatina 306 00179 Rome, Italy
Tel: +390651501597; fax: +390651501366; e-mail: p.marangolo@hsantalucia.it

Received 27 March 2007; accepted 17 May 2007

Mixed transcortical aphasia is a very rare syndrome characterized by intact repetition, despite severe impairment in all other language modalities. In some cases, however, preservation of repetition is accompanied by intact reading. We report the case of a left-handed man who, after a subcortical stroke in the left hemisphere, showed the typical features of mixed transcortical aphasia with spared repetition and reading. After 10 days, a second stroke, involving the anterior insula and adjacent white matter bundles,

markedly deteriorated repetition while his reading abilities recovered. By comparing features of repetition and reading before and after the second stroke, we provide evidence for the existence of a modular organization of language abilities, pointing to the primary role of the insula and surrounding white matter in phonological processing. *NeuroReport* 18:1367–1370 © 2007 Lippincott Williams & Wilkins.

Keywords: arcuate fasciculus, insula, phonology, reading, repetition, transcortical aphasia

Introduction

Since Broca first reported an anatomoclinical correlation in the patient 'Tan' [1], several single case studies have highlighted the existence of double dissociations between different linguistic modalities. These dissociations gave rise to the well-known classification of the aphasia syndromes [2]. Mixed transcortical aphasia (MTA) is a rare syndrome, with less than 0.5% incidence in acute stroke [3], which is characterized by a marked dissociation between reduced speech, severe comprehension deficit, naming difficulties and intact or relatively spared repetition [4]. Another distinctive linguistic feature often reported with MTA is the unimpaired ability to read aloud despite a severe written comprehension deficit.

This pattern of aphasic deficits distinguishes MTA from other transcortical aphasias in which comprehension (in motor transcortical aphasia) or fluent speech production (in sensorial transcortical aphasia) are maintained, although repetition is almost intact.

Recently, the modern cognitive approach has considered the existence of these dissociations as evidence of a modular organization of language. Therefore, patients with MTA who show intact repetition and reading abilities, despite severe comprehension impairment, provide a unique opportunity to investigate how distinct functional neural modules process different language abilities. The existence of distinct and somehow independent language modules is hypothesized by the 'triple route' cognitive model [5] (Fig. 1), which describes the existence of a lexical-semantic pathway (*first route*) and two alternative routes for single word and nonword repetition and reading.

The *second route* involves simple acoustic-to-phonological (for repetition) and graphemic-to-phonological (for reading) translation processes that allow repeating and reading pronounceable nonwords and new words, which do not yet have a stored phonological representation. The *third route* proposes a direct link between the auditory (or graphemic) input lexicon and the phonological output lexicon. With this route, therefore, pronunciation is achieved lexically, without the activation of meaning, explaining how some aphasic patients can read orthographically irregular words (whose representations are stored in the lexicon) without comprehending them and how they can repeat and read words better than nonwords [6,7].

Over the last two decades, developments in the area of functional neuroimaging have allowed deeper investigation of the neurological correlates of linguistic functions. However, most of these studies were performed on healthy participants [8–10], and there are very few reports of linguistic abilities and neuroanatomical correlations in aphasic patients in whom a second consecutive stroke induced selective changes of the initial aphasic symptom [11–13].

Here we report the performance of a 76-year-old French participant (G.P.) in various linguistic tasks. The patient was submitted to language assessment on two different occasions: immediately after a first subcortical stroke, when he showed the classical MTA features, and 10 days later, immediately after a second stroke in the anterior insula and surrounding white matter, when his repetition was markedly deteriorated and his reading improved. By analyzing the double dissociation between repetition and reading

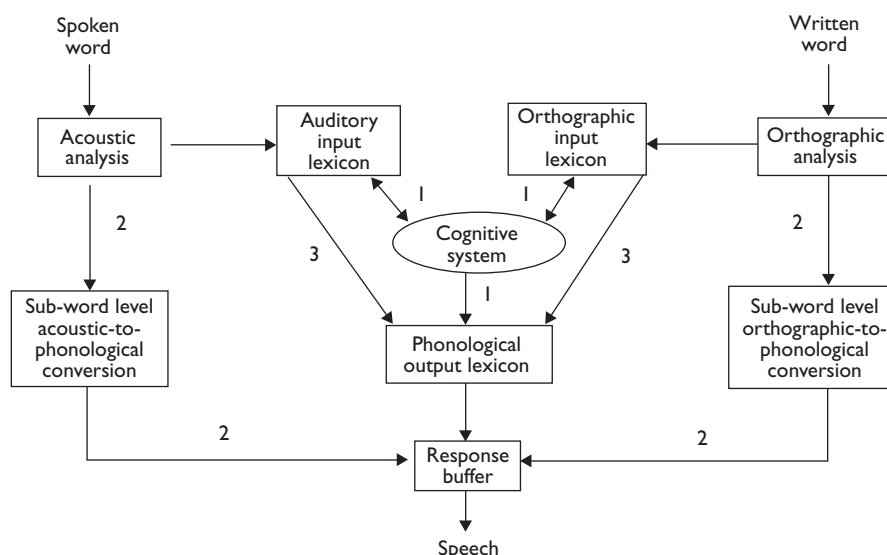


Fig. 1 The triple route model for word and nonword repetition and reading. 1, first route; 2, second route; 3, third route.

performances, we aimed to provide further evidence of almost complete functional segregation of the auditory from the visual, lexical and sublexical system.

Case report

G.P. was a healthy 76-year-old left-handed native French-speaking man with 9 years of formal education. He was a retired skilled worker who lived alone and was completely autonomous. The patient's relatives did not report any signs of memory, language or behavioral disturbances before the stroke. His medical and neurological history was unremarkable, except for arterial hypertension. G.P. was admitted to the CHUV hospital with an acute stroke, which manifested with signs of a complete left middle cerebral artery (MCA) syndrome (severe nonfluent aphasia, head and gaze deviation to the left, right hemiplegia and hypesthesia). Investigations revealed new-onset atrial fibrillation and left internal carotid artery occlusion.

For 10 days, G.P. remained alert but he made no attempt to communicate. However, almost every time someone spoke to him, he spontaneously echoed what the other had said. G.P. accurately repeated almost every word or short sentence spoken to him. Ten days later, his repetition abruptly deteriorated due to a second ischemic infarction, which, however, left his reading abilities preserved.

Magnetic resonance imaging investigations

The first stroke involved the head and the body of the caudate nucleus, the putamen, the pallidum and the corona radiata (Fig. 2a). Ten days later, a new MRI showed the enlargement of the previous lesion and the presence of a new ischemic area involving the anterior insula and adjacent white matter bundles (Fig. 2b and c).

Neuropsychological assessment

After the first stroke, language was assessed by means of the Montréal-Toulouse Protocol [14]. G.P. did not show any signs of comprehending simple commands, yes-no ques-

tions, gestures or contextual cues in conversational speech. Upon verbal or written commands, he pointed or touched objects randomly with his left hand. Word-picture matching tasks showed severe impairment for single words, verbs or phrases. G.P.'s spontaneous speech was completely abolished. He was able to complete a few proverbs and well-known phrases, but he was unable to complete automatic series, for example, counting, months of the year. Most agrammatical sentences were passively repeated without changes. Confrontation naming and naming from definition were compromised. Left-hand writing was distorted by nonsense graphic perseverations. Although G.P.'s ability to repeat and read aloud was remarkably intact (30 and 29 correct responses out of 33 stimuli, respectively), his ability to understand what he had read and repeated was severely damaged. This constellation of aphasic signs was highly suggestive of MTA.

Ten days later, G.P.'s repetition abruptly deteriorated because of a second stroke. When he attempted to repeat what was said to him, he produced numerous phonological paraphasias. However, he continued to read single words perfectly and, except for repetition, his aphasic disorder had not substantially changed.

Experimental investigation

Repetition and reading of single words ($n=460$) and pronounceable nonwords ($n=96$) were studied by means of the Examination of Acquired Dyslexia Battery for French speakers (EDA) [15]. In the EDA, words are grouped into the categories of simple and irregular orthography, concrete and abstract words, open-class and closed-class words, short (3–5 letters) and long (6–9 letters) words. Each category includes words with low (<20) and high (>50) lexical frequency in an inventory of 52 700 French words. EDA items were presented pseudorandomly for both repetition and reading, avoiding more than three consecutive stimuli in the same category. The complete EDA battery was administered four times over a 2-week period, two times after the first stroke and two times after the second stroke.

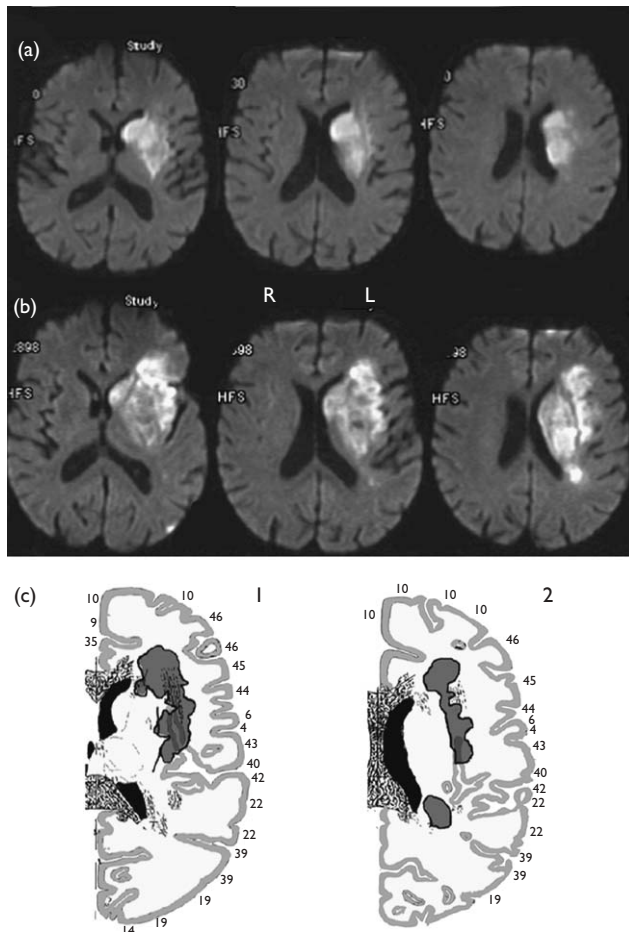


Fig. 2 (a) DWI-MRI images after the first stroke showing the involvement of the caudate nucleus, lenticular nucleus, internal capsule and corona radiata. (b) DWI-MRI images obtained after the second stroke showing the involvement of the anterior insula. (c) Reconstruction of the second stroke (grey color) on sections of the Tairarach and Tournoux stereotaxic atlas. The lesion involves the anterior insula and adjacent white matter bundles. L, left hemisphere; R, right hemisphere; 1, left hemisphere; horizontal section 16 mm above the CA-CP line; 2, left hemisphere; horizontal section 20 mm above the CA-CP line.

Results

Examination of acquired dyslexia battery

As shown in Table 1, after the first stroke there was no significant difference in G.P.'s accuracy (i.e. the number of correct responses) between repeating and reading words and nonwords (χ^2 =NS). In both modalities, better performances were noted for words than for nonwords ($P<0.001$).

Compared with the first assessment, after the second stroke G.P.'s EDA scores showed a significant decline for repetition of both words and nonwords ($P<0.001$). Most repetition errors (about 80%) consisted of phonological deviations [i.e. semaine (week)>semalle; asperge (asparagus)>arpage; animal (animal)>alimal]. Other errors, that is semantic, unclassifiable paraphasias and refusals, were present in equal proportions.

However, dissociated from repetition, G.P. showed significant improvement in reading both words ($P=0.006$) and nonwords ($P<0.001$).

No significant effect of the other tested factors (concreteness, frequency, regularity and length) was found in either examination.

Discussion

MTA is a rare aphasic syndrome in which the severity of impairments in speech production and comprehension differ markedly with almost completely spared word and nonword repetition and (sometimes) reading. Although there is some uncertainty about the amount of spared repetition (and reading) necessary to make a diagnosis of MTA [4], the severity of the oral (and written) comprehension deficits suggests that, in cases of MTA, these preserved abilities are not carried out through lexical-semantic routes, but through alternative asemantic pathways (see Fig. 1).

Such a disconnection is supposed to be the consequence of lesions that spare the perisylvian areas but isolate them from other associative language areas [16]. Indeed, in acute stroke, MTA classically occurs with two simultaneous anterior and posterior watershed infarcts in the MCA territory, at the boundary of the language areas in the dominant hemisphere [3].

G.P.'s first stroke extensively involved the basal ganglia and corona radiata in the left hemisphere, in the territory of the deep MCA perforator arteries. A subcortical localization, although unusual, has already been reported in MTA [17]. In a subcortical stroke, isolation of the perisylvian language areas may result from ischemic penumbra, thalamic-cortical disconnection or cortical diaschisis. Hence, in accordance with other studies [18], we can hypothesize that, in G.P., damage to the frontal periventricular white matter and basal ganglia disconnected the supplementary motor area and Broca's area, resulting in nonfluent aphasia, and that the comprehension deficit was caused by the interruption of temporal-thalamic connections.

However, the most important finding in this study of a patient with MTA was evidence of a double dissociation between word and nonword repetition (deteriorated) and reading (improved), which was demonstrated by language assessment performed after the occurrence of two consecutive strokes in a 10-day period. This situation made it possible to correlate directly the aphasic changes with the brain damage consequent to the second stroke. As far as we know, there are no reports of cases of MTA with similar anatomoclinical correlations. As stated in the introduction, the 'triple route' model offers one explanation of the dissociation between repetition and reading in some patients with transcortical aphasia [5]. The important assumption of this cognitive model is the existence of three independent routes for words and nonwords and for repetition and reading, respectively. Although there is wide consensus regarding lexical-semantic and conversion routes (see Fig. 1) for word and nonword processing, the presence of a direct link between input and output lexicons, which allows reading words that are orthographically irregular, is still a debated issue. One further assumption of the model is that the different modules subserving repetition and reading are functionally segregated and, therefore, could be selectively damaged consequent to brain lesions. We believe that our findings provide further support for both assumptions.

After the first stroke, the preservation of word and nonword repetition and reading with poor comprehension and no other lexical and semantic effects (i.e. effects of frequency, imageability and content of words) indicates that, in both modalities, G.P. was bypassing the lexical-semantic pathway (*first route*) and relying mainly on acoustic-to-phonological and graphemic-to-phonological conversion rules (*second route*; see Fig. 1). However, although this route

Table 1 G.P.'s percentage and number of correct responses at the EDA, after the first and the second stroke, respectively for repetition and reading of single words and pronounceable nonwords

	Repetition			Reading		
	I stroke	II stroke	P	I stroke	II stroke	P
Words (n=460)	0.93 (429)	0.43 (196)	<0.001 ^a	0.93 (427)	0.98 (450)	0.006 ^b
Nonwords (n=96)	0.73 (70)	0.22 (21)	<0.001 ^a	0.81 (78)	1.00 (96)	<0.001 ^b
P	<0.001	<0.001		<0.001	NS	
Repetition (words, nonwords)				NS		
Reading (words, nonwords)	NS					

The proportion of correct responses is reported and the number of correct responses is given in parentheses.

EDA, examination of acquired dyslexia; NS, not significant; P, significance at the χ^2 -test.

^aImpairment.

^bImprovement.

allows G.P. to repeat and read nonwords, it cannot explain the preservation of irregular word reading, whose representation could not be retrieved/accessed by simple grapheme-to-phoneme mapping. The activation of a *third route*, which proposes a direct link between the orthographic input and phonological output lexicons, would justify G.P.'s preserved ability to read these words. Although G.P. was not able to understand the meaning of what he read by this route, owing to the absence of semantic activation, he was still able to retrieve the stored lexical representation of irregular words [6,7].

G.P.'s almost intact ability to read and repeat words and nonwords and the preservation of his ability to read irregular words indicate that little or no damage occurred in the rule conversion route and the lexical route after the first stroke.

Furthermore, the linguistic changes that occurred as a consequence of the second stroke in the insular region, that is marked deterioration of word and nonword repetition and improvement in reading words and nonwords, provide a basis for two further conclusions.

First, they contribute to confirming the modularity assumption by supporting the independence of different linguistic functional pathways [19,20]. Second, they provide additional evidence for the primary role of the insula and adjacent white matter tracts in phonological processing (particularly in word and nonword repetition), as already proposed based on classical clinical-anatomical correlation studies in stroke patients [21,22].

Acknowledgements

The authors thank Dr F. Vingerhoets for his clinical observations, Dr P. Maeder, Dr N.K. Mishra and S.P. Koniak for their useful comments and Dr A. Rossetti and Dr C. Cereda for their help in test administration.

References

- Broca PP. Loss of word, chronic encephalomalacia and partial destruction of the left anterior cerebral lobe. *Bulletin de la Société Anthropologique* 1861; 2:235–238.
- Wernicke C. The aphasia symptom complex. In: Church A, editor. *Diseases of the nervous system*. New York: Appleton, 1908.
- Bogousslavsky J, Regli F, Assal G. Acute transcortical mixed aphasia. A carotid occlusion syndrome with pial and watershed infarcts. *Brain* 1988; 111:631–641.
- Benson D, Ardila A. *Aphasia: a clinical perspective*. Oxford: Oxford University Press; 1996.
- Southwood MH, Chatterjee A. The interaction of multiple routes in oral reading: evidence from dissociations in naming and oral reading in phonological dyslexia. *Brain Lang* 2000; 72:14–39.
- Marangolo P, Basso A. Reading of lexically stressed words by Italian aphasic patients: a retrospective study. *Neuropsychology* 1998; 12:573–577.
- Howard D, Franklin S. *Missing the meaning? A cognitive neuropsychological study of processing words by an aphasic patient*. Cambridge, Massachusetts: The MIT press; 1988.
- Nucifora PG, Verma R, Melhem ER, Gur RE, Gur RC. Leftward asymmetry in relative fiber density of the arcuate fasciculus. *NeuroReport* 2005; 31:791–794.
- Heim S, Eickhoff SB, Opitz B, Friederici AD. BA44 in Broca's area supports syntactic gender decisions in language production. *NeuroReport* 2006; 31:1097–1101.
- Demonet JF, Thierry G, Cardebat D. Renewal of the neurophysiology of language: functional neuroimaging. *Physiol Rev* 2005; 85:49–95 (review).
- Zahn R, Huber W, Drew E, Specht K, Kenney S, Reith W, et al. Recovery of semantic word processing in transcortical sensory aphasia: a functional magnetic resonance imaging study. *Neurocase* 2002; 8:376–386.
- Hart RP, Rosner MJ, Muizelaar P. Recovery from aphasia following extracranial-intracranial bypass surgery: case report. *J Clin Exp Neuropsychol* 1985; 7:224–230.
- Chiacchio L, Grossi D, Stanzione M, Trojano L. Slowly progressive aphasia associated with surface dyslexia. *Cortex* 1993; 29:145–152.
- Nespoulous J, Roch-Lecours A, Lafond D, Lemay A, Puel M, Joannette Y, et al. *Protocole Montréal-Toulouse d'examen linguistique de l'aphasie*. MT86. Isbergues, France: l'Ortho-Edition; 1992.
- Lemay MA. *Acquired dyslexia examination (EDA)*. PointCarré Edition; 1990.
- Geschwind N, Quadfasel F, Segarra J. Isolation of the speech area. *Neuropsychologia* 1968; 6:327–340.
- D'Esposito M, Alexander MP. Subcortical aphasia: distinct profiles following left putaminal hemorrhage. *Neurology* 1995; 45:38–41.
- Freedman M, Alexander MP, Naeser MA. Anatomic basis of transcortical motor aphasia. *Neurology* 1984; 34:409–417.
- Caramazza A. On drawing inferences about the structure of normal cognitive systems from the analysis of patterns of impaired performance: the case for single-patient studies. *Brain Cogn* 1986; 5:41–66.
- Caramazza A. Some aspects of language processing revealed through the analysis of acquired aphasia: the lexical system. *Ann Rev Neurosci* 1988; 11:395–421.
- Benson DF, Sheremata WA, Bouchard R, Segarra JM, Price D, Geschwind N. Conduction aphasia. A clinicopathological study. *Arch Neurol* 1973; 28:339–346.
- Kreisler A, Godefroy O, Delmaire C, Debachy B, Leclercq M, Pruvo JP. The anatomy of aphasia revisited. *Neurology* 2000; 54:1117–1123.