

Functional vibratory stimulation on the hand facilitates voluntary movements of a hemiplegic upper limb in a patient with stroke

Izumi Shirahashi, Shuji Matsumoto, Megumi Shimodozono, Seiji Etoh and Kazumi Kawahira

The use of a new device consisting of a small vibrator to deliver functional vibratory stimulation (FVS) to the arm resulted in improvements of flexion of the hemiparetic shoulder in a man with thalamic bleeding. FVS delivered to the palm enabled the patient to repeat flexing his hemiparetic shoulder to manipulate objects with his hand. The functions of the patient's hemiparetic shoulder and fingers improved after treatments using FVS for 1 month. We examined whether FVS of the hemiplegic upper limb could facilitate voluntary movements of the limb by increasing the excitability of the motor cortex or the spinal motor neurons using somatosensory-evoked potentials, transcranial magnetic stimulation, F-wave, and single photon emission computed tomography. Our results did not detect an increase of excitability in the motor cortex or

in spinal motor neurons by FVS. *International Journal of Rehabilitation Research* 30:227–230 © 2007 Lippincott Williams & Wilkins.

International Journal of Rehabilitation Research 2007, 30:227–230

Keywords: stroke, thalamus, upper limb, vibratory stimulation

Department of Rehabilitation and Physical Medicine, Kagoshima University Graduate School of Medical and Dental Sciences, Kirishima-shi, Kagoshima, Japan

Correspondence to Megumi Shimodozono, MD, PhD, Department of Rehabilitation and Physical Medicine, Kagoshima University Graduate School of Medical and Dental Sciences, 3930-7, Makizono-cho, Kirishima-shi, Kagoshima, 899-6603, Japan
Tel: +81 995 78 2077; fax: +81 995 64 4045;
e-mail: izmine@m.kufm.kagoshima-u.ac.jp

Introduction

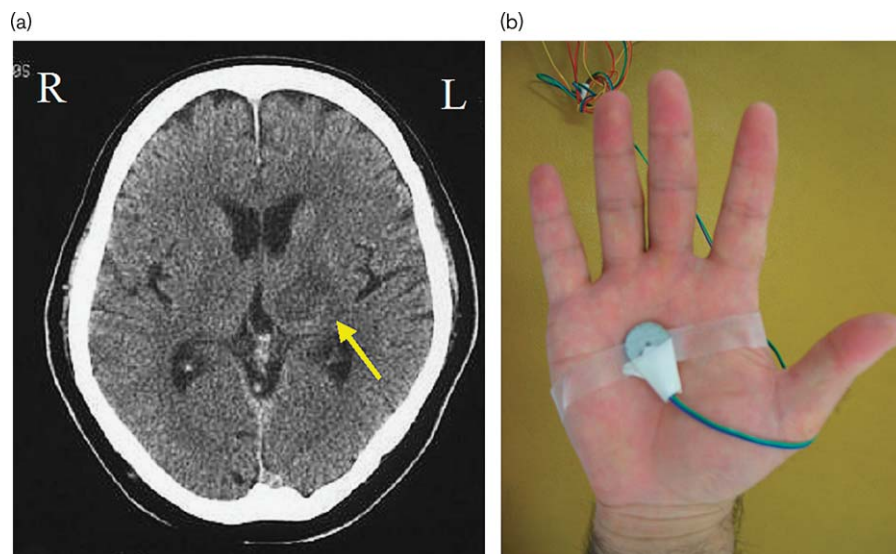
Patients with lesions involving the thalamus and internal capsule might show disturbances in hand function owing to insufficient shoulder function. In these patients, and most others with hemiparesis, improving the shoulder function is necessary to enable them to lift the arms when they reach for and manipulate objects by hand. Intensive therapies should include the repetition of facilitation exercises, which have been shown to improve the hemiplegic lower limb (Kawahira *et al.*, 2004a). Therapeutic electric stimulation on the shoulder, in addition to conventional occupational therapy, has been used to improve function. Here, we report a patient whose shoulder flexion was facilitated by sensory stimulation and who showed improvement when reaching out for objects after treatment using functional vibratory stimulation (FVS) to the palm. FVS has been shown previously to improve gait speed (Kawahira *et al.*, 2004b). The mechanisms of action of FVS to the palm, which enabled the patient to flex his hemiparetic shoulder, were examined using somatosensory-evoked potentials (SSEPs), transcranial magnetic stimulation, F-wave, and single photon emission computed tomography (SPECT).

Case report

A sixty-two-year-old man suffered left thalamic hemorrhage, which resulted in right hemiplegia. As shown in Fig. 1a, a low-density area on CT, involving the left

thalamus and, partially, the internal capsule, was detected. One month later, he entered our hospital for rehabilitation treatment for the hemiplegia. The severity of hemiparesis of the right extremities was Brunnstrom stage 4 in the upper limb, 6 in the hand, and 5 in lower limb. As shown in Fig. 2a, 2 weeks later, the patient found that he could raise his right arm by more than 135° with his elbow extended when he held something such as a soft paper ball or a handkerchief in his right palm; however, he could raise his arm only by 70° or less when he held nothing in his right palm. He underwent physical and occupational therapies, including facilitation exercise, to elicit shoulder flexion in the supine or sitting positions, or when reaching for a target, or carrying objects such as pegs, balls, and blocks. Although sensory stimulation to his hemiplegic hand, induced by gripping objects, facilitated his shoulder flexion, he was unable to release these objects during shoulder flexion because his arm dropped immediately after releasing the objects in his hand. As shown in Fig. 2, to facilitate his shoulder flexion without gripping objects, FVS was applied by a small vibrator fixed to his hemiparetic upper limb. FVS application to the palm, back of the hand, forearm, and shoulder facilitated the flexion of the arm, with that on the palm being most effective. The patient was able to flex his hemiparetic arm by more than 135° during FVS, but the arm dropped when the FVS was stopped during his shoulder flexion.

Fig. 1



(a) Brain lesion in computed tomography (CT). A low-density area involved in the left thalamus and internal capsule. (b) Functional vibratory stimulation and the stimulated site of the hemiparetic upper limb. A small vibrator, 18 mm in diameter and 3 mm in height, was stabilized on the palm by a bandage, to deliver functional vibratory stimulation. The device consisted of one battery, a small vibrator, and a connecting wire.

As part of the treatment using FVS, the patient held a ball in front of his chest and moved the ball to a high and far point, which required flexion of the shoulder. After reaching the target, the patient released the object and withdrew the arm to the starting point (Fig. 2). FVS to the palm was switched on, by an occupational therapist, from the time of holding the ball to that of withdrawing to the starting point. In addition to conventional occupational therapy for 40 min, the new FVS treatments were applied for 20 min a day, 5 days a week. The patient recovered the flexion of his shoulder by more than 135° and the manipulation of objects by hand, after 4 weeks of FVS treatment. The effects of FVS to the palm, which enabled the patient to flex his hemiparetic shoulder, were examined using SSEPs, transcranial magnetic stimulation, F-wave, and SPECT.

Somatosensory-evoked potentials

SSEPs were elicited by electrical stimulation to the median nerve at the wrist. Recording electrodes were placed over the scalp, the spine, and peripheral nerves proximal to the stimulation site. The primary cortical SSEP component following median-nerve stimulation, N20, was recorded as a near-field potential over the parietal areas. The patient's N20 wave recorded from his injured side was reduced, compared with that recorded from his noninjured side (Fig. 3).

Magnetic-evoked potential

Electromyograms were recorded with a gain of 1000 and 5000, using Ag–AgCl surface electrodes over the right

first dorsal interosseous and the right deltoid muscles, respectively. Magnetic stimulation was given over the hand and shoulder areas of the motor cortex, using a hand-held figure-8 coil placed tangential to the scalp, with the handle pointing posteriorly. A single pulse was delivered using a Magstim Super Rapid stimulator (The Magstim Company, Whitland, Carmarthenshire, Wales, UK). The stimulation intensity to activate the motor threshold was considered to be the minimum single-pulse intensity required to produce a magnetic-evoked potential in more than five out of ten trials from the contralateral first dorsal interosseous muscle; during these trials, the patient would maintain a voluntary contraction of about 20% of maximum, using visual feedback. The patient's hand did not react to either the application or nonapplication of an FVS to his palm. The magnetic-evoked potential from the right deltoid muscle was not recorded when the maximum stimulation intensity was given.

The F-waves

The F-waves and M-responses were recorded from the short abductor muscles of the thumb, after supramaximal percutaneous electrostimulation of the median nerve at the wrist, using bipolar surface electrodes (Eisen *et al.*, 1977). The stimuli were adjusted to be 20% above the threshold of the maximum M-response. Twenty F-waves were recorded after the supramaximal current pulses at a rate of 0.5/s (0.5 ms duration). A stimulus rate of 0.5 Hz was used to elicit the F-responses, with a total analysis time of 100 ms. The cathode was placed proximally. The

Fig. 2

Improvements of the patient's shoulder flexion by vibratory stimulation to the palm. (a) He could not raise his right arm more than 70° when he held nothing in his right palm. (b) and (c) He could raise his right arm by more than 135°, but only when he had a block and a soft paper ball in his right palm. (d) He could raise his hand with a vibratory stimulation to his palm. (e) He held a ball before his chest and carried it to a high and distant point; this action necessitated flexion of the shoulder, reaching, releasing objects and withdrawing to the starting point when functional vibratory stimulation was delivered to his right palm.

measurement of F-waves in the patient was carried out with the patient at rest, when being stimulated by FVS, and after stimulation. No changes in F-waves resulting in an improvement of shoulder flexion were found.

Single photon emission computed tomography

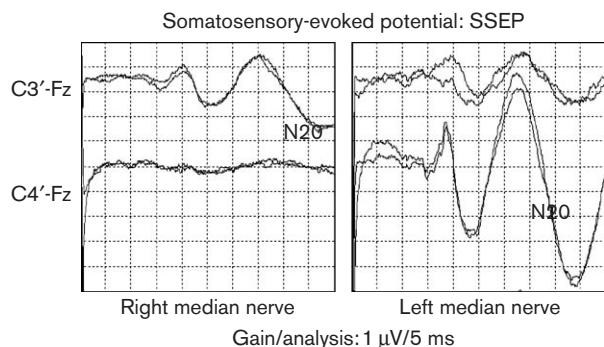
SPECT was performed before and after FVS. The initial SPECT began by injecting 99 mTc-ECD into the patient in 9 minutes. FVS for 30 s began when the initial SPECT ended and was maintained for 3 minutes during a second injection of 99 mTc-ECD. After 6 min, the second SPECT began. The increase in rate from the initial SPECT to the second SPECT was calculated. An increase was not observed in the motor area, but was observed in the sensory area.

Discussion

Previously, we described the utility of an FVS device that delivers vibratory stimulation whenever necessary, regardless of the posture or motion of the patient (Kawahira *et al.*, 2004b). In this case report, we demonstrated that targeted FVS to the palm of the hemiplegic upper limb significantly improved the flexion of the shoulder in a patient with a thalamic lesion whose shoulder flexion was facilitated by holding something in the hand.

The physiological effects of vibratory stimulation have been studied previously on muscle strength, standing balance, and sensory-motor systems. Few reports, however, consider the effects of vibratory stimulation during walking in healthy patients (Ivanenko *et al.*, 2000).

Fig. 3



The primary cortical somatosensory-evoked potentials (SSEP) component following median-nerve stimulation. N20 is recorded as a near-field potential over the parietal areas. A picture of electric stimulation to the patient's hemiplegic median nerve is on the left, and to his nonhemiplegic one on the right. The N20 wave in the injured side of his brain was smaller than that in the noninjured side.

Conventional vibrators have been used as therapeutic tools, but their size has made it difficult to deliver vibratory stimulation in active patients. In this study, FVS delivered to the palm enabled the patient to flex his hemiparetic shoulder and to manipulate objects with his hand. This improvement might be due to the increase in sensory input to the thalamus and sensory cortex. Training of the upper limb, including fingers, to recover voluntary movements, in patients with motor dysfunction due to decrease of sensory input, might be reduced by FVS.

Little physiological evidence exists, however, that vibratory stimulation to different body regions facilitates muscle contraction far from the stimulated body parts. The mechanisms of FVS to the palm, which enabled our

patient to flex his hemiparetic shoulder, were examined using SSEP, transcranial magnetic stimulation, F-wave, and SPECT. Changes in the excitability of the cerebral motor cortex and spinal motor neurons, or an increase in the blood flow in the cerebral motor cortex during FVS to the palm, were not detected. An increase in blood flow to the sensory cortex was, however, detected, which might stimulate the functions of the motor cortex. Of course, FVS to the palm can directly stimulate motor neurons in the spinal cord and the cerebral motor cortex through the activation of the thalamus.

Further research is needed to better define the mechanisms of functional motor recovery in hemiplegic patients using FVS during voluntary movements.

Conclusion

Targeted FVS to the palm of the hemiplegic upper limb significantly improved the flexion of the hemiparetic shoulder in a patient with a thalamic lesion, whose shoulder flexion was facilitated by holding something in the hand. FVS can be a useful treatment modality during therapeutic exercise for hemiparetic extremities.

References

- Eisen A, Schomer D, Melmed C (1977). The application of F-wave measurements in the differentiation of proximal and distal upper limb entrapments. *Neurology* **27**:662–668.
- Ivanenko YP, Grasso R, Lacquaniti F (2000). Influence of leg muscle vibration on human walking. *J Neurophysiol* **84**:1737–1747.
- Kawahira K, Shimodozono M, Ogata A, Tanaka N (2004). Addition of intensive repetition of facilitation exercise to multidisciplinary rehabilitation promotes motor functional recovery of the hemiplegic lower limb. *J Rehabil Med* **36**:159–164.
- Kawahira K, Higashihara K, Matsumoto S, Shimodozono M, Etoh S, Tanaka N, Sueyoshi Y (2004). New functional vibratory stimulation device for extremities in patients with stroke. *Int J Rehabil Res* **27**:335–337.