



CASE REPORT

# Preictal versus ictal injection of radiotracer for SPECT study in partial epilepsy: SISCOM

Seung Bong Hong<sup>a,\*</sup>, Eun Yeon Joo<sup>a</sup>, Woo Suk Tae<sup>a</sup>, Jae-Wook Cho<sup>a</sup>,  
Ji-Hyun Lee<sup>a</sup>, Dae Won Seo<sup>a</sup>, Yeon-Lim Suh<sup>c</sup>, Seung Chyul Hong<sup>b</sup>

<sup>a</sup> Department of Neurology, Samsung Medical Center, SBRI, Sungkyunkwan University School of Medicine, 50 Irwon-dong, Gangnam-gu, Seoul 135-710, South Korea

<sup>b</sup> Department of Neurosurgery, Samsung Medical Center, SBRI, Sungkyunkwan University School of Medicine, 50 Irwon-dong, Gangnam-gu, Seoul, South Korea

<sup>c</sup> Department of Pathology, Samsung Medical Center, SBRI, Sungkyunkwan University School of Medicine, 50 Irwon-dong, Gangnam-gu, Seoul, South Korea

Received 6 March 2007; received in revised form 20 July 2007; accepted 24 July 2007

## KEYWORDS

Epilepsy;  
Cerebral blood flow;  
SISCOM;  
Dysembryoplastic  
neuroepithelial tumor;  
SPECT

**Summary** A 27-year-old man had complex partial seizures and a dysembryoplastic neuroepithelial tumor (DNT) in the left inferior-basal temporal region. The patient's seizures consisted of incomprehensible speech, staring, unresponsiveness, fumbling and then looking around. For the brain SPECT study, radiotracer was injected during the preictal (11 s prior to seizure onset), ictal (at 25 s out of 47 s seizure duration) and interictal periods. Interictal SPECT was subtracted from preictal or ictal-injection SPECTs and then the subtracted SPECTs were overlaid on the patient's MRI (SISCOM). SISCOM with preictal-injection SPECT showed hyperperfusion at the brain lesion, whereas SISCOM with ictal-injection SPECT showed hyperperfusion at the ipsilateral amygdala-hippocampus and hypoperfusion around the tumor lesion. After the DNT and nearby temporal lobe tissues were resected with preservation of amygdala-hippocampus, the patient became seizure free without complaint of subjective postsurgical memory decline. In this patient, SISCOM with preictal injection of radiotracer localized an epileptogenic zone, whereas SISCOM with the ictal injection showed hyperperfusion at the symptomatogenic zone.

© 2007 British Epilepsy Association. Published by Elsevier Ltd. All rights reserved.

## Introduction

Ictal brain single photon emission computed tomography (SPECT) has been used to localize epileptic

foci in patients with partial epilepsy.<sup>1,2</sup> However, the results of ictal SPECT may depend on the radiotracer injection time.<sup>3</sup> Thus, in order to perform early ictal SPECT injections, detailed attention must be paid to ictal SPECT logistics setup.<sup>4</sup>

It is generally more difficult to localize the epileptic focus in temporal lobe epilepsy (TLE) when the lesion is near the hippocampus. Scalp EEG shows ictal discharges that are localized to

\* Corresponding author. Tel.: +82 2 3410 3592;  
fax: +82 2 3410 0052.

E-mail addresses: sbhong@skku.edu,  
seungbong.hong@samsung.com (S.B. Hong).

the temporal lobe encompassing a lesion as well as the hippocampus; ictal SPECT usually shows ictal hyperperfusion in the ipsilateral temporal region including both lesion and hippocampus. Furthermore, the ictal features of seizures arising from these lesions are similar to those of hippocampal origin seizures because ictal discharges quickly propagate to the ipsilateral hippocampus. Recently, a computer-aided method for the subtraction of interictal images from ictal SPECT and then the co-registration of the subtracted SPECT image to MRI, has been developed to further localize ictal-onset zones,<sup>5</sup> and is referred to as SISCOM.

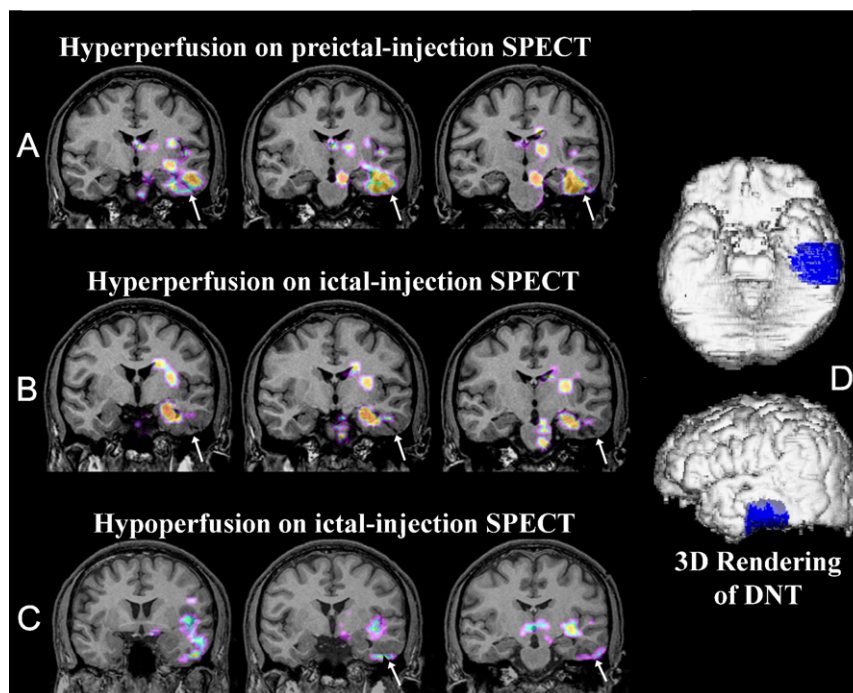
Dysembryoplastic neuroepithelial tumors (DNTs) are a group of glioneuronal supratentorial and intracortical lesions that are often associated with the early onset of intractable partial seizures.<sup>6</sup> The dysplastic cortex surrounding DNTs is usually epileptogenic per se.<sup>7</sup>

Here, we present a patient with intractable partial epilepsy and a lesion at the inferior-basal temporal region near the hippocampus who had both preictal and ictal injections of radiotracer for brain SPECT.

## Case report

A 27-year-old man suffered from intractable complex partial seizures consisting of incomprehensible speech, staring, unresponsiveness, fumbling and then looking around. Scalp EEG showed interictal spikes and ictal discharges at the left temporal lobe; the brain MRI showed a mixed density, irregularly shaped tumor located at the left inferior-basal temporal region (arrows in Fig. 1). The patient was on carbamazepine 600 mg and phenytoin 300 mg per day. He had a long-term video-EEG monitoring, interictal and ictal brain SPECTs.

Brain SPECT scans were performed at 30 min after injecting <sup>99m</sup>Tc-ethylcysteinate dimer (ECD) (925.9 MBq) using a three-headed Triad XLT system equipped with low-energy, high-resolution collimators (Trionix Research Laboratory, Twinsburg, OH). The transaxial system resolution of this camera was 6.9 mm and it had a full width at half maximum of 6.9 mm. The images were reconstructed using a filtered back-projection and a Butterworth filter (cutoff frequency, 0.6 cycle/cm; order, 3). The reconstructed spatial resolution of SPECT was 3.56 mm × 3.56 mm × 3.56 mm (x, y, z, respectively).



**Figure 1** SISCOM results. (A) SISCOM with preictal-injection SPECT shows hyperperfusion on the tumor lesion located at the left inferior-basal temporal area, ipsilateral midbrain, and thalamus. <sup>99m</sup>Tc-ECD injection was completed at 11 s before the seizure began. (B) SISCOM with ictal-injection SPECT shows hyperperfusion at the ipsilateral amygdala-hippocampus, basal ganglia and pons. The <sup>99m</sup>Tc-ECD injection was completed at 25 s out of a 47 s seizure duration. (C) SISCOM with ictal-injection SPECT shows hypoperfusion at the tumor lesion and adjacent temporal lobe tissues. (D) A three-dimensional rendering view of the patient's brain MRI and tumor (blue color). \*White arrows indicate the location of the tumor.

The patient underwent a preictal-injection SPECT (defined by a radiotracer injected before the seizures started on scalp EEG) and an ictal-injection SPECT (defined by a radiotracer injected during the seizures). The preictal-injection SPECT was obtained incidentally when the patient started to have a seizure 11 s after  $^{99m}\text{Tc}$ -ECD had been injected for interictal SPECT. Later, interictal SPECT was performed when the patient had not experienced a seizure during the previous 24 h.

SISCOM was performed on an offline workstation using ANALYZE 7.5 (Biomedical Imaging Resource, Mayo Foundation, Rochester, MN).<sup>8,9</sup>

SISCOM with preictal-injection SPECT showed hyperperfusion at the tumor lesion (Fig. 1A) whereas SISCOM with ictal-injection SPECT showed hyperperfusion at the ipsilateral amygdala-hippocampus (Fig. 1B) and hypoperfusion around the tumor (Fig. 1C). These images suggest that the seizure originated from the lesion, and propagated to the symptomatogenic zone in the amygdala-hippocampus region.

The patient underwent brain lesion resection with the preservation of the ipsilateral amygdala-hippocampus, and he has been seizure free for 2 years since the surgery. Postsurgically his antiepileptic medication was decreased to carbamazepine monotherapy and then tapered off gradually. Histopathologic examination of the resected brain samples revealed a nonspecific variant of a DNT. The EEG recorded at 1 year after the surgery showed intermittent slowing and breach rhythms on left fronto-temporal regions but no epileptiform discharges were observed.

## Discussion

This report shows that early radiotracer injection is important for correctly localizing seizure foci. Because ictal SPECT shows hyperperfusion at brain regions associated with high levels of electrical discharge activity, at the time of radiotracer brain uptake, a delayed injection during the later stage of a seizure could produce ictal hyperperfusion in brain regions outside the epileptic focus.<sup>8</sup> If a brain lesion is located in the extrahippocampal temporal region, in a case with typical hippocampal origin complex partial seizures, it is difficult to determine whether the ipsilateral hippocampus is an epileptogenic or symptomatogenic zone. This differentiation is of critical importance for successful epilepsy surgery with the preservation of memory. In a previous study, eight of 10 patients who had a lobectomy for a DNT, were completely seizure free; whereas, of the 11 patients who had a lesionectomy, only three

were completely seizure free.<sup>7</sup> Thus, in order to obtain a good surgical outcome, all epileptogenic brain tissues must be resected. Our patient has been seizure free without subjective complaint of post-surgical memory decline since the lesionectomy was performed with ipsilateral hippocampal preservation. This surgical decision was based on the preictal-injection SISCOM that confirmed that ictal discharges were limited to the DNT lesion, and did not involve the ipsilateral hippocampus at seizure onset (Fig. 1A). Theoretically, to localize an epileptogenic zone correctly by ictal SPECT, a radiotracer should be injected before the ictal discharges propagate to brain regions outside of the focus. However, because we cannot predict seizure occurrence, preictal injection is generally not possible. Thus, a seizure prediction algorithm or the availability of a suitable mechanical injector could reduce radiotracer injection delay times. Interestingly, SISCOM with ictal-injection SPECT showed hypoperfusion around the tumor. This finding suggests that ictal SPECT may show hypoperfusion at the epileptic focus producing initial ictal discharges, whereas hyperperfusion was noted at brain regions where ictal discharges were propagated at the time of radiotracer injection. A previous study suggested that ictal hypoperfusion, at the epileptic focus, may be due to 'intra-ictal early exhaustion of an initial seizure focus' or a 'steal phenomenon' from neighboring brain regions where ictal discharges are propagated.<sup>8</sup>

There may be an argument about preictal injection in our patient because intracranial electrode recordings occasionally show that seizure may begin very early on deep structures and is detected only late on scalp EEG. Also important is the knowledge of the tracer kinetics within human body. The tracer  $^{99m}\text{Tc}$ -ECD which was injected 11 s before the scalp EEG changes in our patient, has a high first-pass brain extraction rate, with maximum uptake being achieved within 30–60 s of an IV injection.<sup>10</sup> In fact, brain SPECT with the tracer preictally injected in our case will actually represent the 'just preictal' and 'ictal' perfusion changes of an ongoing seizure just started in the basal temporal lobe cortex and detectable by scalp EEG. Thus, we named this as 'preictal-injection SPECT' which is not equal to 'preictal SPECT' representing cerebral perfusion changes during preictal period. On the other hand, brain SPECT with radiotracer injected during seizure (at 25 s out of a 47 s seizure duration) may represent perfusion changes of 'ictal period' or 'ictal and just postictal periods'. A previous study performed 'preictal SPECTs' by injecting  $^{99m}\text{Tc}$ -HMPAO at 11 and 12 min before seizure onset in two patients with TLE.<sup>11</sup> Their preictal SPECTs showed increased rCBF

in the epileptic temporal lobe although there were no significant changes on the ongoing EEG at the time of injection and 10 min thereafter.

In summary, we described a patient with complex partial seizures due to a left temporal lobe DNT that was identified as an ictal-onset zone by brain SPECT with preictal injection of radiotracer.

## Acknowledgements

This study was supported by the Brain Research Center of the 21st Century Frontier Research Program funded by the Ministry of Science and Technology of the Republic of Korea (#M103KV010017-07K2201-01710), by a grant (no. A050462) of the Good Health R;D Project, Ministry of Health ; Welfare, Republic of Korea, and by the Samsung Biomedical Research Institute grant, #SBRI C-A6-435-1.

## References

1. Kim SJ, Kim SE, Hong SB, Seo DW, Hong SC, Na DG, et al. SPECT and PET for the localization of seizure foci in localization-related epilepsy. *J Korean Neurol Assoc* 1998;16:28–35.
2. Devous Sr MD, Thisted RA, Morgan GF, Leroy RF, Rowe CC. SPECT brain imaging in epilepsy: a meta-analysis. *J Nucl Med* 1998;39:285–93.
3. Van Paesschen W. Ictal SPECT. *Epilepsia* 2004;45(Suppl 4):35–40.
4. Wichert-Ana L, Velasco TR, Terra-Bustamante VC, Alexandre Jr V, Guarnieri R, Walz R, et al. Ictal chronology and interictal spikes predict perfusion patterns in temporal lobe epilepsy: a multivariate study. *Seizure* 2004;13:346–57.
5. Zubal IG, Spencer SS, Imam K, Seibyl J, Smith EO, Wisniewski G, et al. Difference images calculated from ictal and interictal technetium-99m-HMPAO SPECT scans of epilepsy. *J Nucl Med* 1995;36:684–9.
6. Daumas-Duport C, Scheithauer BW, Chodkiewicz JP, Laws Jr ER, Vedrenne C. Dysembryoplastic neuroepithelial tumor: a surgically curable tumor of young patients with intractable partial seizures. Report of thirty-nine cases. *Neurosurgery* 1988;23:545–56.
7. Raymond AA, Fish DR, Sisodiya SM, Alsanjari N, Stevens JM, Shorvon SD. Abnormalities of gyration, heterotopias, tuberos sclerosis, focal cortical dysplasia, microdysgenesis, dysembryoplastic neuroepithelial tumour and dysgenesis of the archicortex in epilepsy. Clinical, EEG and neuroimaging features in 100 adult patients. *Brain* 1995;118(Pt 3):629–60.
8. Lee HW, Hong SB, Tae WS. Opposite ictal perfusion patterns of subtracted SPECT. Hyperperfusion and hypoperfusion. *Brain* 2000;123(Pt 10):2150–9.
9. Shin WC, Hong SB, Tae WS, Kim SE. Ictal hyperperfusion patterns according to the progression of temporal lobe seizures. *Neurology* 2002;58:373–80.
10. O'Brien TJ, O'Connor MK, Mullan BP, Brinkmann BH, Hanson D, Jack CR, et al. Subtraction ictal SPET co-registered to MRI in partial epilepsy: description and technical validation of the method with phantom and patient studies. *Nucl Med Commun* 1998;19:31–45.
11. Baumgartner C, Serles W, Leutmezer F, Pataraja E, Aull S, Czech T, et al. Preictal SPECT in temporal lobe epilepsy: regional cerebral blood flow is increased prior to electroencephalography-seizure onset. *J Nucl Med* 1998;39:978–82.