

## Cervical intramedullary cavernous angioma with MRI-proven haemorrhages

H. M. Mehdorn and D. Stolke

Neurochirurgische Universitätsklinik, Weimarer Strasse 8, W-2300 Kiel 1, Federal Republic of Germany

Received September 6, 1990 / Received in revised form November 28, 1990 / Accepted January 21, 1991

**Summary.** Two contrasting cases of cervical intramedullary cavernous angioma in young female patients are reported. One patient had a 3-year course of step-wise progressive tetraparesis; at each of the five events intramedullary bleeding from a cryptic vascular malformation at C6-7 level was diagnosed by MRI. The other patient presented with one episode which led to MRI diagnosis of a vascular malformation at the C2 level. Both patients eventually underwent complete surgical excision of the angioma with subsequent steady improvement of the neurological deficit.

**Key words:** Spinal cavernoma – Magnetic resonance imaging – Arteriovenous malformation

### Introduction

In 1912, surgical removal of an intramedullary spinal cavernous angioma by Garré [30] followed by improvement of the patient's Brown-Séquard syndrome was reported. Until 1985, only an additional 11 surgically treated cases were reported [3, 4, 9, 11, 13, 22, 29, 30, 33] in the literature (see Table 1). However, since 1986, 20 further cases have been reported, indicating that spinal cavernomas occur more frequently than previously thought [2, 5, 19, 24, 27, 28, 34–38, 41]. We report two additional patients who had intraspinal cavernous angiomas diagnosed after they became symptomatic with episodes of intramedullary bleedings. The contrast in the diagnostic and therapeutic management of the two patients prompted this report. One patient had suffered five haemorrhages, proven by magnetic resonance imaging (MRI) (and this may represent the natural history of the disease), before she was referred to us for therapy, while the other one was transferred for therapy after the first bleeding episode.

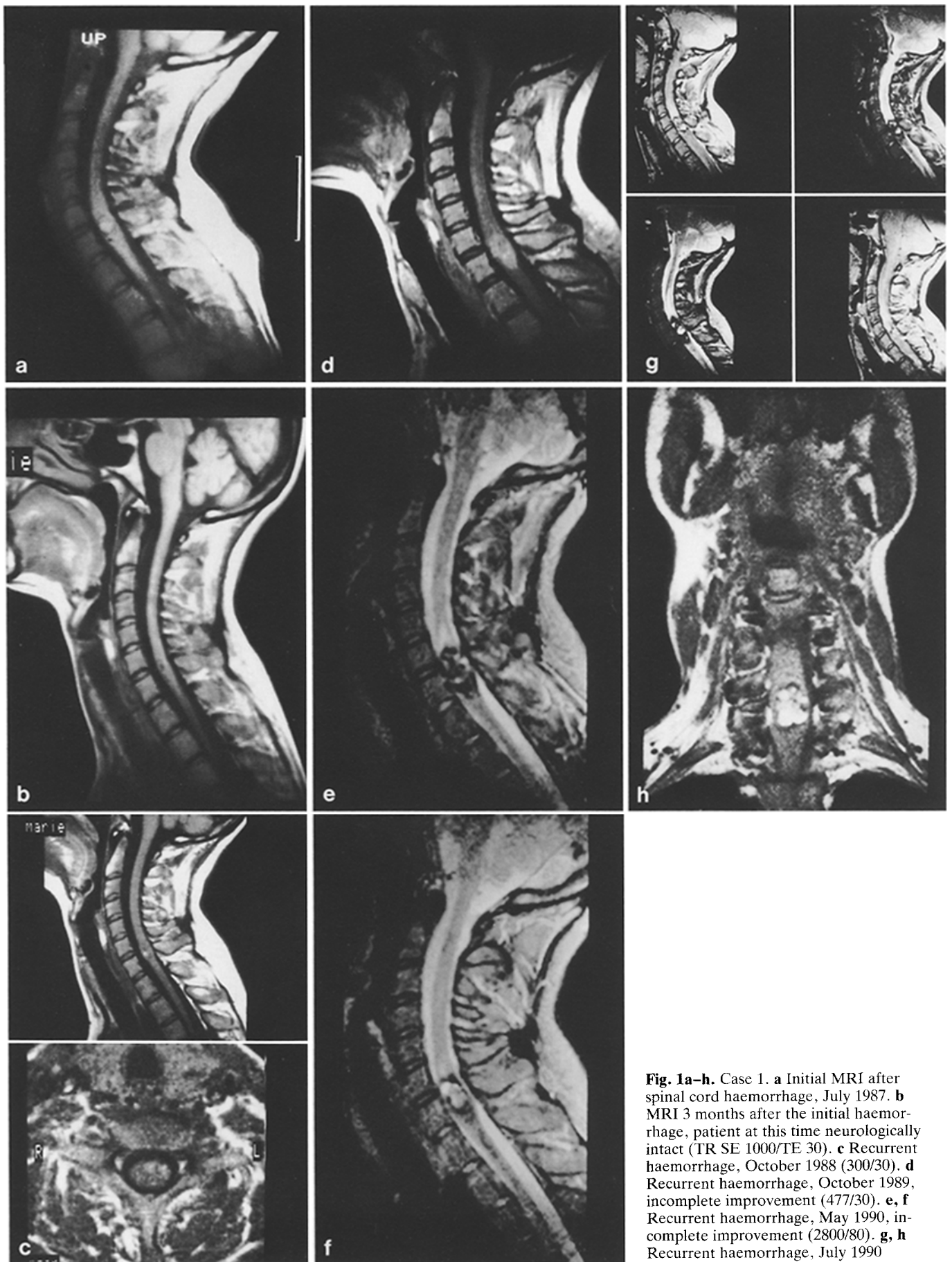
### Case reports

#### Case 1

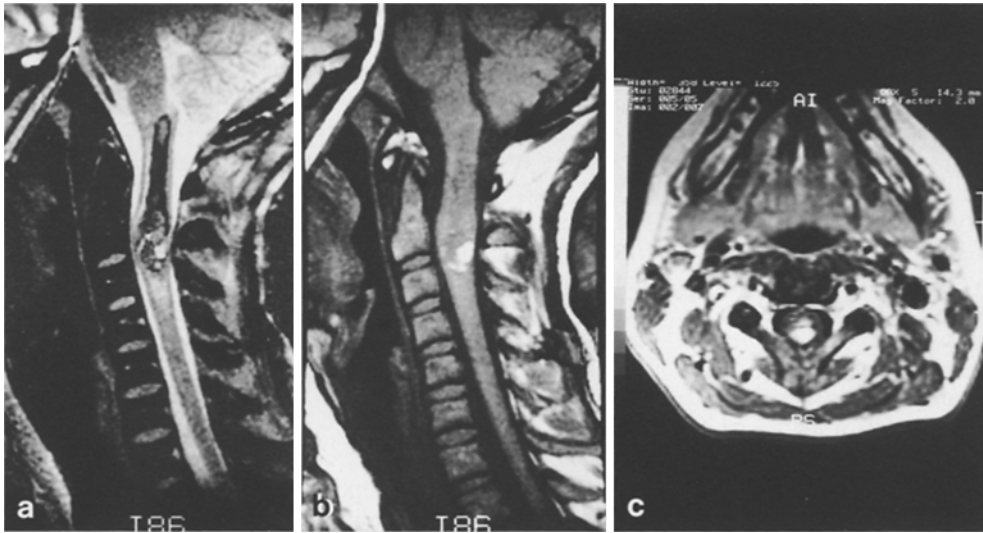
At the time of first bleed in July 1987, this female patient was aged 29 years; she suffered an acute onset of pain in the right arm extending along the C7 dermatome; after a few days, she noticed spasticity in the digits IV and V of her right hand, and was unsuccessfully treated by an orthopaedist, subsequently referred to a neurologist and underwent MRI. The first MRI (Fig. 1a), performed 2 weeks after the acute onset of symptoms, showed a small, anteriorly located intense signal lesion surrounded by a low-intensity rim, at the level of C6-7, and additionally a low intensity line just below the lesion; angiography was normal, so the diagnosis of cryptic arteriovenous malformation, possibly a cavernous angioma, was made. A repeat MRI study (Fig. 1b), performed 3 months after the initial bleeding and after her symptoms had completely resolved, showed a low-intensity lesion at the site of the previous haemorrhage, partially surrounded by an iso-intense lesion, indicating that the haemorrhage had resolved (leaving haemosiderin and/or vessels) and that the cavernoma itself was revealed. However, 1 year after the first haemorrhage (October 1988), she developed the same symptoms as described above, and underwent repeat of MRI (Fig. 1c). Again, the high-intensity lesion was present, at the site of the previous low-intensity area, suggestive of another haemorrhage. At this time, the mass effect of the lesion was less obvious than on the first MRI scan: the subarachnoid space anterior and posterior to the spinal cord was still present, shown well on the axial slice, which also shows the location of the haemorrhage. Again, the symptoms resolved completely. In 1989, when another episode of haemorrhage had occurred, she complained of increase of her pain (in the C7 distribution), but also noted some difficulty in her gait suggestive of disturbed proprioceptive sensation. At this time, the T1-weighted image (Fig. 1d) showed a high-intensity signal through the entire sagittal diameter of the spinal cord, and the nearly iso-intense lesion seemed to be pushed backwards from its previous position. Application of gadolinium-DTPA did not yield any additional information. Spinal angiography was performed to exclude any other vascular disease of the spinal canal and was negative. In May 1990, she experienced progressive, step-wise worsening of gait after acute onset of pain to the point that she became unable to walk; also, progressive weakness of her left and to a lesser degree of her right hand became evident. MRI performed after this episode showed, on T2-weighted images, mixed signal intensities in the core of the lesion surrounded by the low-intensity rim, and again this lesion was seen nearly through the entire sagit-

Table 1. Summary of published surgical cases, 1912–1990

Author	Age (years)	Sex	Location	Duration	Clinical presentation of symptoms	Diagnostic steps	Surgical removal	Results
Schultze 1912	29	M	C6-7	2 years	Progressive Brown-Séquard	Clinical	Complete	Improved
Bergstrand et al. 1964	50	F	D2	4 years	Progressive paraparesis and sensory deficit	Gas myelography	Complete	Unchanged
Bergstrand et al. 1964	47	F	Conus medullaris	1 year	Progressive paraparesis and sensory deficit	Gas myelography	Complete	Improved
Goran et al. 1964	59	F	D3-4	2 years	Progressive paraparesis	Myelography	Complete	Improved
Schröder and Brunngreber 1964	42	F	D3-5	9 years	Progressive paraparesis "multiple sclerosis"	Clinical	Complete	Worse
Bicknell et al. 1978	32	F	D6-7	12 years	Step-wise progressive paraparesis	Myelography	Incomplete	Progressively worse
Kitahara et al. 1982	47	F	L3-4		Progressive paraplegia	Myelography	Complete	Improved
Heimberger et al. 1982	24	M	D2	13 months	4 Subarachnoid haemorrhages	Myelography	Complete	Normal
Tyndel et al. 1985	27	F	C5-6		Progressive paraparesis	Myelography	Complete	Improved
Ueda et al. 1987	28	M	L1-2	3 years	2 Subarachnoid haemorrhages	Myelography, MRI	Complete	Normal
Vaquero et al. 1988	25	F	C6-7	3 years	Progressive paraparesis and sensory deficit	Myelography	Complete	Worse
Vaquero et al. 1988	27	F	D7-8	2 years	Progressive paraparesis and sensory deficit, bladder dysfunction	Myelography, MRI	Complete	Worse
Cosgrove et al. 1988	34	F	D2-3	1 week	Progressive sensory deficit	Myelography	Biopsy	Improved
Cosgrove et al. 1988	33	F	C6-7	3 months	Progressive Brown-Séquard	Myelography	Subtotal	Unchanged
Cosgrove et al. 1988	51	F	D2-3	3 years	Progressive paraplegia, sensory deficit, bladder dysfunction	Myelography	Subtotal	Unchanged
Cosgrove et al. 1988	41	F	D2-3	11 years	Progressive paraparesis, bladder dysfunction	CT, MRI	Biopsy	Unchanged
Cosgrove et al. 1988	48	M	D11-12	5 years	Progressive paraparesis	CT, MRI	Biopsy	Increased paraparesis
McCormick et al. 1988	24	F	D7-8	14 years	Progressive monoparesis, sensory deficit	Myelography, MRI	Complete	Improved
McCormick et al. 1988	52	M	D4	18 months	Progressive Brown-Séquard	Myelography, CT, MRI	Complete	Temporarily worse
McCormick et al. 1988	15	M	D8-9	2 weeks	Rapidly developing paraplegia	MRI	Complete	Unchanged
McCormick et al. 1988	37	F	C1	8 months	Step-wise progressive tetraplegia	MRI	Complete	Improved
McCormick et al. 1988	19	M	D4	3 years	Step-wise progressive paraparesis + sensory deficit + bladder dysfunction	Myelography, MRI	Complete	Improved
McCormick et al. 1988	51	M	D9	25 years	Step-wise paraparesis, "multiple sclerosis"	Myelography, MRI	Complete	Improved
Rutka et al. 1988	30	M	D1-2	6 months	Progressive paraplegia	Myelography	Complete	Improved
Villani et al. 1989	22	F	D8	3 months	Progressive paraparesis while pregnant	MRI	Complete	Good
Villani et al. 1989	28	M	D10-11	1 year	Progressive paraparesis	Myelography, MRI	Complete	Improved
Villani et al. 1989	65	F	C3	1 year	Progressive paraparesis	Myelography, MRI	Complete	Improved
Saito et al. 1989	45	F	C1	7 months	Trigeminal neuralgia, mild hemiparesis	MRI	Complete	Improved
Zentner et al. 1989	52	M	D5-6	14 years	Step-wise progressive paraparesis + bladder dysfunction	MRI	Complete	Temporarily worse
Zentner et al. 1989	22	F	C3	4 years	Step-wise progressive tetraparesis	Myelography, MRI	Complete	Temporarily worse
Barnwell et al. 1990	37	M	D6-7	3 years	Progressive Brown-Séquard	MRI	Complete	Stable
Ramos et al. 1990	67	F	L3	3 months	Progressive normal pressure hydrocephalus	CT, Myelography	Complete	Normal
Present case 1	32	F	C6-7	3 years	Step-wise progressive Brown-Séquard	Repeated MRI	Complete	Improved
Present case 2	35	F	C2		Acute tetraparesis	MRI	Complete	Improved



**Fig. 1a-h.** Case 1. **a** Initial MRI after spinal cord haemorrhage, July 1987. **b** MRI 3 months after the initial haemorrhage, patient at this time neurologically intact (TR SE 1000/TE 30). **c** Recurrent haemorrhage, October 1988 (300/30). **d** Recurrent haemorrhage, October 1989, incomplete improvement (477/30). **e, f** Recurrent haemorrhage, May 1990, incomplete improvement (2800/80). **g, h** Recurrent haemorrhage, July 1990



**Fig. 2a-c.** Case 2. MRI performed 15 h after the initial clinical manifestation of the bleeding. **a** Sagittal T1-weighted image shows the typical mixed appearance of the cavernoma with haemorrhage in the dorsal part of the spinal cord at C2; aedema extends upwards to the pons as well as downward for one segment. **b** Sagittal T2-weighted multi-echo/gradient echo image. **c** Horizontal image through the maximum extension of the cavernoma

tasl diameter of the spinal cord (Fig. 1e, f). The patient's neurological deficit remained unchanged (minor paresis of flexion and extension of her left fingers, increase of her leg jerks, hypaesthesia in the dermatome C8 left).

Two months later, another episode of intramedullary bleeding occurred. This time, the motor deficit progressed, and a dissociated sensory deficit below D6 in the right and D12 in the left lower extremities developed. While on dexamethasone, she developed spastic-atactic gait to the point that she was not able to walk on her own, and had urinary incontinence. This time, MRI (Fig. 1g, h) showed a major haemorrhage in her cervical medulla extending over the major part of the coronal diameter and, in the sagittal projection, nearly completely in the left part of the medulla. At this time, the patient agreed to surgery, and she was referred to our department. At surgery, laminotomy from C4 to D1 was performed; under the microscope, the dura was opened longitudinally, and the arachnoid membrane was dissected. Between the exit of the left dorsal roots of C7-8, a red-yellowish mass appeared under the pial layer. Bipolar coagulation and incision led to the intramedullary cavity of haemorrhages of various age which was evacuated, and a mulberry-shaped tumour of about 1 cm length was removed. Histological examination confirmed the MRI diagnosis of cavernous angioma. Her postoperative course was uneventful; her neurological deficit slowly improved over the ensuing 4 months.

### Case 2

This 35-year-old female suffered from acute onset of radicular pain in the neck, increasing over the day and followed by nausea and vomiting, as well as a tingling sensation in the right arm and leg. Upon admission in an other hospital, she had only a slight right-sided hemiparesis; her cranial nerves were normal. Lumbar puncture revealed no abnormality. Cranial computed tomography was normal. A few hours after admission, she developed right-sided hemiparesis and paraesthesias as well as a weakness in her left hand. Sensory deficit was below D1 on the right and D3 on the left. There was urinary incontinence. MRI (Fig. 2a-c) showed a lesion suggestive of a cavernous angioma at the level of C2 with recent haemorrhage; an intramedullary area of decreased signal intensity in T1-weighted image extended up to the pons suggestive of haemosiderin deposits. It should be noted that she had never presented with any clinical episode suggestive of previous haemorrhage.

After a few days on dexamethasone, a cavernoma was removed in a fashion similarly to the one described above. The postoperative neurological status showed steady improvement to the point

that she became able to walk with help, 2 weeks after surgery, and became essentially neurologically normal within 4-months.

## Discussion

### Incidence

The true incidence of spinal cavernous angiomas is unknown. As can be seen in Table 1, the number of reported surgical series since the first surgical treatment in 1912 until 1985 is very small, in addition to a few autopsy reports of partially ante mortem undiagnosed disease [10, 16, 19, 32, 38]. Krayenbühl and Yasargil [14] reported only a single cavernoma in a series of 568 spinal tumours seen over a period of 25 years, representing 4.3% of their intradural angiomas. Pia and Djindjian [22] reported 2 spinal cavernomas (3% of their spinal intradural arteriovenous malformations). McCormick and Nofzinger [18] described 1 cervical cavernoma in an autopsy series of 48 "cryptic" vascular malformations; reviewing the literature, they found 18 spinal "cryptic" vascular malformations among 308 located in the central nervous system, and approximately 31% of the intracranial "cryptic" vascular malformations were cavernomas [17]. Recently, a report from the New York Neurological Institute [19] stated that spinal cavernomas represented 5.1% of the intramedullary tumours treated at this institution between 1980 and 1987. Owing to refinement of diagnostic procedures, particularly to the application of MRI to diseases of the spinal cord, intraspinal cavernomas are diagnosed now with increasing frequency, so that a re-appraisal of diagnostic steps and therapeutic options should be considered.

### Clinical presentation

The natural history of central nervous system cavernomas with regard to the frequency of clinically distinguishable haemorrhage has been uncertain, although essentially all histologically examined cases showed evidence of haemorrhage.

morrhage [31]. Spinal cavernomas present clinically in the way already described by Schultze [30] in 1912; painful attacks may be followed by neurological deficits, frequently in the way of Brown-Séquard paresis [2, 5, 19, 30]; as in our own case 1). The neurological deficit may resolve at least partially while under corticosteroids. Step-wise progression of conservatively treated disease may lead to paraparesis and sensory deficits with or without bladder/bowel dysfunction. The clinical course of spinal cavernomas resembles, frequently, that of multiple sclerosis. This diagnosis has previously often been made in these patients [19, 29] until a mass effect by enlarging cavernomas led to myelographic appearance of the lesion [5, 9, 19]. The clinical differential diagnosis of this slowly progressive disease further includes other vascular disease of the spinal canal such as Foix-Alajouanine's disease [1, 7]. This clinical course may take from 1 week to 25 years (most frequently 2–4 years) until the diagnosis is established. Occasionally, sudden onset of a massive deficit may lead to early diagnosis (our case 2). If the cavernoma is located on the surface of the spinal cord or the bleeding breaks through the pial layer, it may present as subarachnoid haemorrhage [11, 34]; rarely, its presentation is that of a spinal tumour causing hydrocephalus [24].

The summary of published cases shows a female preponderance (1.8:1) and a maximum age of onset of symptoms in the early twenties to thirties.

#### *Diagnostic procedures*

The first successfully operated case was diagnosed only clinically [30]; over the next 70 years, myelography was often misleadingly normal and usually only helpful [4, 5, 9, 19, 21] after several bleeding episodes had occurred – leading to a mass effect of the cavernoma with its surrounding haematoma. MRI nowadays is the first diagnostic tool for suspected lesions of the spinal cord. The MRI appearance of intracranial cavernous angiomas has recently been well described [12, 15, 25, 27], and its characteristics also apply to the cavernomas in the spinal cord [2, 5]. On T2-weighted images, most frequently mixed signal intensity lesions are seen with a reticulated appearance and a prominent surrounding rim of decreased signal intensity (see Figs. 1, 2). While this central portion is thought to reflect the presence of methaemoglobin, the surrounding low intensity rim represents haemosiderin deposits, indicating previous haemorrhages. T1-weighted images are less sensitive for the detection of cavernomas. Smaller lesions may appear only as signal hypointensity or mixed signal intensity (Fig. 1). However, it should be remembered that the MRI appearance of cavernomas is non-specific and may also be present in other types of cryptic vascular malformations of the central nervous system with histological evidence of previous haemorrhage and even in small haemorrhagic tumours. In the patients presented here, the diagnosis of an intramedullary bleeding from a cryptic vascular malformation was clear, based on the MRI findings. Although in case 1 the cavernoma itself which was removed at surgery had not increased in size when compared with the

lesion initially detected 3 years previously, the mass effect due to haematoma formation had remarkably increased; growth of cerebral cavernomas due to haematoma and capsule formation has been previously reported [23] and may also be responsible for the eventual detection by repeatedly performed myelography [4, 5, 9, 19, 21].

In case 2, MRI performed immediately following the dramatic onset of tetraparesis showed the irregularly shaped lesion at the level of C2, as well as the surrounding high-intensity signal extending up to the pons, suggestive of central haemosiderin deposits; this strongly suggests previous silent haemorrhages.

#### *Therapy*

Most of the previously reported case have been characterized by a step-wise progression of the neurological deficit, and myelography performed after the initial events frequently has been unable to show any lesion. This meant that worsening of the neurological status had to be followed without a means of intervening surgically. However, our case 1 shows on MRI, for the first time, a close correlation of the clinical progression of the neurological deficit and the expanding nature of the lesion, due to recurrent haemorrhages. This case may serve as a particularly impressive example to demonstrate the natural history of the disease, and it should help to clarify the therapeutic options.

Conservative therapy was only of temporary benefit, as in many reported cases, and was unable to stop the progression of the neurological deficit. Only surgical removal of the cavernoma offers a way to stop progression and to reduce the neurological deficit. Of the reported 31 cases, 17 were reported improved following removal of the cavernoma, and 8 remained unchanged. Only 5 patients were reportedly permanently worse postoperatively, and 2 of them had undergone only incomplete removal of the lesion. Surgical removal of the cavernomas was thought to be complete in both cases presented here, because pathological vascular structures were clearly demarcated from surrounding spinal cord tissue by haemosiderin laden glial scar tissue. MRI scans were not performed in the early postoperative course and should be considered for later follow-up studies in order to prove the absence of abnormal vascular structures (suggestive of residual vascular malformation) within the glial scar.

The usual approach to the spinal cord is posterior or posterolateral laminotomy or laminectomy or hemilaminectomy. Laminotomy with re-insertion of the temporarily removed posterior segments of the vertebral arches (important particularly in young patients to prevent late sequelae of laminectomy) has been performed in both cases presented here. While one might have questioned, in the early phase of case 1, the possibility of complete removal of an anteriorly located cavernoma, the anterior approach to the spinal cord should also be considered possible nowadays with the use of temporary spondylectomy and microsurgical techniques, similarly to microsurgical removal of cavernomas in other regions such as the brain stem [6, 20, 40].

### Final comments

Multicentricity and familial occurrence of cavernomas have been reported. In 16–50% of patients who become symptomatic because of intracranial cavernomas, additional cavernomas of the central nervous system or elsewhere have been detected [8, 12, 25, 39]. The familial occurrence of cavernomas and the familial association with other vascular abnormalities also has been noted upon several occasions [4, 25–27, 29], and its true importance should become clear with more widespread application of MRI diagnostics. Then, the question will arise whether asymptomatic cavernomas should be considered for removal.

### Conclusion

Acute painful spinal cord neurological deficit, particularly in a young female patient, should be suggestive of intramedullary haemorrhage and be diagnosed immediately by MRI. The typical appearance of cavernoma on T2-weighted images is that of mixed increased signal intensity in the centre and low-intensity rim suggestive of previous silent haemorrhages. Surgical removal of the cavernoma should be the treatment of choice in order to stop the natural course of the disease which is characterized by repeated haemorrhages and step-wise progression of the deficit.

*Acknowledgements.* Professors/Drs. Felix (Berlin), Hornung, Kühne, Blümm (Essen) supplied the MRI scans of case 1; Professor Hebestreit (Lüdenscheidt) the MRI scans of case 2. Drs. Urban, Tenfelde and Gallenkamp kindly referred the patients for therapy.

### References

1. Ansari F (1965) Hämatomyelie bei arteriovenösem Angiom des Rückenmarks. Ein Beitrag zur Pathogenese der Foix-Alajouanine'schen Krankheit. *Beitr Pathol Anat* 131:137–161
2. Barnwell SL, Dowd CF, Davis RL, Edwards MSB, Gutin PH, Wilson CB (1990) Cryptic vascular malformations of the spinal cord: diagnosis by magnetic resonance imaging and outcome after surgery. *J Neurosurg* 72:403–407
3. Bergstrand A, Höök O, Lidvall H (1964) Vascular malformations of the spinal cord. *Acta Neurol Scand* 40:169–183
4. Bicknell JM, Carlow TJ, Kornfeld M, Stovring J, Turner P (1978) Familial cavernous angiomas. *Arch Neurol* 35:746–749
5. Cosgrove GR, Bertrand G, Fontaine S, Robitaille Y, Melanson D (1988) Cavernous angiomas of the spinal cord. *J Neurosurg* 68:31–36
6. Fahlbusch R, Strauss C, Huk W, Röckelein G, Kömpf D, Ruprecht KW (1990) Surgical removal of pontomesencephalic cavernous hemangiomas. *Neurosurgery* 26:449–457
7. Foix C, Alajouanine T (1926) La myélite nécrotique subaigue. *Rev Neurol (Paris)* II:1–42
8. Giombini S, Morello G (1978) Cavernous angiomas of the brain: account of fourteen personal cases and review of the literature. *Acta Neurochir (Wien)* 40:61–82
9. Goran A, Carlson DJ, Fisher FG (1964) Successful treatment of intramedullary angioma of the cord. *J Neurosurg* 21:311–314
10. Hadlich R (1903) Ein Fall von Tumor cavernosus des Rückenmarks mit besonderer Berücksichtigung der neueren Theorien über die Genese des Cavernoms. *Virchows Arch [A]* 172:429–441
11. Heimberger K, Schnabert G, Koos W, Pendl G, Auff E (1982) Spinal cavernous haemangioma (intradural-extramedullary) underlying repeated subarachnoid haemorrhage. *J Neurol* 226:289–293
12. Imakita S, Nishimura T, Yamada N, Naito HG, Takamiya M, Yamada Y, Kikuchi H, Yonekawa Y, Sawada T, Yamaguchi T (1989) Cerebral vascular malformations: applications of magnetic resonance imaging to differential diagnosis. *Neuroradiology* 31:320–325
13. Kitahara T, Miyasaka Y, Ohwada T, Yada K, Mera H (1982) An operated case of cervical spontaneous hematomyelia. *Neurol Surg* 10:675–679
14. Krayenbühl H, Yasargil MG (1963) Die Varikosis spinalis und ihre Bedeutung. *Schweiz Arch Neurol Psychiatr* 92:74–92
15. Lemme-Plaghos L, Kucharzycyk W, Brandt-Zawatzki M, Uske A, Edwards M, Norman D, Newton TH (1986) MR imaging of angiographically occult vascular malformations. *AJNR* 7:217–222
16. Lindboe CF, Nordal HJ (1985) Multiple neurilemmoma of the cauda equina, cavernous hemangioma of the spinal cord and degeneration of the lateral corticospinal tracts in a man with the clinical diagnosis of multiple sclerosis. *Clin Neuropathol* 4:260–264
17. Lobato RD, Perez C, Rivas JJ, Cordobes F (1988) Clinical, radiological and pathological spectrum of angiographically occult intracranial vascular malformations. Analysis of 21 cases and review of the literature. *J Neurosurg* 68:518–531
18. McCormick WF, Nofzinger JD (1966) "Cryptic" vascular malformations of the central nervous system. *J Neurosurg* 24:865–875
19. McCormick PC, Michelsen WJ, Post KD, Carmel PW, Stein BM (1988) Cavernous malformations of the spinal cord. *Neurosurgery* 23:459–463
20. Ondra SL, Doty JR, Mahla ME (1988) Surgical excision of a cavernous hemangioma of the rostral brain stem. Case report. *Neurosurgery* 23:490–493
21. Ortner WD, Kubin H, Pilz P (1973) Ein zervikales kavernöses Angiom. *Fortschr Roentgenstr* 118:475–476
22. Pia HW, Djindjian R (eds) (1978) Spinal angiomas: advances in diagnosis and therapy. Springer, New York Berlin Heidelberg
23. Pozzati E, Giuliani G, Nuzzo G, Poppi M (1989) The growth of cerebral cavernous angiomas. *Neurosurgery* 25:92–96
24. Ramos F Jr, Toffol B de, Jan M (1990) Hydrocephalus and cavernoma of the cauda equina. *Neurosurgery* 27:139–142
25. Rigamonti D, Drayer B, Johnson PC, Hadley MN, Zabramski J, Spetzler RF (1987) The MRI appearance of cavernous malformations (angiomas). *J Neurosurg* 67:518–524
26. Rigamonti D, Hadley MN, Drayer BP, Johnson PC, Hoenig-Rigamonti K, Knight JT, Spetzler RF (1988) Cerebral cavernous malformations: incidence and familial occurrence. *N Engl J Med* 319:343–347
27. Rutka JT, Brant-Zawatzki M, Wilson CB (1988) Familial cavernous malformations. Diagnostic potential of magnetic resonance imaging. *Surg Neurol* 29:467–474
28. Saito N, Yamakawa K, Sasaki T, Saito I, Takakura K (1989) Intramedullary cavernous angioma with trigeminal neuralgia: a case report and review of the literature. *Neurosurgery* 25:97–101
29. Schröder JM, Brunngraber CV (1964) Über ein intramedulläres cavernöses Angiom. *Acta Neurochir (Wien)* 12:632–641
30. Schultze F (1912) Weiterer Beitrag zur Diagnose und operativen Behandlung von Geschwülsten der Rückenmarkshäute und des Rückenmarks. Erfolgreiche Operation eines intramedullären Tumors. *Dtsch Med Wochenschr* 36:1676–1679
31. Simard JM, Garcia-Bengochea F, Ballinger WE, Mickle JP, Quisling RG (1986) Cavernous angioma: a review of 126 collected and 12 new clinical cases. *Neurosurgery* 18:162–172
32. Turner OA, Kernohan JW (1949) Vascular malformations and vascular tumors involving the spinal cord. A pathological study of 46 cases. *Arch Neurol Psychiatr* 46:444–463

33. Tyndel FJ, Bilboa JM, Hudson AR, Colapinto EV (1985) Hemangioma calcificans of the spinal cord. *Can J Neurol Sci* 12:321–323
34. Ueda S, Saito AA, Inomori S, Kim I (1987) Cavernous angioma of the cauda equina producing subarachnoid hemorrhage: case report. *J Neurosurg* 66:134–136
35. Vaquero J, Martinez R, Martinez P (1988) Cavernomas of the spinal cord: report of two cases. *Neurosurgery* 22:143–144
36. Vaquero J, Salazar J, Martinez R, Martinez P, Bravo G (1987) Cavernomas of the central nervous system: clinical syndromes, CT-diagnosis and prognosis after surgical treatment in 25 cases. *Acta Neurochir (Wien)* 85:29–33
37. Villani RM, Arienta C, Caroli M (1989) Cavernous angiomas of the central nervous system. *J Neurol Sci* 33:229–252
38. Vraa Jensen G (1949) Angioma of the spinal cord. *Acta Psychiatr Neurol Scand* 24:709–721
39. Wood MW, White RJ, Kernohan JW (1957) Cavernous hemangiomas involving the brain, spinal cord, heart, skin and kidney: report of case. *Proc Staff Meet Mayo Clin* 32:249–254
40. Yoshimoto T, Suzuki J (1986) Radical surgery on cavernous angiomas of the brainstem. *Surg Neurol* 26:72–78
41. Zentner J, Hassler W, Gawehn J, Schroth G (1989) Intramedullary cavernous angiomas. *Surg Neurol* 31:64–68