

Stroke

Unipolar and continuous cortical stimulation to enhance motor and language deficit in patients with chronic stroke: report of 2 cases

Hyoung-Ihl Kim, MD^{a,*}, Yong-Il Shin, MD^b, Seong-Keun Moon, MD^c, Gyung-Ho Chung, MD^d,
Min-Cheol Lee, MD^f, Hyun-Gi Kim, PhD^e

^aDepartment of Neurosurgery, Presbyterian Medical Center, Jeonju 560-750, Republic of Korea

Departments of ^bRehabilitation Medicine, and ^cNeurosurgery, Wonkwang University School of Medicine, Iksan 570-711, Republic of Korea

Departments of ^dDiagnostic Imaging, and ^eClinical Speech Pathology, Chonbuk National University and Hospital, Jeonju 561-712, Republic of Korea

^fDepartment of Neuropathology, Chonnam University Medical School, Gwangju 501-746, Republic of Korea

Received 17 November 2006; accepted 20 December 2006

Abstract

Background: Stroke often leads to permanent neurological deficit despite extensive therapeutic and rehabilitative efforts; and in chronic stages, it is difficult to restore neurological function. Recently, bipolar and intermittent cortical stimulation combined with rehabilitation has been reported to be effective in chronic hemiparetic stroke. However, optimal parameters of cortical stimulation for chronic stroke have not been determined to restore neurological function in chronic stages of stroke.

Case descriptions: We report 2 cases of chronic stroke whose neurological functions were improved by continuous, unipolar cortical stimulation combined with rehabilitation. Patient 1 presented motor and language deficit associated with cortical infarct in the left middle cerebral artery territory, which occurred 18 months before admission. Patient 2 presented motor deficit associated with subcortical infarct in the internal capsule 8 months before admission. Unipolar electrodes were implanted epidurally to cover the contralateral premotor and motor cortex in both cases, and an additional electrode was implanted over the Broca area in patient 1. Follow-up evaluation after 4 months of stimulation and concurrent rehabilitation showed improvement of Fugl-Meyer and FIM scores in both patients, and of speech and articulation in patient 1, whose electrode covered the Broca area. No adverse effects were observed during the period of treatment.

Conclusion: Unipolar and continuous cortical stimulation with rehabilitation is beneficial for improving neurological deficit in selected cases of chronic stroke.

© 2008 Elsevier Inc. All rights reserved.

Keywords:

Stroke; Electrical stimulation; Cortex; Motor; Language

1. Introduction

Stroke is a disastrous event that often leads to mortality and disability despite advances in therapeutic methods. Recent experimental studies indicate that electrical stimulation of the motor cortex might be useful

in augmenting recovery from motor dysfunction in stroke patients [1,7,13,14]. Although the exact mechanisms by which this treatment improves motor deficits is not fully understood, adaptive plasticity mediated by rehabilitation and electrical stimulation is thought to activate functional residual neuronal connections (plastic cortex) to compensate for the neurological loss [12]. Seven cases have been recently reported where bipolar and intermittent cortical stimulation, administered in patients with chronic stroke, led to reasonable improvement in motor function [2,3].

We herein report 2 cases of UCCS to improve motor and language function in chronic stroke patients.

Abbreviations: FIM, Functional Independence Measure; fMRI, functional magnetic resonance imaging; MRI, magnetic resonance imaging; UCCS, unipolar and continuous cortex stimulation.

* Corresponding author. Tel.: +82 063 230 8264; fax: +82 063 285 9573.

E-mail address: hyoungihl@hotmail.com (H.-I. Kim).

2. Case 1

A 39-year-old female patient presented an 18-month history of motor deficit in the right side, aphasia, and severe dysarthria. She was diagnosed with cortical infarct in the middle cerebral artery territory on her initial MRI examination (Fig. 1A), with progressive improvement of her neurological symptoms; yet neurological deficits still persisted. Arm Fugl-Meyer score was 8/66 and FIM was 96/126. She had marked limitation of speech (articulation error rate, 45%) and severe aphasia (not testable). The fMRI during a flexion-extension task of the right hand showed activation of motor cortex in both sides; but activation of the left motor cortex moved anterosuperiorly, compared with that of the right motor cortex (Fig. 1B). Two 4 × 4 cm-sized paddle electrodes (Oscor, Palm Harbor, Fla) were epidurally implanted through craniotomy opening to cover the upper portion of motor and premotor cortex corresponding to the activation area in fMRI and the Broca area after motor mapping (Fig. 1C). Epidural electrodes were fixed to the dura by securing 3 anchoring holes in the corners, leaving no dead space between the dura and the paddle electrode. Electrode leads were subcutaneously tunneled to the anterior chest area where an implantable pulse generator was connected. Unipolar and continuous cortex stimulation was given at 1 V, for 200 μs of pulse duration, at 50 Hz a week after the surgery. The amplitude was progressively increased to 5 V over 4 weeks. At the same time, the patient was encouraged to undergo active rehabilitation training for 2 hours every day. Follow-up examination after 4 months of treatment showed improved motor and language performance. The Fugl-Meyer score had improved from preoperative value of 8 to 27/66. The FIM score was improved from 96 to 117/126, especially in the subscales of self-care, mobility, locomotion, and communication. An articulation screening test revealed improved visual response times for

picture words stimuli (from 13.70 to 2.97 sec) and articulation error rate (from 45% to 59%). Z scores of aphasia evaluation were markedly improved for recognition of common nouns. In addition, the patient showed improvement in stability and walking gestures. During the course of UCCS, the patient showed no adverse effects.

3. Case 2

This 51-year-old male patient showed motor deficit in the left side, which had persisted for the last 8 months. Eight months before admission, he had small subcortical infarct in the internal capsule with subsequent motor deficit and spasticity in right extremities (Fig. 2A). Finger extension and flexion were incompletely active in the affected hand, with a moderately spastic arm. His walking was unsteady and he fell down easily even with a cane. The fMRI of flexion-extension of the right and left hands showed activation of left motor cortex; however, activation of right motor cortex was not observed (Fig. 2B1 and B2). Despite unclear guidance of fMRI, a paddle electrode was implanted to cover the upper portion of premotor and motor cortex in the right side after motor mapping (Fig. 2C). The UCCS and rehabilitation were applied likewise in case 1. Follow-up examination after 4 months of UCCS demonstrated that arm Fugl-Meyer was improved from 35 to 42/66 and that FIM score was improved from 82 to 95/126 in the subscales of self-care, mobility, and locomotion. In addition, gait was markedly improved with no need for the assistance of a cane or caregiver. He is currently able to drive a nonhandicapped car.

4. Discussion

Described are 2 cases of patients who have had a stroke and whose neurological deficits were improved by UCCS

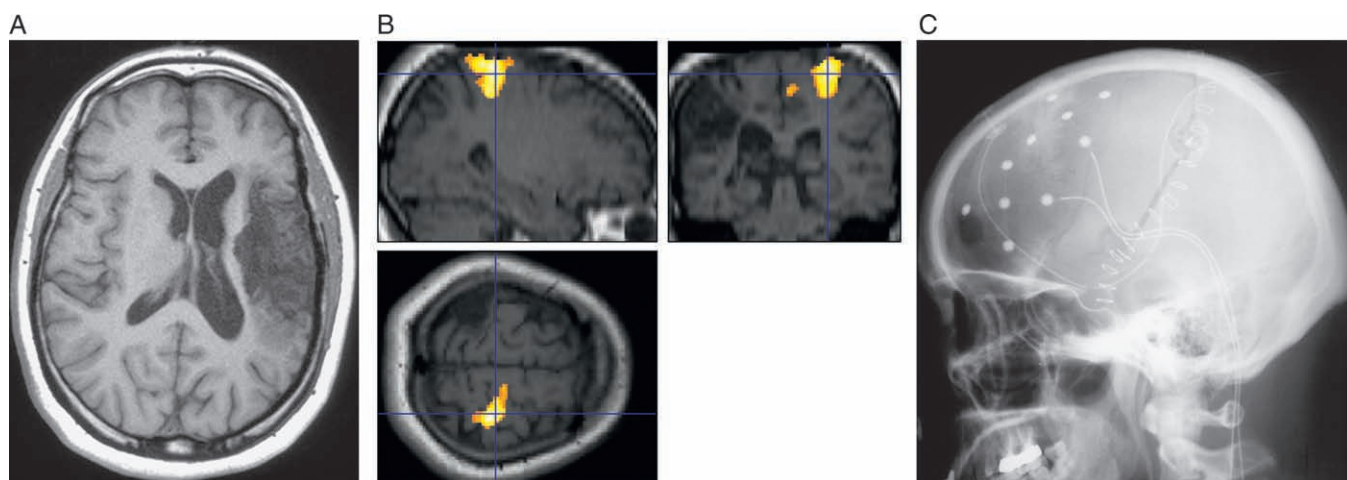
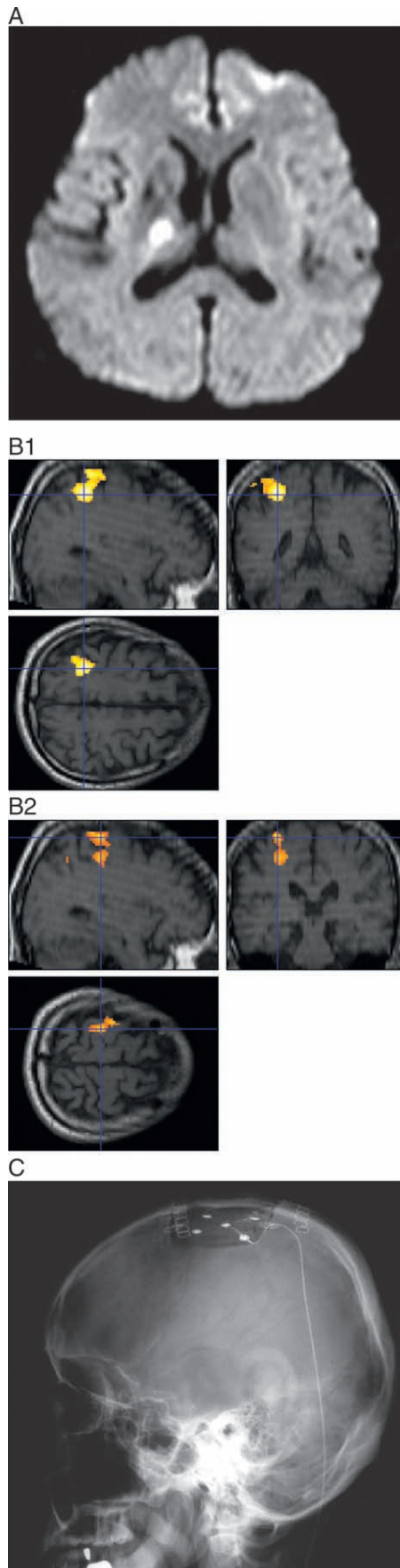


Fig. 1. A: T1-weighted axial view of MRI demonstrates cortical infarct including motor-sensory cortex and lentiform nucleus insular cortex but sparing caudate nucleus. B: The fMRI of flexion-extension task of right hand showed activation of motor cortex in both sides; yet activation of left motor cortex moved anteriorly and superiorly, compared with activation of right motor cortex. C: Postoperative lateral skull view shows the implantation of 2 paddle electrodes covering premotor-motor cortex area and Broca area.



and rehabilitative training. Both patients showed improvement of motor function, whereas one patient also showed improvement in language function. Interestingly, patients responded to this type of therapy regardless of the location of infarct, cortical or subcortical. It is surprising to note that language function was also improved with UCCS and speech training. The patient could communicate comfortably with other people after treatment. This finding suggests that language deficit after stroke can be improved with similar combination of therapy.

Neurological deficit after stroke gradually improves with modern therapeutic regimes. This recovery has been attributed to functional reorganization and recruitment of plastic cortex previously not engaged in a given task [12]. However, neurological recovery stops beyond the critical time of recovery depending on the severity of infarct. In line with the trial of Brown et al [3], we tried to improve neurological deficits in patients whose neurological symptoms were fixed for more than 6 months; and it was surprising to note that cortical stimulation still acted on reorganization of functional zones even 18 months after the stroke.

We used anodal and unipolar stimulation techniques that have been used successfully in animal experiments [7]. Such stimulation may affect corticofugal projections in the cortical and subcortical levels [5,9]. Modern anatomical studies have shown that the pyramidal tract is formed by many corticofugal systems and that the corticospinal component of the pyramidal tract originates from a widespread portion of the cortex. For example, several arm presentations are found not only in motor cortex but also in subcortical structures including the brainstem reticular formation, the red nucleus, and pontine gray matter [4,8,10,11]. Kleim et al showed that both unipolar and bipolar stimulation enhanced motor recovery in comparison to control infarct models. However, unipolar stimulation was more effective at improving motor performance [7], suggesting that unipolar stimulation may alter not only cortical function in peri-infarct area, but also influence the subcortical structures responsible for motor performance. This might be attributable to the depth into which the electric force is exerted by unipolar stimulation, which affects a deeper region of the cortex than that stimulated by bipolar method. Interestingly, although the paddle electrode was applied mainly at the wrist-hand area, we observed postural improvements such as walking stability and balance. Unipolar stimulation is thought to create an

Fig. 2. A: Diffusion-weighted imaging of MRI performed 8 months before implantation of electrode shows the subcortical infarct involving posterior limb of internal capsule. B1 and B2: The fMRI of flexion-extension task of right and left hand showed activation of left motor cortex; however, activation of right motor cortex was not observed. C: Postoperative lateral skull view shows the implantation of a paddle electrode covering premotor and motor cortex.

electrical field in the deeper “leg representation area” in the interhemispheric fissure.

Brown et al recommended fMRI to choose the targets for implanting electrodes [3]. However, in our cases, it was confusing to select the targets based on the results of fMRI. Although fMRI provided “localizing” information for paddle placement in the first case, it could not provide “lateralizing” information in either case. We rather chose the contralateral motor cortex as target of UCCS because motor cortex of the contralateral hemisphere has been demonstrated to play a facilitatory role in motor recovery [6]. Additional studies are required to settle the debates in selecting targets. In summary, this report supports the hypothesis that UCCS combined with rehabilitation is a potential method to improve motor and language function in late chronic stage stroke patients.

Acknowledgments

This study was supported by Wonkwang University grant in 2006.

References

- [1] Adkins-Muir DL, Jones TA. Cortical electrical stimulation combined with rehabilitative training: enhanced functional recovery and dendritic plasticity following focal cortical ischemia in rats. *Neurol Res* 2003;25:780-8.
- [2] Brown JA, Lutsep H, Cramer SC, et al. Motor cortex stimulation for enhancement of recovery after stroke: case report. *Neurol Res* 2003; 25:815-8.
- [3] Brown JA, Lutsep HL, Weinand M, et al. Motor cortex stimulation for the enhancement of recovery from stroke: a prospective, multicenter safety study. *Neurosurgery* 2006;58:464-73.
- [4] Burman K, Darin-Smith C, Darin-Smith I. Macaque red nucleus: origin of spinal and olivary projections and terminations of cortical inputs. *J Comp Neurol* 2000;423:176-96.
- [5] Garcia-Larrea L, Peyron R, Metens P, et al. Electrical stimulation of motor cortex for pain control: a combined PET-scan and electrophysiological study. *Pain* 1999;83:259-73.
- [6] Gerloff C, Bushara K, Sailer A, et al. Multimodal imaging of brain reorganization in motor areas of the contralesional hemisphere of well recovered patients after capsular stroke. *Brain* 2006;129:791-808.
- [7] Kleim JA, Bruneau R, VandenBerg P, et al. Motor cortex stimulation enhances motor recovery and reduces peri-infarct dysfunction following ischemic insult. *Neurol Res* 2003;25:789-93.
- [8] Luppino G, Rizzolatti G. The organization of the frontal motor cortex. *New Physiol Sci* 2000;15:219-24.
- [9] Marshall RS, Pertera GM, Lazar RM, et al. Evolution of cortical activation during recovery from corticospinal tract infarction. *Stroke* 2000;31:656-61.
- [10] Morecraft RJ, Herrick JL, Stilwell-Morecraft KS, et al. Localization of arm presentation in the corona radiata and internal capsule in the non-human primate. *Brain* 2002;125:176-98.
- [11] Nudo RJ, Masterton RB. Descending pathways to the spinal cord, III. Site of origin of the corticospinal tract. *J Comp Neurol* 1990;296: 559-83.
- [12] Nudo RJ, Plautz EJ, Frost SB. Role of adaptive plasticity in recovery of function after damage to motor cortex. *Muscle Nerve* 2001;24: 1000-19.
- [13] Plautz EJ, Barbay S, Frost SB, et al. Post-infarct cortical plasticity and behavioral recovery using concurrent cortical stimulation and rehabilitative training: a feasibility study in primates. *Neurol Res* 2003;25: 801-10.
- [14] Teskey GC, Flynn C, Goertzen CD, et al. Cortical stimulation improves skilled forelimb use following a focal ischemic infarct in the rat. *Neurol Res* 2003;25:794-800.

Commentary

Functional neurosurgeons and neurologists who treat patients with cerebral infarcts are expanding their ability to improve care for these patients who have often been subject to significant functional deficits. Cortical stimulation is one example of emerging applications that combine our improved understanding of neurophysiology/neuropathology with intracranial implants to affect common disease processes. These developments provide hope that with further safety and efficacy studies, certain stroke patients will have significantly improved clinical outcomes in the future.

Donald Charles Shields, MD, PhD
Department of Neurosurgery
UCLA School of Medicine
Los Angeles, CA 90095, USA