

Akinetic Mutism Responsive to Bromocriptine Following Subdural Hematoma Evacuation in a Patient With Hydrocephalus

—Case Report—

Myoung Soo KIM, Jong Joo RHEE, Seung Jun LEE, Seon-Joo KWON*,
and Chae Heuck LEE

Departments of Neurosurgery and *Neurology, Seoul Paik Hospital,
Inje University College of Medicine, Seoul, R.O.K.

Abstract

An 11-year-old girl with obstructive hydrocephalus developed akinetic mutism after treatment for hydrocephalus due to aqueductal stenosis by ventriculoperitoneal (VP) shunting. Bilateral chronic subdural hematomas developed about 2 months after insertion of the VP shunt and were evacuated. Postoperatively, the patient developed akinetic mutism, but her condition improved after administration of bromocriptine. Absence of abnormalities on dopamine transporter single photon emission computed tomography, lack of clinical response to levodopa treatment, and normal homovanillic acid concentration in the cerebrospinal fluid all indicated normal dopamine production. Pressure on the periventricular monoamine projections in the thalamus and hypothalamus without major dopamine deprivation in the striatum may have been the most important factors in the development of akinetic mutism in this patient.

Key words: akinetic mutism, hydrocephalus, bromocriptine

Introduction

Akinetic mutism is a state in which a seemingly awake patient remains motionless and silent, and is associated with lesions involving the ascending dopaminergic activating system. Akinetic mutism is typically a transient disorder following posterior fossa tumor resection, and may also occur after recurrent shunt failures in patients with hydrocephalus, who show no improvement either spontaneously or with shunt revisions but respond to bromocriptine.^{2,4,13,19,24} However, little is known about the state of dopamine production in the brain of patients with akinetic mutism.²⁰

We treated a patient with akinetic mutism caused by ventricular wall expansion and discuss the involvement of dopamine production.

Case Report

An 11-year-old girl presented with a 16-month histo-

ry of gait disturbance, memory disturbance, and learning difficulty. She was lethargic and had developed slurred speech and urinary incontinence. Computed tomography (CT) demonstrated obstructive hydrocephalus (Fig. 1). A ventriculoperitoneal (VP) shunt with a pressure-adjustable valve (Codman Medos programmable valve, Medos SA, Le Locle, Switzerland; opening pressure 100 mmH₂O) was inserted. Subsequently, the patient complained of intermittent headache. On day 51 after insertion of the VP shunt, she was lethargic and complained of severe headache. CT in the emergency department demonstrated a right subdural hematoma (SDH) (Fig. 2). Burr hole trephination was performed on the right. CT obtained 2 days postoperatively showed a left SDH (Fig. 3), and further burr hole trephination was performed on the left. CT performed after the burr hole trephinations showed that the SDHs had almost completely disappeared. After surgery, the patient remained awake, motionless, and mute, and she would move all extremities only

Received January 9, 2007; Accepted June 23, 2007

Author's present address: J. J. Rhee, M.D., Department of Neurosurgery, Cheongju Saint Mary's Hospital, Cheongju, R.O.K.

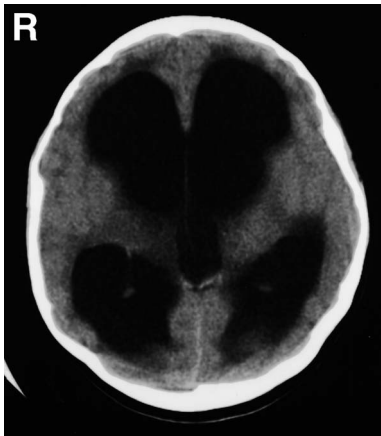


Fig. 1 Computed tomography scan obtained on first admission at another hospital demonstrating marked hydrocephalus.

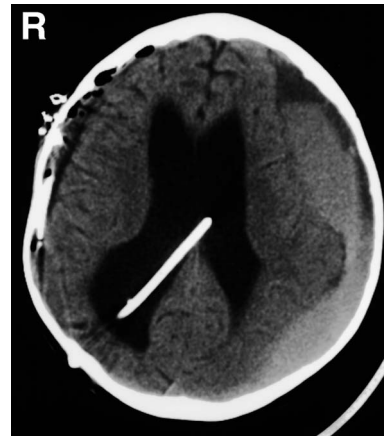

Fig. 3 Computed tomography scan obtained at follow-up examination 2 days after right burrhole trephination demonstrating left subdural hematoma.

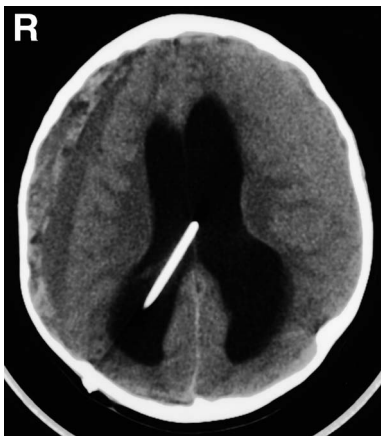

Fig. 2 Computed tomography scan obtained at follow-up examination 51 days after ventriculoperitoneal shunting showing right subdural hematoma.

in response to deep pain. The patient showed no improvement despite conservative treatment and adjustment of the shunt valve opening pressure from 100 to 140 mmH₂O on several occasions (i.e., from 100 to 120 mmH₂O, 120 to 140 mmH₂O, 140 to 130 mmH₂O, and 130 to 110 mmH₂O). She was referred to our department for evaluation and treatment 30 days after the left burr hole trephination.

Examination on admission revealed features consistent with akinetic mutism. She appeared to be awake but was almost completely unresponsive to her surroundings. She seldom responded to painful somatosensory, loud auditory, or threatening visual stimuli. Occasionally, she seemed to make spontaneous but weak attempts to move her extremities. She required complete tube feeding and total nursing

care. We found no signs of rigidity. The VP shunt functioned well, and the opening pressure of the shunt valve was 110 mmH₂O. Electroencephalography disclosed no epileptic discharge. Magnetic resonance (MR) imaging, including perfusion-weighted and diffusion-weighted MR imaging, showed no abnormal finding except for a small residual SDH and improved hydrocephalus (Fig. 4). ¹²³I-beta-fluoropropyl-2beta-carbomethoxy-3beta-(4-iodophenyl)tropane (¹²³I-FP-CIT)-single photon emission computed tomography (SPECT) demonstrated normal presynaptic dopamine reuptake in the bilateral putamens and caudate nuclei (Fig. 5). The concentration of homovanillic acid (HVA) in the cerebrospinal fluid was 67.86 ng/ml (normal range 1–73 ng/ml).

Treatment with Madopar © Rapid 125 Tablet (La Roche Ltd., Basel, Switzerland) (benserazide 25 mg, levodopa 100 mg) was begun on postoperative day 31 after the second burr hole operation, initially 31.25 mg/day and increasing gradually to 187.5 mg/day in three equal doses. Despite 12 days of Madopar treatment, her symptoms did not improve. We stopped the Madopar administration and began treatment with bromocriptine, initially 1.25 mg/day and increasing gradually to 50 mg/day in three equal doses. Two days after the initiation of bromocriptine administration, she began speaking words and responding to verbal stimuli. Twenty days after the initiation, she was speaking in full sentences and demonstrated no gait disturbance, although she had memory disturbance and learning difficulty. Treatment with trihexyphenidyl was begun on day 66 after the second burr hole operation, initially 2 mg/day and increasing gradually to 6 mg/day in

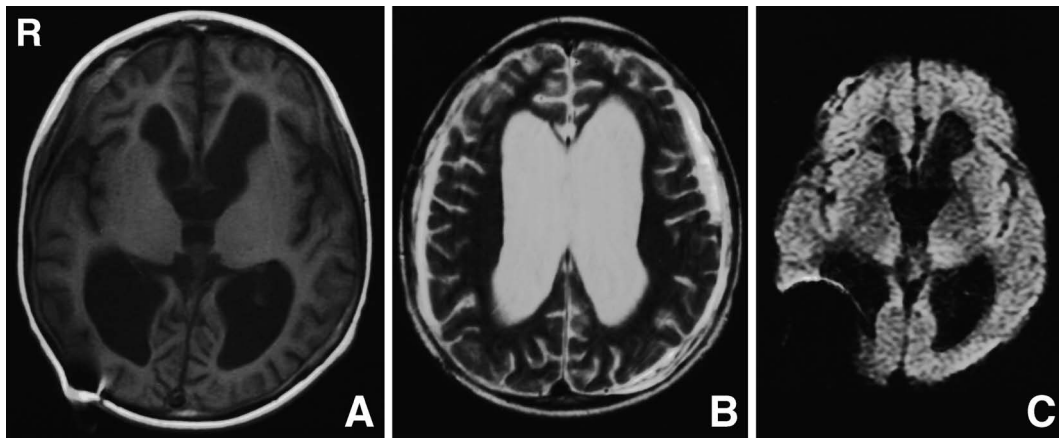


Fig. 4 Axial T₁-weighted (A), T₂-weighted (B), and diffusion-weighted (C) magnetic resonance images obtained at follow-up examination 26 days after burrhole trephination for the left subdural hematoma demonstrating improved hydrocephalus and residual subdural hematoma.

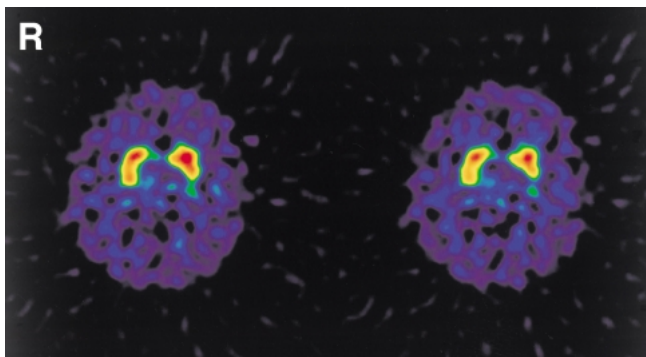


Fig. 5 ¹²³I-beta-fluoropropyl-2beta-carbomethoxy-3beta-(4-iodophenyl)tropane-single photon emission computed tomography images demonstrating normal presynaptic dopamine reuptake in the bilateral putamens and caudate nuclei.

three equal doses. We did not change the shunt valve opening pressure during adjustment of the drug dose. Seven months after the second burr hole operation, she had only slight residual dystonia of the body and mild memory disturbance. An attempt to decrease the dosage of bromocriptine 5 months after initiation because of dyskinesia failed, with rapid clinical deterioration including decreased spontaneous speech and motor activity. Return to the previous dosage of bromocriptine reversed the decline in symptoms.

Discussion

The clinical features of patients with akinetic mutism associated with hydrocephalus are listed in Table 1. Akinetic mutism can appear in different

forms, depending on its cerebellar or hydrocephalic origin. Injury of the mesiofrontal lobes is the most frequently reported cause of akinetic mutism. One patient had akinetic mutism caused by hemorrhagic infarction of both cingulate gyri,³⁾ and three patients had akinetic mutism caused by anterior cingulate lesions due to bilateral anterior cerebral artery infarctions.⁹⁾ Similar symptoms have been associated with anterior cingulate lesions.^{6,10,25)}

Animal studies and case reports have identified two primary lesion sites that may be associated with akinetic mutism: the mesencephalic-diencephalic reticular activating system, including the midbrain reticular formation, thalamus, and hypothalamus^{1,7,12)}; and the anterior cingulate gyrus and adjacent mesial frontal lobes. Lesions at these sites occur along pathways that originate in the mesencephalon and project widely to dopamine receptors in the spinal cord, brainstem, diencephalon, corpus striatum, and mesiofrontal lobe.^{8,18,24)} The diffuse nonspecific reticular activating system, which normally interacts with these specific projections as a coordinated unit, remains intact. The resultant behavioral abnormality causes the patient to remain awake but unable to initiate motor activity in response to sensory stimuli, that is a state of sensory inattention.

Pressure transmitted to the diencephalon from hydrocephalus or third ventricular tumors can cause akinetic mutism.^{2,4,17,24)} The underlying mechanism is believed to be damage to the periventricular monoamine projections in the thalamus and hypothalamus caused by expansion of the third ventricular wall.^{19,22)} The degree and duration of ventricular wall expansion required to injure the monoamine projection fibers remains unknown, but

Table 1 Summary of clinical features in patients with akinetic mutism following hydrocephalus (HD) treatment

Case No.	Author (Year)	Age (yrs)/ Sex	HD	Operation	Time of onset	Treatment
1	Berger et al. (1985) ⁴⁾	21/F	obstructive HD due to AS	multiple shunt operation due to shunt malfunction	after 3rd shunt operation	shunt revision, cogentin, DOPA/benserazide (prolopa)
2	Watahiki et al. (1987) ²⁴⁾	39/M	obstructive HD due to AS	multiple shunt operation due to shunt malfunction	after 3rd shunt operation	levodopa, bromocriptine, trihexyphenidyl
3	Anderson (1992) ²⁾	20/M	obstructive HD due to AS	multiple shunt operation due to shunt malfunction	after 4th shunt operation	bromocriptine, ephedrine
4	Lee et al. (2002) ¹³⁾	34/M	unilateral ventricle HD	multiple shunt operation due to shunt malfunction	after 3rd shunt operation	bromocriptine
5	Psarros et al. (2003) ¹⁹⁾	26/F	obstructive HD due to cystic mass	endoscopic exploration, cyst resection, septostomy	immediately after operation	bromocriptine

AS: aqueductal stenosis.

lesioning of these structures in animals induces akinetic mutism, which can be reversed with dopamine agonists.²³⁾ This observation forms the basis of dopamine agonist use in humans with akinetic mutism.²⁰⁾ A patient with akinetic mutism caused by hydrocephalus was treated successfully with levodopa, bromocriptine, and trihexyphenidyl.²⁴⁾ Another patient with akinetic mutism resulting from obstructive hydrocephalus was treated with bromocriptine and ephedrine.²⁾

The causative damage may be maximal in regions adjacent to the third ventricle.⁵⁾ This region contains monoaminergic projection fibers from the brain stem.^{21,23)} Akinetic mutism does not result from simple elevation of intracranial pressure,⁵⁾ which is consistent with clinical observations of patients with pseudotumor cerebri, who can experience pronounced elevation of intracranial pressure without becoming mute. Akinetic mutism also does not result from simple dilation of the cerebroventricular system. A review of previous cases revealed that the syndrome usually develops after multiple shunt revisions for shunt failure.^{4,16,24)} This observation suggests that the brain undergoes a series of stretching and contraction cycles, so the repeated cycles of ventricular dilation and relaxation may somehow alter the physical characteristics and result in more rapid dilation in response to increased intracerebral pressure, which exceeds the speed of compensatory mechanisms and results in damage.²⁾ Such stretching might occur in the midbrain structures or the nigrostriatal system, and might lead to dysregulation of this system without major dopamine deprivation through the midbrain

lesion, which affects the substantia nigra.²⁾

HVA concentration was normal in the cerebrospinal fluid of a patient with akinetic mutism caused by hypothalamic damage.²⁰⁾ However, the dopamine metabolism is unclear in patients with akinetic mutism resulting from hydrocephalus. Some patients with chronic hydrocephalus may experience decreased autoregulatory capacity for cerebral blood volume. In our patient, this mechanism was excluded by perfusion-weighted MR imaging, which revealed no perfusion changes.¹¹⁾ Our patient did not respond to Madopar, a presynaptic dopamine-mimetic drug, so we thought that the medial forebrain bundles were probably destroyed. Therefore, we decided to try treatment with direct dopamine agonists based on the results of animal experiments and a previous case report.^{14,15)}

In our patient, the clinical and pharmacologic evidence indicated that the lesion predominantly involved the periventricular monoamine projections in the thalamus and hypothalamus, more specifically the presynaptic dopamine axons coursing in the anterior portions of the medial forebrain bundles. The unresponsiveness of this patient to Madopar coupled with the initial response to low-dose dopamine agonists suggest that the presynaptic catecholaminergic mechanisms were inoperative. On the other hand, if our patient's lesion had involved the anterior cingulate gyri, she probably would not have responded to direct dopamine agonists because the dopamine receptor targets would have been destroyed.²⁰⁾ The absence of abnormalities on ¹²³I-FP-CIT-SPECT (dopamine transporter SPECT), lack of clinical response to levodopa

treatment, and normal HVA concentration in the cerebrospinal fluid all indicated normal dopamine production.

Although we could not determine the exact pathophysiological mechanisms, pressure on the periventricular monoamine projections in the thalamus and hypothalamus without major dopamine deprivation in the striatum may have been the most important factors in the development of akinetic mutism in this patient.

References

- 1) Alexander MP: Chronic akinetic mutism after mesencephalic-diencephalic infarction: remediated with dopaminergic medications. *Neurorehabil Neural Repair* 15: 151-156, 2001
- 2) Anderson B: Relief of akinetic mutism from obstructive hydrocephalus using bromocriptine and ephedrine. Case report. *J Neurosurg* 76: 152-155, 1992
- 3) Barris RW, Schuman HR: Bilateral anterior cingulate gyrus lesions; syndrome of the anterior cingulate gyri. *Neurology* 3: 44-52, 1953
- 4) Berger L, Gauthier S, Leblanc R: Akinetic mutism and parkinsonism associated with obstructive hydrocephalus. *Can J Neurol Sci* 2: 255-258, 1985
- 5) Cairns H, Oldfield RC, Pennybacker JB, Whitteridge D: Akinetic mutism with an epidermoid cyst of the 3rd ventricle. (With a report of the associated disturbance of brain potentials.) *Brain* 64: 273-290, 1941
- 6) Devinsky O, Morrell MJ, Vogt BA: Contributions of anterior cingulate cortex to behaviour. *Brain* 118: 279-306, 1995
- 7) Duma D, Argintaru D, Serban M: [Mesodiencephalic tumors with akinetic mutism]. *Neurol Psihiatr Neurochir* 12: 201-205, 1967 (Rom)
- 8) Echiverri HC, Tatum WO, Merens TA, Coker SB: Akinetic mutism: pharmacologic probe of the dopaminergic mesencephalofrontal activating system. *Pediatr Neurol* 4: 228-230, 1988
- 9) Freeman FR: Akinetic mutism and bilateral anterior cerebral artery occlusion. *J Neurol Neurosurg Psychiatry* 34: 693-698, 1971
- 10) Gugliotta MA, Silvestri R, De Domenico P, Galatioto S, Di Perri R: Spontaneous bilateral anterior cerebral artery occlusion resulting in akinetic mutism. A case report. *Acta Neurol (Napoli)* 11: 252-258, 1989
- 11) Hertel F, Walter C, Schmitt M, Morsdorf M, Jammers W, Bushc HP, Bettaq M: Is a combination of Tc-SPECT or perfusion weighted magnetic resonance imaging with spinal tap test helpful in the diagnosis of normal pressure hydrocephalus? *J Neurol Neurosurg Psychiatry* 74: 479-484, 2003
- 12) Kadota Y, Kondo T, Sato K: Akinetic mutism and involuntary movements following radical resection of hypothalamic glioma—case report. *Neurol Med Chir (Tokyo)* 36: 447-450, 1996
- 13) Lee KS, Kwon OY, Lee L, Park KJ, Choi NC, Lim BH: [A case of akinetic mutism caused by volume change of cerebral ventricles]. *Journal of Korean Neurological Association* 20: 414-417, 2002 (Kor, with Eng abstract)
- 14) Marshall JF, Gotthelf T: Sensory inattention in rats with 6-hydroxydopamine-induced degeneration of ascending dopaminergic neurons: apomorphine-induced reversal of deficits. *Exp Neurol* 65: 398-411, 1979
- 15) Marshall JF, Ungerstedt U: Apomorphine-induced restoration of drinking to thirst challenges in 6-hydroxydopamine-treated rats. *Physiol Behav* 17: 817-822, 1976
- 16) Messert B, Henke TK, Langheim W: Syndrome of akinetic mutism associated with obstructive hydrocephalus. *Neurology* 16: 635-649, 1966
- 17) Moser A, Freyberger HJ, Bruckmann H, Kompf D: [Akinetic mutism in decompensated triventricular hydrocephalus]. *Fortschr Neurol Psychiatr* 63: 248-251, 1995 (Ger, with Eng abstract)
- 18) Nemeth G, Hegedus K, Molnar L: Akinetic mutism associated with bicingular lesions: clinicopathological and functional anatomical correlates. *Eur Arch Psychiatry Neurol Sci* 237: 218-222, 1988
- 19) Psarros T, Zouros A, Coimbra C: Bromocriptine-responsive akinetic mutism following endoscopy for ventricular neurocysticercosis. Case report and review of the literature. *J Neurosurg* 99: 397-401, 2003
- 20) Ross ED, Stewart RM: Akinetic mutism from hypothalamic damage: successful treatment with dopamine agonists. *Neurology* 31: 1435-1439, 1981
- 21) Saper CB: Function of the locus coeruleus. *Trends Neurosci* 10: 343-344, 1987
- 22) Stewart JT, Leadon M, Gonzalez-Rothi LJ: Treatment of a case of akinetic mutism with bromocriptine. *J Neuropsychiatry Clin Neurosci* 2: 462-463, 1990
- 23) Ugenstedt U: Functional dynamics of central monoamine pathways, in Schmitt FO, Worden FG (eds): *The Neurosciences: Third Study Program*. Cambridge, Mass, MIT Press, 1974, pp 979-988
- 24) Watahiki Y, Narita S, Kurahashi K, Tanaka T, Matsunaga M: [Akinetic mutism from recurrent hydrocephalus: successful treatment with levodopa, bromocriptine and trihexyphenidyl]. *No To Shinkei* 39: 977-982, 1987 (Jpn, with Eng abstract)
- 25) Wolff V, Saint Maurice JP, Ducros A, Guichard JP, Woimant F: [Akinetic mutism and anterior bicerebral infarction due to abnormal distribution of the anterior cerebral artery]. *Rev Neurol (Paris)* 158: 377-380, 2002 (Fre)

Address reprint requests to: Myoung Soo Kim, M.D., Department of Neurosurgery, Seoul Paik Hospital, Inje University College of Medicine, 85 Jeo-dong 2-ga, Jung-gu, Seoul 100-032, R.O.K. e-mail: hanibalkms@hanmail.net