

Radiosurgery

Management and prognosis of cysts developed on
long-term follow-up after Gamma Knife radiosurgery for
intracranial arteriovenous malformations^{☆,☆☆}

Masahiro Izawa, MD^{a,*}, Mikhail Chernov, MD^{a,b}, Motohiro Hayashi, MD^a,
Kotaro Nakaya, MD^a, Shuji Kamikawa, MD^a, Koichi Kato, MD^a, Takashi Higa, MD^a,
Hiroshi Ujiie, MD^a, Hidetoshi Kasuya, MD^a, Takakazu Kawamata, MD^a,
Yoshikazu Okada, MD^a, Osami Kubo, MD^a, Hiroshi Iseki, MD^{a,b},
Tomokatsu Hori, MD^a, Kintomo Takakura, MD^{a,b}

^aDepartment of Neurosurgery, Neurological Institute, Tokyo Women's Medical University, Tokyo 162-8666, Japan

^bInternational Research and Educational Institute for Integrated Medical Sciences (IREIIMS), Tokyo Women's Medical University, Tokyo 162-8666, Japan

Received 7 September 2006; accepted 21 November 2006

Abstract

Background: Delayed cyst formation is a well-recognized complication after radiosurgery for intracranial AVM. The objective of the present study was the evaluation of the different management options for these lesions and the corresponding prognosis of patients.

Methods: Between 2000 and 2005, 12 patients with intracranial AVM initially treated by GKR were reevaluated at Tokyo Women's Medical University because of delayed cyst formation in the vicinity of the target area. There were 7 men and 5 women. The mean age of the patients was 31.8 years at the time of GKR and 41.1 years at the time of complication. The average period between treatment and diagnosis of the complication constituted 6.7 years. All AVMs had lobar location and showed complete angiographic obliteration after GKR.

Results: The most common neurological signs and symptoms at the time of cyst presentation were headache (10 cases) and seizures (4 cases). Two patients were asymptomatic. Three patients underwent surgery soon after the diagnosis of the cyst, whereas initial observation was done in another 9. Among the latter, 5 patients had to be treated surgically thereafter because of persistent or aggravated neurological symptoms associated with radiological cyst expansion. Four other patients, including both asymptomatic ones, are in stable condition without surgery. Follow-up after treatment of the cyst varied from 7 to 60 months (average, 34.3 months). All patients are in good condition.

Conclusions: Although delayed formation of cysts after GKR for intracranial AVM should be considered as a complication of the radiosurgical treatment, it has a relatively good prognosis. Observation can be recommended as initial option for compensated and asymptomatic patients.

© 2007 Elsevier Inc. All rights reserved.

Keywords: Arteriovenous malformation; Complication; Cyst; Gamma Knife radiosurgery; Management; Prognosis

Abbreviations: AVM, Arteriovenous malformation; CT, Computed tomography; GKR, Gamma Knife radiosurgery; MRI, Magnetic resonance imaging. The results of this study were presented during the 13th International Meeting of the Leksell Gamma Knife Society (May 21–25, 2006; Seoul, ROK).

[☆] No author has any financial interest on the subject under discussion.

^{☆☆} This work was supported by the Program for Promoting the Establishment of Strategic Research Centers, Special Coordination Funds for Promoting Science and Technology, Ministry of Education, Culture, Sports, Science, and Technology (Japan).

* Corresponding author. Tel.: +81 3 3353 8111x26216; fax: +81 3 5269 7438.

E-mail address: mizawa@nij.twmu.ac.jp (M. Izawa).

1. Introduction

Radiosurgery is an established management option for intracranial AVM, which results in 55% to 81% complete obliteration of the lesion within several years after treatment [1,3,4,6,7,15,17,19]. Early complications are mainly associated with hemorrhage from the functioning nidus during the so-called latency period [3,7]. When complete obliteration is attained, the risk of hemorrhage, although preserved, becomes extremely low; but the possibility of several other complications still exists on the long-term follow-up [2,7,15,17,19,20]. One of the most frequent and clinically important of these is delayed cyst formation in the vicinity of the target area [4,7,9–11,14,16,20,21]. Analysis of the

different treatment options of this complication and evaluation of the corresponding patient prognosis in such cases were the objectives of the present study.

2. Materials and methods

Between 2000 and 2005, 12 patients (7 men and 5 women) with intracranial AVM who underwent primary treatment by GKR underwent reevaluation and management at the Department of Neurosurgery of the Tokyo Women's Medical University because of delayed cyst formation in the vicinity of the target area. These cases were analyzed retrospectively with regard to outcome after treatment. Eight cases of the

Table 1
Summary of the clinical data in patients with delayed cyst formation after radiosurgery for intracranial AVM

Case	Age (years), sex	Initial nidus volume (mL)	Time to the cyst diagnosis (y)	Presenting symptoms at the time of cyst diagnosis	Initial observation (y)	Surgical treatment	Follow-up (mo)	Outcome
1	37, M	15.3	6	Headache, seizures	No	Endoscopic cyst fenestration and cyst-peritoneal shunting	60	Good ^a
2	39, M	12.9	5	No symptoms	Observation only	No surgery	60	Good
3	58, F	4.8	7	No symptoms	Observation only	No surgery	60	Good
4	36, M	12.4	6	Headache, seizures	No	Endoscopic cyst fenestration and cyst-peritoneal shunting	48	Good ^a
5	37, F	10.4	9	Progressive headache, seizures, gradual cyst expansion	4	Endoscopic cyst revision and open microsurgical cyst fenestration with excision of the obliterated nidus	48	Good ^a
6	34, M	5.2	5	Progressive headache, gradual cyst expansion	3	Endoscopic cyst revision and open microsurgical cyst fenestration with excision of the obliterated nidus	36	Good
7	46, F	4.7	8	Progressive headache, seizures, vertigo, gradual cyst expansion	8 mo	Endoscopic cyst revision and open microsurgical cyst fenestration with excision of the obliterated nidus	24	Good ^a
8	28, M	9.6	7	Headache	10 mo	Open microsurgical cyst fenestration with excision of the obliterated nidus	24	Good
9	55, F	8.8	9	Headache	2	Open microsurgical cyst fenestration with excision of the obliterated nidus	24	Good
10	30, M	4.4	3	Headache	No	Open microsurgical cyst fenestration with excision of the obliterated nidus	14	Good
11	49, M	2.4	10	Headache	Observation only	No surgery	7	Good
12 ^b	44, F	8.5	5 (9)	Headache	Observation only	No surgery	7	Good

M indicates male; F, female.

^a In these cases, the patients are on antiepileptic medication; but the seizures are well controlled.

^b In this case, GKR was performed twice with an interval of 4 years; and cyst formation was disclosed 9 and 5 years after the first and second treatment session, respectively.

present series were included in a previous study of long-term complications after GKR, which was published elsewhere [7].

2.1. Primary radiosurgical treatment

Mean age of patients at the time of GKR was 31.8 ± 8.3 years (range, 21–46 years). All AVMs had lobar location and were presented by seizures (6 cases), headache (4 cases), and hemorrhage (2 cases). The Spetzler-Martin grade of the lesion was I in 2, II in 3, III in 6, and IV in 1 case(s). The mean volume of the nidus was 8.3 ± 4.0 mL (range, 2.4–15.3 mL).

All patients were treated with the Leksell Gamma Knife model B (Elekta Instruments AB, Stockholm, Sweden). The treatment planning was performed using KULA or Leksell GammaPlan based on the combination of the angiographic data, contrast-enhanced CT images, and, later, thin-sliced MRI. In all cases, complete coverage of the nidus with the prescription isodose line, which constituted 40% in 8 cases, 45% in 1, and 50% in 3, by using single or multiple isocenters, was done. The choice of the radiation dose depended on the target volume. The mean maximal dose was 51.9 ± 6.5 Gy (range, 40–62.5 Gy). The mean marginal dose was 22.2 ± 2.8 Gy (range, 18–25 Gy). One patient underwent radiosurgery twice: 4 years after initial treatment (18 Gy marginal dose at 45% isodose line), second GKR was done (15 Gy marginal dose at 50% isodose line) because of persistent residual nidus. In all cases, complete angiographic obliteration of the AVM was attained.

2.2. Delayed cyst formation: its presentation and management

Summary of the clinical data considering delayed cyst formation in the vicinity of the target area is presented in the Table 1. The complication was diagnosed an average of 6.7 ± 2.1 years (range, 3–10 years) after radiosurgical management of the AVM. At that time, the mean age of

patients was 41.1 ± 9.5 years (range, 28–58 years). The most common neurological signs and symptoms at the time of cyst presentation were headache (10 cases) and seizures (4 cases). Two patients were asymptomatic.

Indications for surgical treatment included presence of the neurological symptoms resistant to conservative therapy and/or significant mass effect caused by the lesion. Three patients underwent surgery soon after the diagnosis of the cyst. These included endoscopic cyst fenestration with cyst-peritoneal shunting (2 cases) and open microsurgical cyst fenestration with excision of the obliterated nidus (1 case). Nine patients were initially observed with or without medical treatment (analgetics, antiepileptic drugs). Among the latter, 5 patients underwent subsequent surgical treatment an average of 2.1 ± 1.4 years (range, 0.7–4 years) later, which was performed because of persistent (2 cases) or progressive (3 cases) headache associated with gradual cyst expansion identified on serial CT (3 cases). Open microsurgical cyst fenestration with excision of the obliterated nidus with or without initial endoscopic cyst revision was performed in all these cases. Four other patients, including both asymptomatic ones, were followed by serial clinical and radiological investigations.

2.3. Outcome

Outcome was evaluated at the time of the last follow-up visit. It was considered as good if the patient was symptom-free with or without additional medication (analgetics, antiepileptic drugs) and if the persistent or residual cyst did not show significant mass effect.

3. Results

Follow-up after management of the cyst varied from 7 to 60 months (average, 34 ± 20 months). All 8 surgically treated patients were in good general condition and

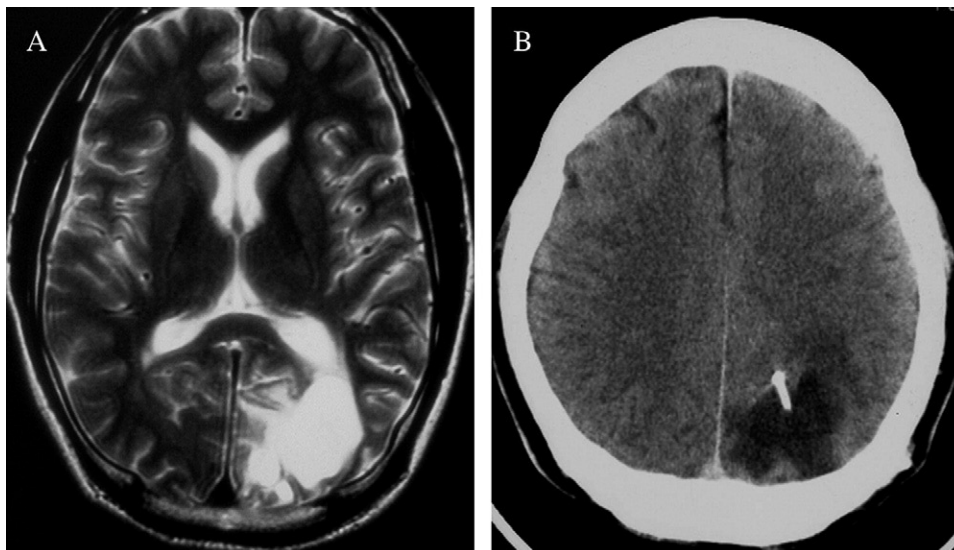


Fig. 1. Delayed cyst formation after radiosurgery of left parietooccipital AVM (case 1): T₂-weighted MRI at the time of clinical manifestation (A) and follow-up CT after cyst-peritoneal shunting (B).

symptom-free during 14 to 60 months follow-up (average, 35 ± 16 months). In 4 patients who had symptomatic epilepsy at the time of cyst diagnosis, the seizures were well controlled; but antiepileptic medication was prescribed constantly. Four patients who were treated without surgery were in stable condition during 7 to 60 months follow-up (average, 34 ± 31 months).

4. Illustrative cases

4.1. Case 1

A 37-year-old man was admitted with complaints of headache and epileptic seizures. Six years earlier, he underwent GKR for AVM of the left parietal and occipital lobes, which presented with hemorrhage. The volume of the lesion constituted 15.3 mL. It was completely covered by 40% isodose line with corresponding marginal dose of 20 Gy. The maximal dose was 50 Gy. Three years later, complete obliteration of the nidus was marked. Clinical investigation at the time of admission revealed cystic lesion in the left parietal area (Fig. 1). The patient underwent endoscopic cyst fenestration and cyst-peritoneal shunting. After treatment, his headache disappeared completely; and no seizures were observed during follow-up of 60 months, although antiepileptic medication is prescribed constantly.

4.2. Case 6

A 34-year-old man was admitted with complaints of headache. Eight years earlier, he underwent GKR for left parietal AVM. The volume of the lesion constituted 5.2 mL. It was completely covered by 40% isodose line with corresponding marginal dose of 22 Gy. The maximal dose was 55 Gy. Two years later, complete obliteration of the nidus was identified. Five years after treatment, the patient marked

appearance of mild headache. Clinical examination revealed cyst formation in the left parietal area. No neurological signs were disclosed. Treatment with analgetics was initially effective; however, headache relapsed later on. Serial neuroimaging revealed gradual increase in the cyst volume and appearance of the mass effect (Fig. 2). Therefore, 3 years after diagnosis of the complication, elective surgical treatment was done. Initial neuroendoscopic revision of the cyst cavity disclosed patent mural nidus despite angiographically confirmed complete obliteration of the AVM (Fig. 3). Open microsurgical excision and fenestration of the cyst were performed. After surgery, headache disappeared completely. The patient is symptom-free during 3 years of follow-up.

4.3. Case 11

A 49-year-old man was admitted with complaints of headache. Ten years earlier, he underwent GKR of left temporal AVM, which was presented with seizures. The volume of the lesion constituted 2.4 mL. It was completely covered by 50% isodose line with corresponding marginal dose of 25 Gy. The maximal dose was 50 Gy. Two years later, complete obliteration of the nidus was identified. Eight years after treatment, the patient marked appearance of nonconstant mild headache. Clinical examination 10 years after radiosurgery revealed cystic lesion in the left temporal lobe (Fig. 4). No neurological signs were disclosed. Symptomatic treatment with analgetics was initiated and resulted in complete release of symptoms. The patient's condition and cyst volume are stable during 7 months of follow-up.

5. Discussion

Delayed cyst formation is an enigmatic complication after radiosurgery for intracranial AVM, which was not marked at

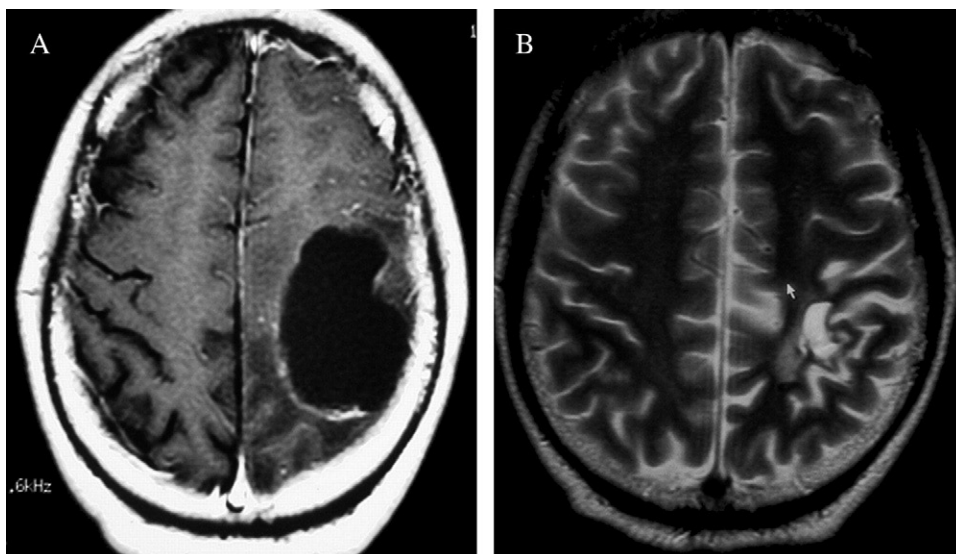


Fig. 2. Delayed cyst formation after radiosurgery of left parietal AVM (case 6): T₁-weighted MRI before surgical treatment (A) and T₂-weighted MRI 2 years thereafter (B).

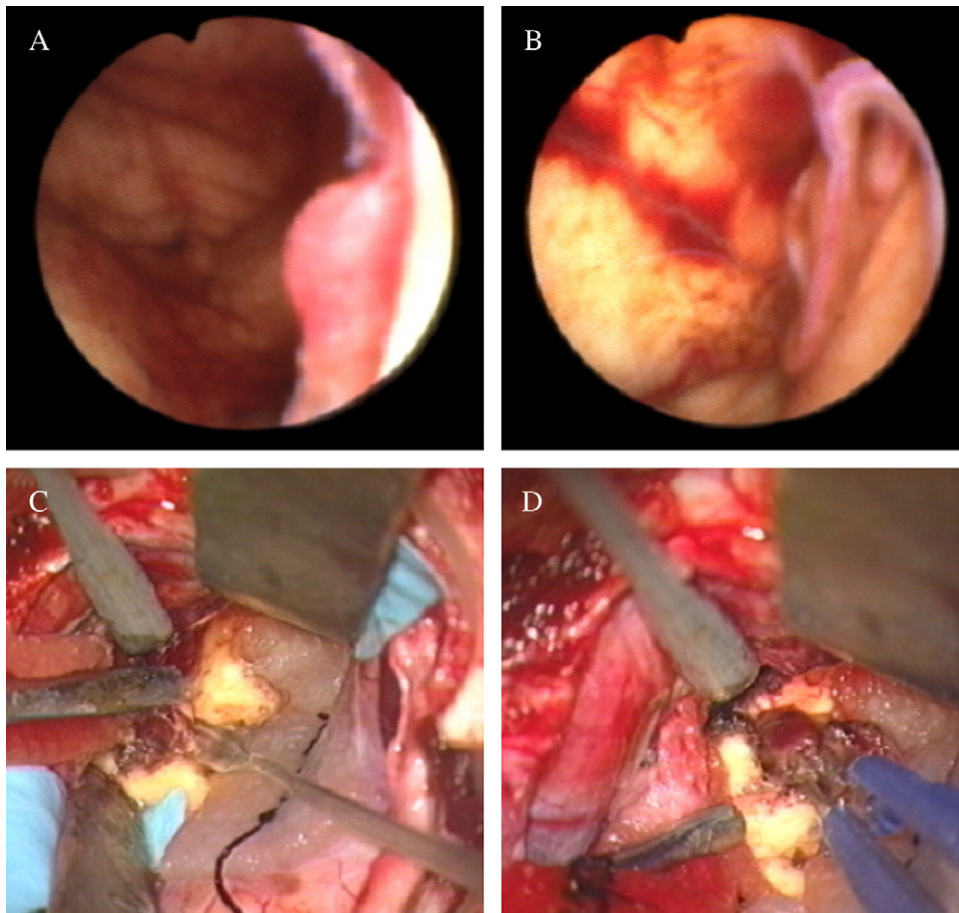


Fig. 3. Details of the surgical procedure in case 6: neuroendoscopic revision of the cyst that developed after radiosurgery for cerebral AVM with its angiographically confirmed complete obliteration permitted to reveal patent mural nidus (A and B), which was further excised at open surgery (C and D).

all in several large series [3,6] but was reported with a frequency from 0.4% to 28% in others [1,2,4,9–11, 14,15,17,19,20]. Our previous analysis of patients with AVM treated by GKR at Tokyo Women's Medical University

between 1991 and 2002 and followed for at least 2 years revealed delayed cyst formation in 3.4% of cases [7]. The rate of the complication definitely depends on the length of follow-up and regularity of long-term imaging [11,14,20].

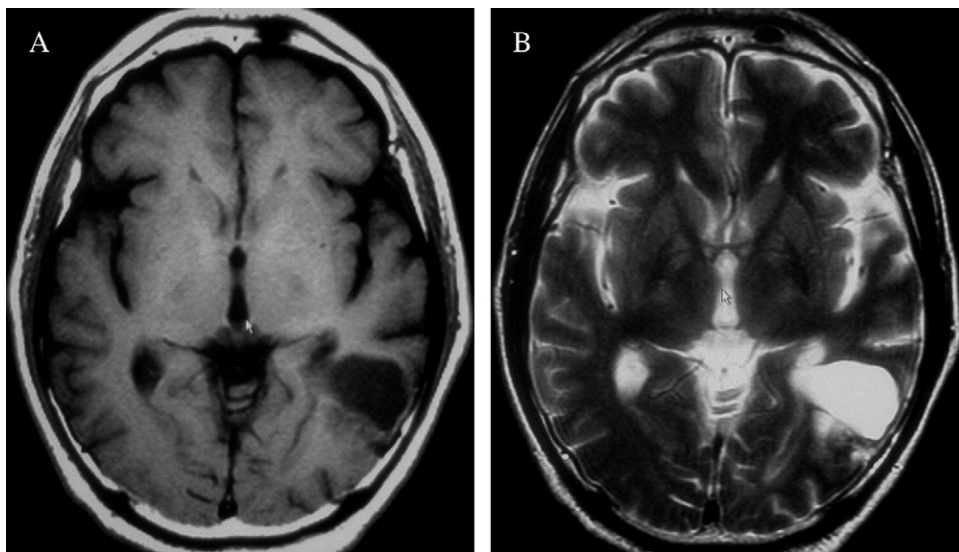


Fig. 4. T₁-weighted (A) and T₂-weighted (B) MRI of the cystic lesion 10 years after radiosurgery of left temporal AVM (case 11). The patient is treated conservatively by analgetics and followed by serial neuroimaging.

Using multivariate analysis, Pan et al [11] found that prior embolization and radiation-induced brain edema have statistically significant interrelationships with delayed cyst formation. The risk of the complication seems to be higher after repeated radiosurgery for residual functioning nidus, compared with primary treatment; in the series of Pollock and Brown [14], its incidence constituted 1.3% and 10%, respectively. Our previous study [7] revealed 4 factors associated with the development of the cyst, namely, large nidus volume, high maximal treatment dose, complete obliteration of AVM, and lobar location of the lesion. The mean nidus volume (9.9 ± 3.7 mL) and mean maximal treatment dose (52.8 ± 5.9 Gy) in these cases were significantly ($P < .001$) greater compared with the whole investigated cohort (4.7 ± 1.9 mL and 42.8 ± 6.4 Gy, respectively). Larger nidus volume and higher treatment dose can explain the statistically significant propensity of the cyst formation after radiosurgery for lobar AVM, compared with deep-seated lesions, which was found in our series [7].

Various pathophysiological mechanisms can be responsible for cyst development: direct radiation injury to the perilesional brain tissue [2,6,9], increased permeability of the blood-brain barrier with extravasation of the biologically active substances and accumulation of the exudative fluid [4,14,17,19,20], hemodynamic perturbations during gradual obliteration of the nidus with subsequent ischemic tissue damage [12,18], tissue damage due to multiple subclinical perilesional hemorrhages, gradual resorption of the hematoma [10,20], and partial destruction of the thrombosed AVM [9,20]. From a clinical point of view, it is important to differentiate the 2 types of cysts [19]. The first type, which was described by Kihlstrom et al [9], was represented by small cavitations within the obliterated nidus, which are usually self-limiting and asymptomatic and frequently resolve spontaneously. The second type, which was reported previously [4,10,11,14,16,19–21] and formed the present series, included large perilesional cysts, which frequently cause mass effect and are usually accompanied by more or less prominent neurological symptoms and signs, which necessitate their active management.

Several treatment options of the complication were proposed. Initial observation with serial imaging is usually recommended if symptoms are absent or mild; and in fact, in many of these cases, no other treatment may be needed [11,14]. Some cysts can occasionally undergo spontaneous shrinkage [20]. In symptomatic cases, attempts of stereotactic aspiration were performed previously; but within weeks, recurrence was observed in all patients [14]. Although implantation of the Ommaya reservoir may be occasionally useful [10], cyst-peritoneal shunting represents a better option, with its efficacy confirmed in several series [11,14,15]. Correct position of the central shunt tube may however be difficult in multiple or multiloculated lesions [14]. Finally, particularly if shunting procedure is not effective, open cyst fenestration, excision of its wall, and resection of the nidus can be done [4,11,14–17,19,21].

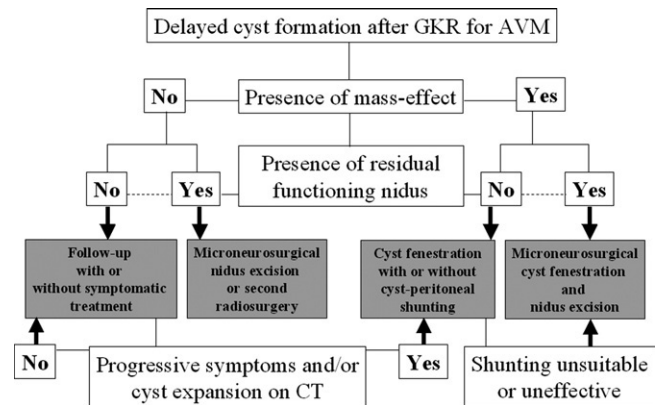


Fig. 5. Proposed algorithm for choice of the treatment option in cases of delayed cyst formation after radiosurgery for intracranial AVM.

In general, our experience with treatment of cysts that developed on the long-term follow-up after radiosurgery for cerebral AVM corresponds well to those reported previously [11,14]. It seems that the choice of the optimal management in such cases should be based on the presence or absence of 2 main factors, namely, mass effect and residual functioning nidus (Fig. 5). Initial observation can be recommended for compensated and asymptomatic patients whose lesion does not exhibit significant compression of the perilesional brain. Observation only with or without symptomatic therapy for headache was effectively used in 4 of 9 patients in the present series. Close clinical and radiological follow-up is necessary, however because in some cases progressive symptoms and gradual cyst expansion necessitate active treatment. Surgical options include cyst-peritoneal shunting and open micro-neurosurgical cyst fenestration with excision of the nidus. In both occasions, initial neuroendoscopic revision of the cyst cavity for identification of the mural nodule and evaluation of its patency may be helpful. Although it was never used in the present series, sole neuroendoscopic fenestration of the cyst into the ventricle might be sufficient enough for decompression of the lesion and relief of symptoms, whereas shunting procedure or open surgery can be reserved for recurrent cases only. Finally, if surgical excision of the presented residual nidus seems to be too risky, a second radiosurgery can be considered as a possible treatment option in cases without mass effect and signs of radiation damage to the perilesional brain tissue [20].

Different options were proposed for the avoidance of the long-term complications after radiosurgical treatment of intracranial lesions. No cyst formation was reported after staged-dose stereotactic fractionated radiotherapy of large AVMs, but their obliteration rate seems insufficient [1,8]. Staged-volume radiosurgery was proposed recently for the prevention of radiation injury to the normal brain tissue; however, it is not clear yet whether this technique can prevent the development of delayed cyst formation [5,7,13,14]. Meanwhile, no attention was put previously on the generally benign prognosis of this complication. Most patients remain neurologically intact [9,11,14]. In the series of Pan et al [11],

just 6 of 20 patients with these lesions had symptoms; and only 3 needed active treatment. Although in exceptional cases symptomatic epilepsy may cause disastrous consequences in a patient with an expanded cyst after radiosurgery for AVM [1], in general, appropriate management, both conservative and surgical, usually results in favorable functional outcome [9-11,14-16,21]. It should also be marked that all our patients showed complete obliteration of the nidus, in agreement with some of the previous reports [4,14,16]. Therefore, it can be speculated that in most cases delayed cyst formation is a complication of an effective radiosurgical treatment, which is definitely beneficial for patients in terms of AVM obliteration.

6. Conclusion

The choice of the optimal management for cysts that developed in the vicinity of the target area on the long-term follow-up after radiosurgery of intracranial AVM should be based on the presence of mass effect and residual functioning nidus. Initial observation with close clinical and radiological follow-up can be appropriate for compensated and asymptomatic patients in cases of complete AVM obliteration. Overall, the complication has a relatively good prognosis; and both conservative and surgical treatments generally result in favorable functional outcome.

References

- [1] Chang TC, Shirato H, Aoyama H, et al. Stereotactic irradiation for intracranial arteriovenous malformation using stereotactic radiosurgery or hypofractionated stereotactic radiotherapy. *Int J Radiat Oncol Biol Phys* 2004;60:861-70.
- [2] Flickinger JC, Kondziolka D, Lunsford LD, et al. A multi-institutional analysis of complication outcomes after arteriovenous malformation radiosurgery. *Int J Radiat Oncol Biol Phys* 1999;44:67-74.
- [3] Friedman WA. Radiosurgery for arteriovenous malformations: the University of Florida experience. In: Kondziolka D, editor. *Radiosurgery*, vol 4. Basel: Karger; 2002. p. 12-8.
- [4] Hara M, Nakamura M, Shiokawa Y, et al. Delayed cyst formation after radiosurgery for cerebral arteriovenous malformation: two case reports. *Minim Invasive Neurosurg* 1998;41:40-5.
- [5] Hayashi M, Izawa M, Ochiai T, et al. The treatment strategy of staged radiosurgery for high-grade arteriovenous malformation considering post-radiosurgical complication. *Stereotact Radiother* 2005;9:87-96 [article in Japanese].
- [6] Inoue HK, Tezuka M, Oda O, et al. Optimal radiosurgery dosages for the treatment of arteriovenous malformations in the era of magnetic resonance imaging. In: Kondziolka D, editor. *Radiosurgery*, vol 4. Basel: Karger; 2002. p. 19-25.
- [7] Izawa M, Hayashi M, Chernov M, et al. Long-term complications after gamma knife surgery for arteriovenous malformations. *J Neurosurg* 2005;102(Suppl):34-7.
- [8] Karlsson B, Lindqvist M, Blomgren H, et al. Long-term results after fractionated radiation therapy for large brain arteriovenous malformations. *Neurosurgery* 2005;57:42-9.
- [9] Kihlstrom L, Guo W-Y, Karlsson B, et al. Magnetic resonance imaging of obliterated arteriovenous malformations up to 23 years after radiosurgery. *J Neurosurg* 1997;86:589-93.
- [10] Kim MS, Lee SI, Sim JH. A case of very large cyst formation with Gamma Knife radiosurgery for an arteriovenous malformation. *Stereotact Funct Neurosurg* 1999;72(Suppl 1):168-74.

- [11] Pan H-C, Sheehan J, Stroila M, et al. Late cyst formation following gamma knife surgery of arteriovenous malformations. *J Neurosurg* 2005;102(Suppl 1):124-7.
- [12] Pollock BE. Occlusive hyperemia: a radiosurgical phenomenon? *Neurosurgery* 2000;47:1178-84.
- [13] Pollock BE, Kline RW, Stafford SL, et al. The rationale and technique of staged-volume arteriovenous malformation radiosurgery. *Int J Radiat Oncol Biol Phys* 2000;48:817-24.
- [14] Pollock BE, Brown Jr RD. Management of cysts arising after radiosurgery to treat intracranial arteriovenous malformations. *Neurosurgery* 2001;49:259-65.
- [15] Pollock BE, Gorman DA, Coffey RJ. Patient outcomes after arteriovenous malformation radiosurgical management: results based on a 5- to 14-year follow-up study. *Neurosurgery* 2003;52:1291-7.
- [16] Radanowicz-Hartmann V, Bachli H, Gratzl O. Late complication of radiosurgery of AVMs with the gamma knife: a case report. *Acta Neurochir (Wien)* 1998;140:194-5.
- [17] Yamamoto M, Jimbo M, Hara M, et al. Gamma Knife radiosurgery for arteriovenous malformations: long-term follow-up results focusing on complications occurring more than 5 years after irradiation: clinical study. *Neurosurgery* 1996;38:906-14.
- [18] Yamamoto M, Ban S, Ide M, et al. A diffuse white matter ischemic lesion appearing 7 years after stereotactic radiosurgery for cerebral arteriovenous malformations: case report. *Neurosurgery* 1997;41:1405-9.
- [19] Yamamoto M, Hara M, Ide M, et al. Radiation-related adverse effects observed on neuro-imaging several years after radiosurgery for cerebral arteriovenous malformations. *Surg Neurol* 1998;49:385-98.
- [20] Yamamoto M, Ide M, Jimbo M, et al. Late cyst convolution after gamma knife radiosurgery for cerebral arteriovenous malformations. *Stereotact Funct Neurosurg* 1998;70(Suppl 1):166-78.
- [21] Yonekawa Y, Imhof HG, Bjeljac M, et al. Three cases of AVM at eloquent areas finally treated with conventional microsurgical method. *Acta Neurochir Suppl* 2005;94:105-10.

Commentary

One of the late complications of successful radiosurgery, cyst development at or adjacent to the target site of AVM has been seen in 1-3% of series with extensive longterm experience. The reasons for development are not clear. I believe that it is more likely in patients who have had prior bleeds (perhaps iron pigment is a sensitizer for adverse radiation effects) and in patients with multimodality treatment including prior surgery, embolization, or prior radiosurgery. Fortunately, as the authors point out, the consequences in general are handled by observation (if no clinical symptoms are detected) or by surgical drainage. I have placed an Ommaya type reservoir for a basal ganglionic AVM related cyst to facilitate periodic aspiration. However, when feasible, I believe that cyst fenestration is the best approach. Although a low incidence, I believe that periodic MRI surveillance even in patients with demonstrated AVM obliteration is warranted.

L. Dade Lunsford, MD
Department of Neurosurgery
Presbyterian University Hospital
Pittsburgh, PA 15213, USA