

Vascular

A restricted subarachnoid hemorrhage in the cortical sulcus in cerebral amyloid angiopathy: could it be a warning sign?

Masahito Katoh, MD*, Masami Yoshino, MD, Katsuyuki Asaoka, MD, Takeshi Aoki, MD, Hiroyuki Imamura, MD, Daina Kashiwazaki, MD, Kazuya Takano, MD, Toshimitsu Aida, MD

Department of Neurosurgery, Hokkaido Neurosurgical Memorial Hospital, Sapporo 060-0022, Japan

Received 14 May 2006; accepted 3 November 2006

Abstract

Background: Cerebral amyloid angiopathy is a well-known disease that is predominantly recognized in elderly people and repeatedly causes large subcortical hemorrhages. These hemorrhages may be derived from vessel wall weakness because of A β depositions in the wall of the cortical and leptomeningeal arteries. Although vessel ruptures in CAA have been thought to occur in cortical arteries, it was recently demonstrated that the primary hemorrhage occurs in the subarachnoid space, particularly the cerebral sulci, as a result of multiple ruptures of meningeal arteries in some cases of subcortical hematoma caused by CAA.

Case Description: Case patient 1 was a 74-year-old woman who presented with epileptic seizure. A restricted SAH in the right frontal lobe was observed on MRI. Thirty-three days later, left hemiparesis occurred suddenly and a huge subcortical hematoma was observed in the right frontal lobe on CT. The hematoma was removed, and the patient was pathologically diagnosed with amyloid angiopathy. Case patient 2 was a 73-year-old man who presented with epileptic seizure. A restricted SAH in the right frontal lobe was observed on MRI. Twenty days later, left hemiparesis occurred suddenly and a huge subcortical hematoma was observed in the right frontoparietal area on CT. Hematoma removal was performed on both patients, and they were diagnosed pathologically with amyloid angiopathy.

Conclusions: We report on the cases of 2 patients with CAA who presented with epileptic seizure and were found to have a restricted subarachnoid hematoma in the cerebral sulcus on MRI before their subcortical hemorrhages occurred. Both cases were diagnosed pathologically. This demonstrated that vessel ruptures in CAA can occur in the subarachnoid space, particularly the cerebral sulci, as a result of ruptures of meningeal arteries. A restricted SAH on CT/MRI could be a warning sign of a huge subcortical hemorrhage in CAA.

© 2007 Elsevier Inc. All rights reserved.

Keywords:

Cerebral amyloid angiopathy; Subarachnoid hemorrhage; Warning sign; Meningeal artery

1. Introduction

Cerebral amyloid angiopathy is a well-known disease that is predominantly recognized in elderly people and repeatedly causes large subcortical hemorrhages. These hemorrhages may be derived from vessel wall weakness and are very difficult to anticipate or control.

Abbreviations: A β , amyloid β protein; CAA, cerebral amyloid angiopathy; CT, computed tomography; EEG, electroencephalography; MRA, magnetic resonance angiogram; MRI, magnetic resonance imaging; SAH, subarachnoid hemorrhage.

* Corresponding author.

E-mail address: masasama@ceres.ocn.ne.jp (M. Katoh).

We report on 2 cases of CAA with huge subcortical hematomas. The patients presented with epileptic seizure and were found to have a restricted subarachnoid hematoma in the cerebral sulcus on MRI before their subcortical hemorrhages occurred.

A restricted SAH with epileptic seizure could be a warning sign of a huge subcortical hemorrhage in CAA.

2. Case patient 1

A 74-year-old woman presented herself to the Hokkaido Neurosurgical Memorial Hospital because of transient left

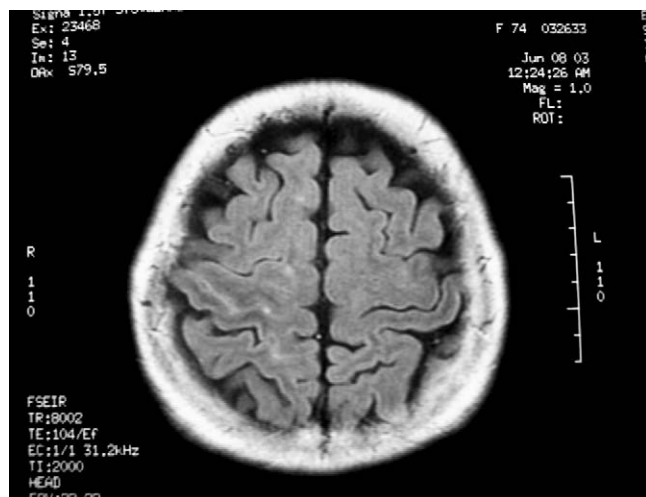


Fig. 1. Case patient 1: A restricted SAH in the right frontal lobe was observed on MRI.

hemiparesis and sensory disturbance. Neurologic deficit disappeared 30 minutes later. On MRI, there was no abnormality; however, she noted numbness in the left side of her body 7 days after her first visit. Although the numbness disappeared after 15 minutes, a restricted SAH in the right frontal lobe was observed on MRI (Fig. 1).

Because epileptic waves were found on electric encephalography, carbamazepine was prescribed.

No abnormal finding was detected on the MRA or in the cerebrospinal fluid; therefore, we did not know the cause of the restricted SAH. Because a trauma, brain tumor, or another unknown origin (eg, mycotic aneurysm, cortical vein thrombosis, or cavernous angioma) could not be excluded, epileptic waves were observed on EEG, and seizures could be controlled with the use of an anticonvulsant drug, we decided not to perform a biopsy but to conduct a periodic follow-up by MRI after thorough discussion with the patient.

The patient did not have hypertension, coagulopathy, or a history of having a malignant neoplasm.

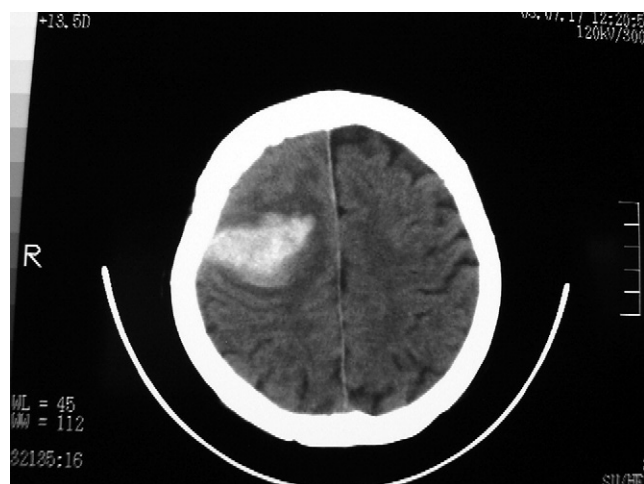

Fig. 2. Case patient 1: A huge subcortical hematoma in the right frontal lobe was observed.

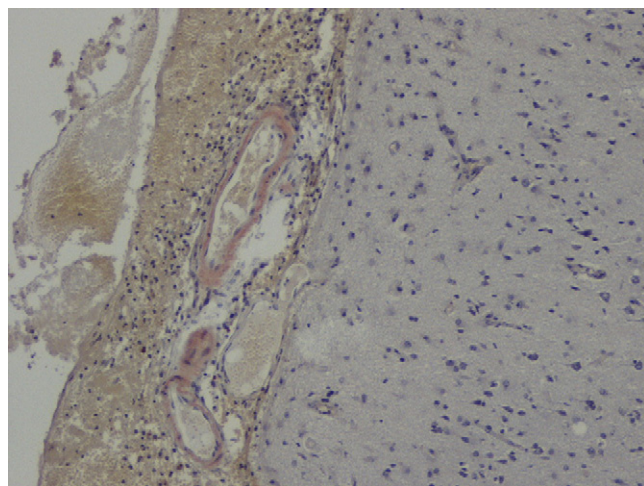


Fig. 3. Case patient 1: Amyloid β protein depositions were detected in vessel walls (direct fast scarlet stain).

Fourteen days later, left hemiparesis suddenly occurred in the patient, and she was brought to our hospital by ambulance. Neurologic examination demonstrated left hemispatial agnosia, left hemiparesis, and left hemihypesthesia. On CT, a huge subcortical hematoma was observed in the right frontal lobe (Fig. 2).

Removal of the hematoma was performed, and the patient was diagnosed with amyloid angiopathy (Fig. 3). No other lesion that could cause SAH and subcortical bleeding was found either intraoperatively or pathologically.

3. Case patient 2

A 73-year-old man was admitted to the Hokkaido Neurosurgical Memorial Hospital because of repeated left hemiparesis that lasted for approximately 10 minutes. Neurologic examination disclosed slight left hemiparesis. On MRI, a restricted SAH was noted in the right frontal sulcus (Fig. 4).

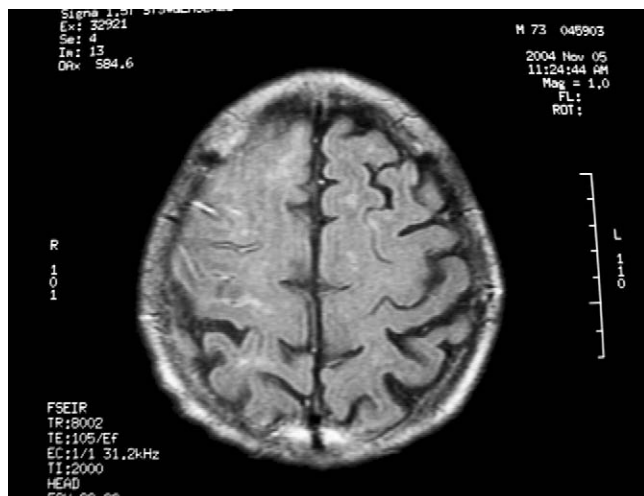


Fig. 4. Case patient 2: A restricted SAH in the right frontal sulcus was noted.

Sodium valproate was prescribed, and the repeated episodes of left hemiparesis disappeared.

We thought the patient might have had CAA when he presented with a restricted SAH on MRI; therefore, we paid close attention to his general condition, including his blood pressure.

The patient did not have hypertension, coagulopathy, or a history of having a malignant neoplasm.

However, on the day the patient was discharged, he fainted and was brought back to our hospital by ambulance. Neurologic examination revealed consciousness disturbance ($E_4V_4M_6 = 14$), dysarthria, and left hemiparesis. On CT, a huge subcortical hematoma was observed in the right frontoparietal area (Fig. 5).

Hematoma removal was performed, and the patient was diagnosed with amyloid angiopathy (Fig. 6). No other lesion that could cause SAH and subcortical bleeding was found either intraoperatively or pathologically.

4. Discussion

Cerebral amyloid angiopathy is caused by the deposition of $A\beta$ in the walls of cortical and leptomeningeal arteries. As a rule, veins and capillaries tend to be affected less frequently than arteries [3,4]. Finally, the layers of smooth muscle cells disappear, resulting in vessel weakness.

Although the etiology of this condition remains unknown, Weller and Nicoll [6] suggested that $A\beta$ deposits in vessel walls because of a loss of function in the periarterial interstitial fluid drainage pathway, which corresponds to the lymphatics of the brain.

Although vessel ruptures in CAA have been thought to occur in cortical arteries, Takeda et al [5] examined 6 autopsy cases and demonstrated that the primary hemorrhage occurs in the subarachnoid space, particularly the cerebral sulci, as a result of multiple ruptures of meningeal arteries in some cases of subcortical hematoma

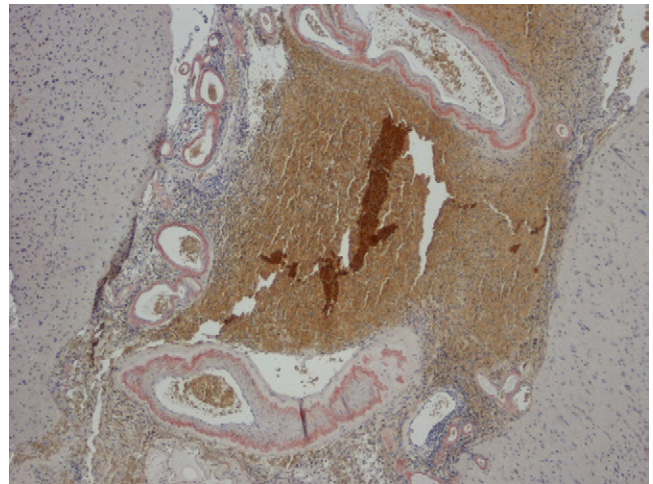


Fig. 6. Case patient 2: Amyloid β protein depositions were detected in vessel walls (direct fast scarlet stain).

caused by CAA. Maia et al [1,2] presented a case showing a restricted SAH on CT and MRI and, although there was no pathologic evidence, suggested that these findings supported the theory presented by Takeda et al [5].

In our case patients, a restricted SAH preceded a huge subcortical hemorrhage and pathologic evidence was available. This is the first evidence of hemorrhage occurring in the subarachnoid space in CAA. Takeda et al [4] reported that they observed many ruptured vessels in subarachnoid hematomas. Repeated and restricted SAH might result in a huge subcortical hematoma.

Both our case patients presented with epileptic seizure without dementia. The case patient reported on by Maia et al [1,2] also presented with epileptic seizure showing a restricted SAH.

Could this restricted SAH on CT/MRI be a warning sign of a huge subcortical hemorrhage in CAA? A definitive diagnosis of CAA cannot be made from this finding alone, and there is no indication for biopsy at that time. However, other etiologies cannot be identified in elderly patients without a traumatic episode who show a restricted SAH at a location distant from the common sites of cerebral aneurysms.

Hemorrhage in CAA, as indicated, results from weakening of the vessel walls. Therefore, the anticipation or prevention of these hemorrhages is very difficult. However, attention can be focused on the nature of an attack.

When the precise mechanism of cerebral vessel rupture in CAA is elucidated, this warning sign will become more clinically significant.

References

- [1] Maia LF, Botelho L, Correia MM. Commentary on "Subcortical hematoma caused by cerebral amyloid angiopathy: does the first evidence of hemorrhage occur in the subarachnoid space?" *Neuropathology* 2003; 23, 254–61.

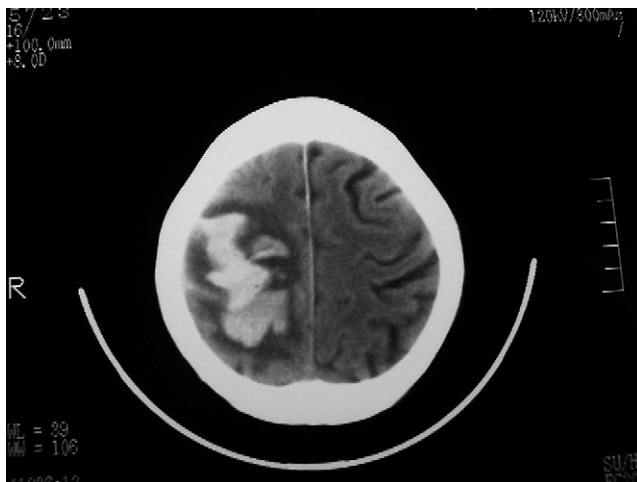


Fig. 5. Case patient 2: A huge subcortical hematoma in the right frontoparietal area was observed.

- [2] Maia LF, Botelho L, Correia MM. Commentary on “Subcortical hematoma caused by cerebral amyloid angiopathy: does the first evidence of hemorrhage occur in the subarachnoid space?” *Neuropathology* 2004;24(4):354-5.
- [3] Mughal M, Allen S. Cerebral amyloid angiopathy as a cause of recurrent intracerebral hemorrhage. *Conn Med* 2002;66(2):67-70.
- [4] Revesz T, Ghiso J, Lashley T, Plant G, Rostagno A, Frangione B, Holton JL. Cerebral amyloid angiopathies: a pathologic, biochemical, and genetic view. *J Neuropathol Exp Neurol* 2003;62(9):885-98.
- [5] Takeda S, Yamazaki K, Miyakawa T, Onda K, Hinokuma K, Ikuta F, Arai H. Subcortical hematoma caused by cerebral amyloid angiopathy: does the first evidence of hemorrhage occur in the subarachnoid space? *Neuropathology* 2003;23(4):254-61.
- [6] Weller RO, Nicoll JA. Cerebral amyloid angiopathy: pathogenesis and effects on the ageing and Alzheimer brain. *Neurol Res* 2003;25(6):611-6.