

Letters to the Editor

Unilateral periodic leg movements during wakefulness and sleep after a parietal hemorrhage

To the Editor:

Although periodic leg movements (PLM) [1] following lesions in the cerebral white matter, basal ganglia, or brainstem are known, abnormalities confined to a lobar location have not been reported.

A 58-year-old man experienced a left parietal hemorrhage in 1993, shortly after a liver transplant (cirrhosis). He came to our attention 13 years later, after an accidental left fronto-basal contusion. He had tacrolimus-induced chronic renal failure and a mild, symmetrical axonal polyneuropathy; medication included benzodiazepines, vitamins, and electrolytes. He complained of rhythmic movements of his right leg, appearing at rest, which prevented him from falling asleep, starting a few weeks after the stroke; he denied any associated unpleasant sensation or need to move. This had been interpreted as symptomatic simple-partial seizures and was treated unsuccessfully with anti-epileptic agents. On examination, he had a moderate right hemibody ataxic hemiparesis with sensory impairment (postural sensation, graphesthesia) and a spastic component. At rest, his right toes and foot began to dorsiflex slowly and periodically, with a slight knee flexion. This was abolished by voluntary posturing; the left limb was not involved. Magnetic resonance imaging (MRI) showed the old parietal lesion but no basal ganglia abnormality (Fig. 1a). An afternoon polysomnographic recording confirmed brief periodic movements occurring every 20 s exclusively on the right, during quiet wakefulness (Fig. 1b); they persisted in light sleep (Fig. 1c and d), inducing periodic microarousals (Fig. 1c), and disappeared during rapid eye movement (REM) sleep. Plasma ferritin was within the normal range. Routine electroencephalograms (EEGs) performed under the same conditions were normal. The movements practically disappeared with 0.250 mg pramipexole.

These movements fulfill diagnostic criteria for PLM [1]. Seizures are unlikely: the former displayed a relatively low frequency and lacked any myoclonic component; furthermore, the EEG was normal, and there was

a response to dopaminergic, but not to antiseizure, drugs. Medication and uremia may have worsened the picture, but PLM appeared just after the hemorrhage, before either could exert a durable action. The strictly asymmetrical location argues against a substantial role of alcoholic polyneuropathy or hepatic-induced basal ganglia dysfunction. Our observation is limited by the short polysomnographic recording, since the patient refused an overnight study. In fact, PLM may switch sides; however, we believe that his history, our observations, and previous medical records reporting PLM only on the right are highly suggestive of unilateral PLM.

These movements have several interesting features. They appeared shortly after the left parietal hemorrhage, strongly suggesting a causal relationship. To our knowledge, this represents the most rostral lesion inducing PLM: spinal lesions are relatively common [2], whereas pontine lesions [3], subcortical stroke [4], and corticobasal degeneration [5] are exceptional. PLM pathophysiology remains unclear [6]. A functional MRI study showed activation of the brainstem reticular formation and the red nuclei during PLM [7]; a dysfunction of a dopamine-modulated spinal pathway from the hypothalamus has also been postulated [6]. PLM following spinal lesions suggest the presence of a disinhibited spinal pacemaker [2]. Regardless of the exact location of the putative pacemaker, in analogy to corticobasal degeneration [5], our description suggests that parietal lobe impairment might disrupt cortical excitatory inputs to the basal ganglia, altering the physiological balance. Our patient's PLM are strictly unilateral, a rare finding described in symptomatic cases following central nervous system (CNS) lesions [2–5]. In the absence of restless legs, the complaint of PLM leading to insomnia represents an intriguing feature. As in patients with spinal cord impairment [2], the condition lasted for many years before the correct diagnosis, but, as opposed to PLM following brainstem lesions [4], it was resolved by dopamine agonists. Considering the misdiagnosis of partial epilepsy for years, our observation suggests that similar conditions might represent an underreported cause of insomnia in stroke patients.

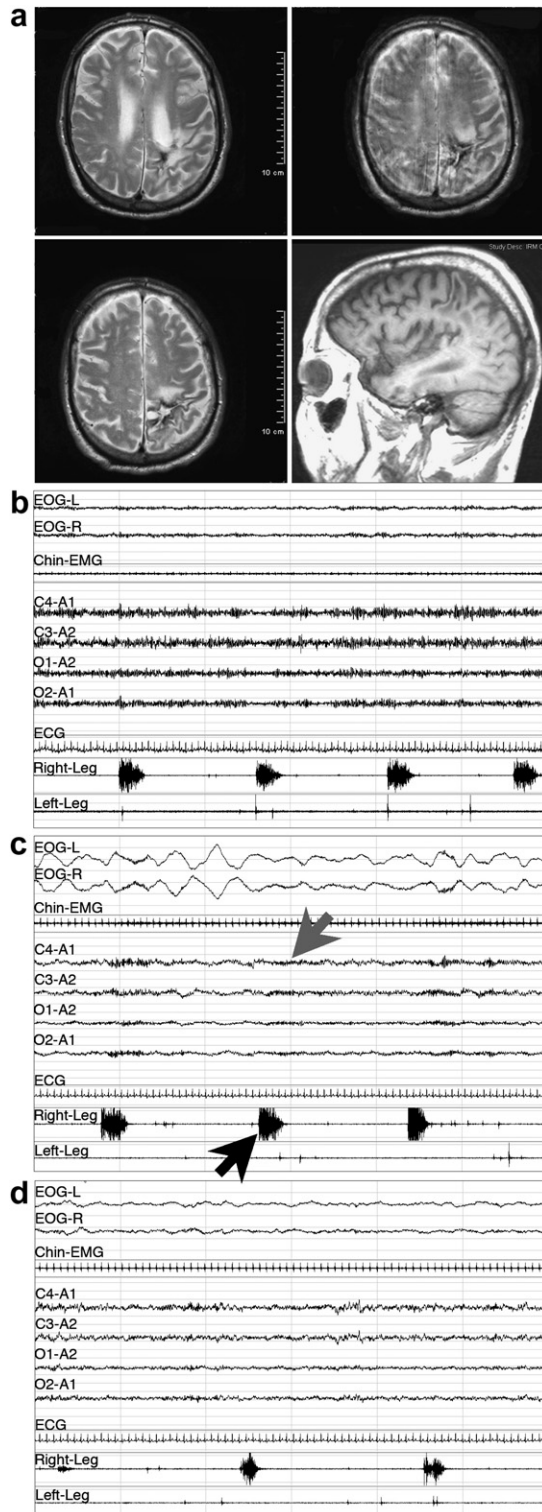


Fig. 1. T2 weighted axial and T1 weighted sagittal (right lower corner) MRI, showing the old left superior parietal lobar hemorrhage (a); polysomnographic recordings during wakefulness (b) stage 1 (c), and stage 2 sleep (d), disclosing PLM in the right leg (black arrow; one page corresponds to 60 s), with the induced micro-arousals (gray arrow).

References

- [1] Walters AS. Toward a better definition of the restless legs syndrome. The International Restless Legs Syndrome Study Group. *Mov Disord* 1995;10:634–42.
- [2] Nogués M, Cammarota A, Leiguarda R, Rivero A, Pardal A, Encabo H. Periodic limb movements in syringomyelia and syringobulbia. *Mov Disord* 2000;15:113–9.
- [3] Kim JS, Lee SB, Park SK, Han SR, Kim YI, Lee KS. Periodic limb movement during sleep developed after pontine lesion. *Mov Disord* 2003;18:1403–5.
- [4] Kang SY, Sohn YH, Lee IK, Kim JS. Unilateral periodic limb movement in sleep after supratentorial cerebral infarction. *Parkinsonism Relat Disord* 2004;10:429–31.
- [5] Iriarte J, Alegre M, Arbizu J, de Castro P. Unilateral limb movements during sleep in corticobasal degeneration. *Mov Disord* 2001;16:1180–3.
- [6] Clemens S, Rye D, Hochman S. Restless legs syndrome. Revisiting the dopamine hypothesis from the spinal cord perspective. *Neurology* 2006;67:125–30.
- [7] Bucher SF, Seelos KC, Oertel WH, Reiser M, Trenkwalder C. Cerebral generators involved in the pathogenesis of the restless legs syndrome. *Ann Neurol* 1997;41:639–45.

Andrea O. Rossetti ^{a,b,*}

Raphaël Heinzer ^a

Fabrice Espa ^a

Mehdi Tafti ^{a,c}

^a Centre d'Investigation et Recherche du Sommeil (CIRS),
Lausanne, Switzerland

^b Service de Neurologie, CHUV, Lausanne, Switzerland

^c Centre Intégréatif de Génomique (CIG),

University of Lausanne, Switzerland

E-mail address: andrea.rossetti@chuv.ch (A.O. Rossetti).

Received 17 March 2007; received in revised form 28

June 2007; accepted 28 June 2007

Available online 24 October 2007

* Corresponding author. Address: Service de Neurologie, CHUV-BH07, CH-1011-Lausanne, Switzerland. Tel.: +41 21 314 1220; fax: +41 21 314 1290.

1389-945/\$ - see front matter © 2007 Elsevier B.V. All rights reserved.
doi:10.1016/j.sleep.2007.06.014

Half of patients with obstructive sleep apnea have a higher NREM AHI than REM AHI

To the Editor:

Siddiqui et al. [1] refer to our study [2] quite extensively and for that we are honoured and grateful. They stated, however, that we studied patients with sleep apnea who were being evaluated for potential surgery. That is not actually correct. Our patients, like theirs, were patients presenting to a sleep disorders clinic for evaluation and investigation of suspected sleep