

19. Nakagawa K, Sakaki S, Oka Y, et al. Malignant thymoma with intracranial metastases. *No Shinkei Geka* 1988;**16**:589–95.
20. Nicolato A, Ferraresi P, Bontempini L, et al. Multiple brain metastases from 'lymphoepithelioma-like' thymic carcinoma: a combined stereotactic-radiosurgical approach. *Surg Neurol* 2001;**55**:232–4.
21. Oda Y, Mori K, Watanabe H, et al. Malignant thymoma with cerebral metastasis. *Rinsho Shinkeigaku* 1982;**22**:501–6.
22. Rachmaninoff N, Fentress V. Thymoma with metastasis to the brain. *Am J Clin Pathol* 1964;**41**:618–25.
23. Ramon P, Wallaert B, Lemaitre L, et al. Value of X-ray computed tomography in assessing the extent of invasive lympho-epithelial thymoma in the adult. Therapeutic implications. *Rev Mal Respir* 1986;**3**:105–10.
24. Sanders DB, Ignatiadis PD, Sweet DE. Thymoma with distant metastases. *Trans Am Neurol Assoc* 1976;**101**:286–8.
25. Suzuki N, Ishiyama N, Katada K, et al. Malignant Thymoma with brain metastasis: case report. *Neurol Med Chir* 1981;**21**:891–5.
26. Tamura Y, Kuroiwa T, Doi A, et al. Thymic carcinoma presenting as cranial metastasis with intradural and extracranial extension: case report. *Neurosurgery* 2004;**54**:209–12.
27. Wick MR, Nichols WC, Ingle JN, et al. Malignant, predominantly lymphocytic thymoma with central and peripheral nervous system metastases. *Cancer* 1981;**47**:2036–43.
28. Willis RA. *Pathology of Tumors*. third ed. St Luis: Mosby; 1952, p. 97.
29. Yamamura K, Kubo O, Aoki N, et al. Falx metastasis of thymic carcinoma: a case report and review of literature. *No Shinkei Geka* 1993;**21**:921. p. 921–4.
30. Yoshida A, Shigematsu T, Mori H, et al. Non-invasive thymoma with widespread blood-borne metastasis. *Virchows Arch A Pathol Anat Histol* 1981;**390**:121–6.
31. Travis WD, Brambilla E, Müller-Hermelink HK, et al. *WHO Classification of Tumours. Pathology and Genetics. Tumours of the Lung, Pleura, Thymus and Heart*. Lyon: IARC Press; 2004, pp. 145–247.

doi:10.1016/j.jocn.2005.12.014

Delayed rupture of pre-existing cerebral aneurysm in a young patient with minor head trauma

Cheng-Ta Hsieh, En-Yuan Lin, Tung-Han Tsai, Yung-Hsiao Chiang, Da-Tong Ju *

Department of Neurological Surgery, Tri-Service General Hospital, 325, Cheng-Kung Road section 2, National Defense Medical Center, Taipei 114, Taiwan, Republic of China

Received 4 January 2006; accepted 25 March 2006

Abstract

An intracranial saccular aneurysm is not commonly diagnosed in a patient with head injury. We present a patient with a history of minor head trauma and a CT scan of the brain revealing minimal subarachnoid hemorrhage 17 days prior to admission, complaining of severe headache, dysarthria and focal right limb seizures 3 hours prior to admission. A traumatic aneurysm was suspected based on clinical history and radiological findings including hematoma in the falx region on a CT scan of the brain and an aneurysm of the pericallosal artery on magnetic resonance angiography and four-vessel cerebral angiography. However, at craniotomy, an intracranial non-traumatic saccular aneurysm at the bifurcation of the pericallosal artery was found. The patient recovered fully after successful clipping the aneurysm.

© 2006 Elsevier Ltd. All rights reserved.

Keywords: Head injury; Pre-existing aneurysm; Subarachnoid hemorrhage

1. Introduction

Subarachnoid hemorrhage (SAH) is frequent following head injury.¹ In a large series,² SAH was found in 39% of 753 patients with severe head injury. The overall incidence of traumatic SAH accounts for 15–40% of severe head injuries.³ Rupture of intracranial aneurysms has been reported as a cause and an important differential diagnosis

of traumatic SAH. However, the relationship between head trauma and rupture of a pre-existing intracranial saccular aneurysm is rarely discussed. We report a patient who developed delayed neurological deficits 17 days after traumatic SAH and an intracranial non-traumatic saccular aneurysm of the left pericallosal artery was later diagnosed.

2. Case report

An 18-year-old man who had been previously healthy, had been involved in a traffic accident and suffered a head injury. At that time, he was drowsy, confused and

* Corresponding author. Tel.: +886 2 8792 7177; fax: +886 2 8792 7178.
E-mail address: nogor@mail2000.com.tw (D.-T. Ju).

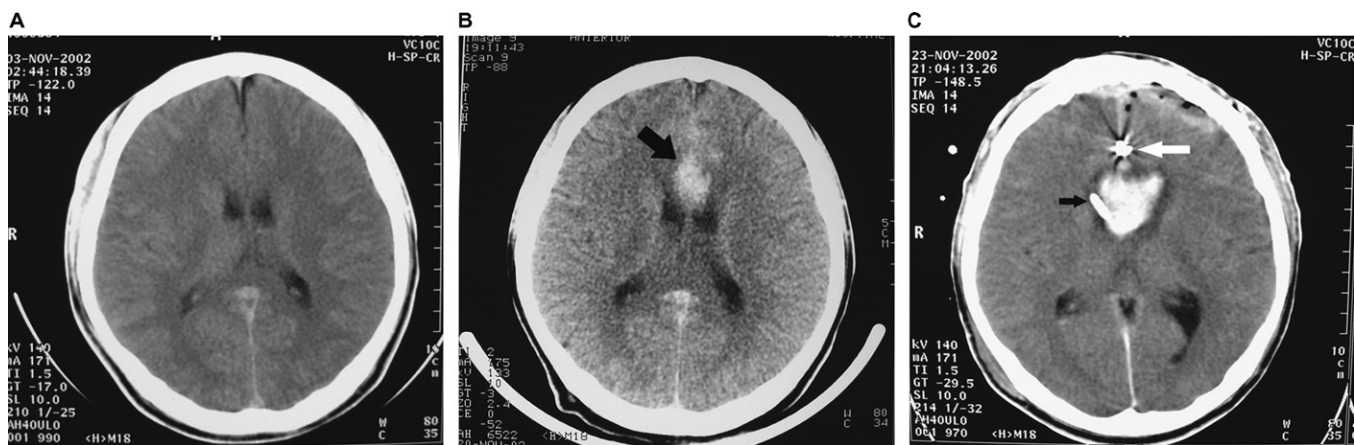

Fig. 1. CT scan of head. (A) 17 days prior to admission reveals no hematoma. (B) Pre-operatively reveals the hematoma (black arrow) in the falx region. (C) Post-operatively reveals the aneurysm clip (white arrow) and shunt tip (black arrow) in the right lateral ventricle.

complained of headache and dizziness. Upon arrival at the emergency room, his Glasgow Coma Scale score (GCS) was 12. Multiple abrasions over the face and fracture of

the right orbital wall were noted. Non-enhanced CT scan (Fig. 1A) of the brain revealed minimal SAH over the bilateral cerebral sulci and traumatic SAH was deduced. Therefore, he was admitted for observation and conservative treatment. Nine days later, he was discharged and neurological deficits were completely resolved. However, severe headache, dysarthria and right focal seizures developed 8 days after discharge. After readmission, he had a GCS of 15. CT scan of the brain (Fig. 1B) revealed diffuse SAH and hematoma in at the falx region. Due to a high degree of suspicion that a cerebral aneurysm had ruptured, MR angiography and four-vessel cerebral angiography were immediately performed which demonstrated an aneurysm of the left pericallosal artery (Fig. 2A, B). Based on the clinical history, presentation, and radiological findings, a traumatic aneurysm was initially suspected. The patient underwent pterional craniotomy and clipping of the aneurysm the same day (Fig. 1C). When surgically exposed, the aneurysm was seen to arise from the bifurcation of the left pericallosal artery and the peripheral brain tissue showed no echymosis. A diagnosis of pre-existing non-traumatic true saccular aneurysm was made. Postoperatively, the patient recovered fully and was discharged after 3 weeks.

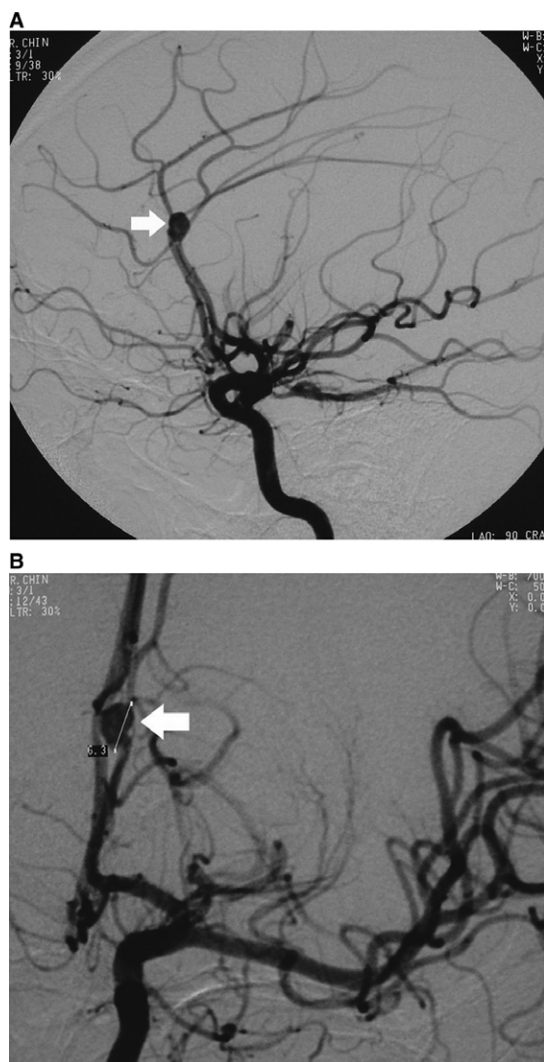


Fig. 2. Left internal carotid angiogram. (A) Lateral view (B) Anteroposterior view. An aneurysm (white arrow) is demonstrated arising from the distal A2 segment of the left anterior cerebral artery.

3. Discussion

Subarachnoid hemorrhage is the most frequent intracranial lesion in patients with head injuries.^{1,4} Based on initial admission CT, the blood, induced by tearing of intracranial arteries or bridging veins on the brain surface,^{1,5} is more frequently located over the cerebral convexities, and less often, in the fissures and basal cisterns.⁴ Usually, convexity SAH is not space-occupying and not life-threatening.⁶ However, traumatic intracranial aneurysms (TICAs) comprise less than 1% of intracranial aneurysms,⁷ and may occur from traumatic events. The etiologies include carotid-cavernous fistula, carotid dissection, carotid thrombosis, blunt vessel injury, penetrating vessel injury and iatrogenic vessel injury.^{5,7} TICAs, also called “false aneurysm” or “pseudoaneurysm”, frequently occur at the distal anterior

cerebral artery, particularly the pericallosal artery, and lay along straight vessels with no branching points nearby.⁸ Because TICAs resemble other true aneurysms, it is an important differential diagnosis in patients with intracerebral hemorrhage or SAH following trauma, with delayed neurological deterioration.⁷

Subarachnoid hemorrhage associated with trauma may be associated with traumatic or non-traumatic aneurysms,⁹ that is, rupture of pre-existing aneurysms, or acute or late development of TICAs. Although 2.8% to 28% of patients with aneurysmal SAH experience head trauma prior to the hemorrhage, the relationship between head trauma and a pre-existing intracranial aneurysm is rarely discussed in the literature. Cummings et al.⁵ reported five (8%) of 60 patients with traumatic SAH harbored pre-existing intracranial saccular aneurysms and the hemorrhage was frequently located in the basal cisterns or sylvian fissure. The relationships between trauma and a pre-existing saccular aneurysm has been summarised as: (i) rupture of aneurysm causing the trauma; (ii) head injury causing rupture of aneurysm; or (iii) unruptured aneurysm incidentally discovered during evaluation of head trauma.⁵

Aneurysmal SAH in patients younger than 40 years of age is uncommon, accounting for 10–20% of SAH.¹⁰ In a study of 295 patients,¹⁰ aneurysms in young adults were commonly located on the anterior communicating artery complex or on the middle cerebral artery. However, in our patient, an aneurysm of the pericallosal artery was found by MR angiography and four-vessel cerebral angiography. Based on the history (recent trauma), time course and clinical presentation, a traumatic pseudo-aneurysm from vessels injured by the falx was initially diagnosed. A saccular “true” aneurysm of the bifurcation of the left pericallosal artery was found during the operation. We suggest the risk of rupture of a pre-existing saccular aneurysm

may be increased by previous trauma, but it is hard to confirm the exact relationship.

In conclusion, pre-existing aneurysms should be considered in the differential diagnosis of patients with SAH following head trauma, especially when hemorrhage is encountered in the basal cisterns or sylvian fissure or when new neurological deficits develop. Accurate clinical history and radiological tools including conventional four-vessel angiography or CT angiogram are essential for early diagnosis and adequate management.

References

1. Kakarieka A. Review on traumatic subarachnoid hemorrhage. *Neurol Res* 1997;**19**:230. p. 230–2.
2. Eisenberg HM, Gary Jr HE, Aldrich EF, et al. Initial CT findings in 753 patients with severe head injury. A report from the NIH Traumatic Coma Data Bank. *J Neurosurg* 1990;**73**:688–98.
3. Cairns CJ, Finfer SR, Harrington TJ, et al. Papaverine angioplasty to treat cerebral vasospasm following traumatic subarachnoid haemorrhage. *Anaesth Intensive Care* 2003;**31**:87–91.
4. Fainardi E, Chiericato A, Antonelli V, et al. Time course of CT evolution in traumatic subarachnoid haemorrhage: a study of 141 patients. *Acta Neurochir (Wien)* 2004;**146**:257–63.
5. Cummings TJ, Johnson RR, Diaz FG, et al. The relationship of blunt head trauma, subarachnoid hemorrhage, and rupture of pre-existing intracranial saccular aneurysms. *Neurol Res* 2000;**22**:165–70.
6. Tatsuno Y, Lindenberg R. Basal subarachnoid hematomas as sole intracranial traumatic lesions. *Arch Pathol* 1974;**97**:211–5.
7. Tan TC, Chan CM, Chiu HM. Traumatic intracranial aneurysm in infancy. *Br J Neurosurg* 2001;**15**:137–9.
8. Senegor M. Traumatic pericallosal aneurysm in a patient with no major trauma. Case report. *J Neurosurg* 1991;**75**:475–7.
9. Suzuki H, Muramatsu M, Shimizu T, et al. Late detection of supraclinoid carotid artery aneurysm after traumatic subarachnoid hemorrhage and occlusion of the ipsilateral cervical internal carotid artery. *Stroke* 2001;**32**:2203–5.
10. Ogungbo B, Gregson B, Blackburn A, et al. Aneurysmal subarachnoid hemorrhage in young adults. *J Neurosurg* 2003;**98**:43–9.

doi:10.1016/j.jocn.2006.03.014

Co-existence of cavernoma and cortical dysplasia in temporal lobe epilepsy

Marco Giuliani^{a,*}, Mino Zucchelli^a, Patrizia Riguzzi^b, Gianluca Marucci^c,
Carlo Alberto Tassinari^b, Fabio Calbucci^a

^a Division of Neurosurgery, Bellaria Hospital, Via Altura 3, 40139, Bologna, Italy

^b Division of Neurology, Bellaria Hospital, Bologna, Italy

^c Department of Oncology, Pathology Section, Bellaria Hospital, Bologna, Italy

Received 25 September 2006; accepted 29 November 2006

* Corresponding author. Tel.: +39 051 6225111; fax: +39 051 6225344.
E-mail address: giulioni.m@tiscali.it (M. Giuliani).