



Pharmacologic Elevation of Blood Pressure for Acute Brain Ischemia

Latha G. Stead · M. Fernanda Bellolio ·
Rachel M. Gilmore · Alyx B. Porter ·
Alejandro A. Rabinstein

Published online: 24 October 2007
© Humana Press Inc. 2007

Abstract

Introduction Several studies demonstrated that patients with low blood pressure upon presentation with acute ischemic stroke have worse outcomes. Elevated mean arterial pressure (MAP) directly improves cerebral perfusion. Phenylephrine is a selective alpha-1 agonist with peripheral vasoconstrictive effect, raising the blood pressure without constricting brain vessels.

Methods We report a 63-year-old lady presenting with an acute high carotid T occlusion causing hemispheric ischemia that was completely reversed by implementing blood pressure augmentation with fluids and intravenous phenylephrine.

Results She arrived 4 h after symptoms onset. At its nadir, the NIHSS was 17. Head CT did not reveal hemorrhage or acute ischemic changes. CT angiogram confirmed the presence of a right internal carotid artery occlusion at the level of the neck. Hemodynamic support in the form of IV normal saline was initiated, followed by a bolus of phenylephrine. The patient responded to blood pressure augmentation with marked improvement in her level of consciousness, therefore an infusion of phenylephrine at 140 mcg/min titrated to a MAP of 110–120 mmHg

was begun. There was complete resolution of the left hemiparesis less than an hour later.

Conclusion This case lends support to the growing body of literature that sustains the use of pharmacological blood pressure augmentation to treat acute brain ischemia. Patients with cervical carotid occlusion represent the ideal candidates for hemodynamic augmentation treatment, as collateral flow can recruited from multiple pathways.

Keywords Pharmacologic elevation of blood pressure · Acute ischemic stroke · Case report

Introduction

We present a case of an acute cervical internal carotid artery occlusion causing a severe hemispheric ischemia that was completely reversed by implementing blood pressure augmentation with fluids and intravenous phenylephrine.

Case Report

A 63-year-old lady was found on the floor by her husband, mute, with left-sided weakness, and urinary incontinence. Her past medical history was remarkable for hypertension treated with a calcium channel blocker. She had no other risk factors for stroke.

She arrived to the Emergency Department 4 h after symptoms onset, and was initially alert, and able to follow commands. On physical exam, she had a forced rightward gaze deviation and left hemiparesis involving face, arm, and leg to the same degree. She neglected her left side and did not respond to visual threat on the left. Her presentation

L. G. Stead (✉)

Division of Emergency Medicine Research, Mayo Clinic
College of Medicine, Rochester, MN, USA
e-mail: Stead.Latha@mayo.edu

M. F. Bellolio · R. M. Gilmore
Department of Emergency Medicine Research, Mayo Clinic
College of Medicine, Rochester, MN, USA

A. B. Porter · A. A. Rabinstein
Department of Neurology, Mayo Clinic College of Medicine,
Rochester, MN, USA

was consistent with a right middle cerebral artery stroke syndrome. Her NIHSS at that time was nine. Over the following 40 min, her mental status fluctuated. She became progressively drowsier and developed complete left hemiplegia. At its nadir, the NIHSS was 17.

Head CT did not reveal hemorrhage or acute ischemic changes. Doppler evaluation demonstrated the right CCA, ECA and the proximal ICA to be patent. However, above the level of the bifurcation, there was marked tortuosity and apparent narrowing of the right ICA with focally elevated velocities (330 cm/s) suggestive of a high-grade stenosis.

CT angiogram of the brain confirmed the presence of a right internal carotid artery occlusion at the level of the neck (Fig. 1).

Hemodynamic support in the form of IV normal saline was initiated, followed by a bolus of phenylephrine. The patient responded to blood pressure augmentation with marked improvement in her level of consciousness (Fig. 2), therefore an infusion of phenylephrine at 140 mcg/min titrated to a mean arterial pressure of 110–120 mmHg was begun. There was complete resolution of the left hemiparesis less than an hour later.

The patient was admitted to the Neuro Intensive Care Unit. A transcranial Doppler (TCD) was performed on the second day of admission and the findings were consistent with persistent ICA occlusion.

The phenylephrine infusion was slowly weaned 36 h after the patient admission. The patient was closely monitored, and neurological symptoms did not recur during the 24 h period that it took to decrease the doses of the vasopressor.

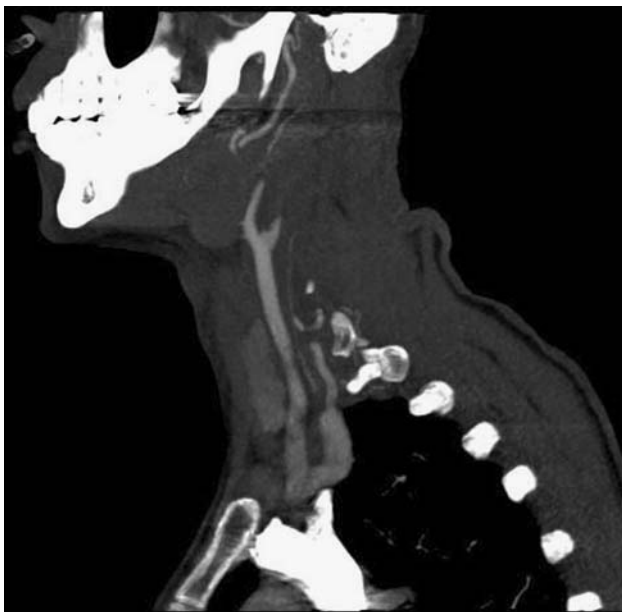


Fig. 1 CT angiogram demonstrating high carotid stenosis

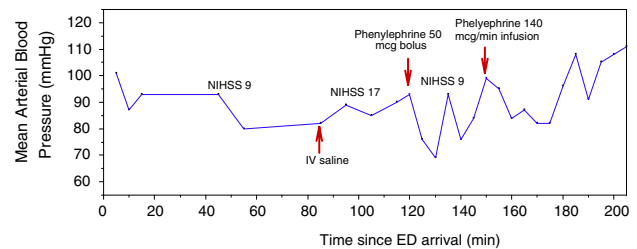


Fig. 2 Emergency Department timeline: Mean Arterial Blood Pressure (mmHg), NIHSS and pharmacologic interventions

Intravenous heparin was initiated once repeat head CT failed to reveal acute infarction. She was subsequently started on warfarin, in addition to a daily 81 mg aspirin. She was discharged on day 4, with a complete normal neurologic examination. Anticoagulation was continued for the following 3 months for her carotid occlusive disease.

Discussion

The management of blood pressure in acute ischemic stroke continues to be a controversial topic, with the latest debate surrounding the optimal management of hypotension, as guidelines for the management of elevated blood pressures is quite well accepted [1]. Several studies including our own have demonstrated that patients with low blood pressure upon initial presentation have worse outcomes [2–6].

We have previously demonstrated that there appears to be a lower limit of blood pressure below which the risk of death at 90 days increases significantly, independent of stroke severity [2, 3]. We hypothesize that below this threshold, the penumbra is irreversibly compromised, leading to extension of infarct and poor outcome. We further hypothesize that improvement of clinical outcome may be achieved with blood pressure augmentation.

Elevated mean arterial pressure (MAP) directly improves cerebral perfusion, rather than simply optimizing the patient overall. The penumbra, or tissue at risk, is thought to either return to normal, or convert to infarct 36–48 h after the stroke onset [7, 8].

Phenylephrine is a selective alpha-1 agonist. Alpha-1 receptors are the most prominent in the peripheral vasculature, and relatively sparse in the cerebral vasculature, allowing its vasoconstrictive effect to raise blood pressure without constricting brain vessels, which would compromise cerebral perfusion. Its feasibility of administration, safety profile, and tolerability have been well established. It has also been used in patients with ischemic stroke, a patient population that is generally less critically ill than those with sepsis or multi-organ failure. Thus far, eight studies including a total of 152 patients report adverse

effects of treatment with intravenous phenylephrine comparable to control groups, in patients with symptom onset ranging from <24 h to 10 days [9–16].

The 2007 American Stroke Association guidelines for management of acute ischemic stroke [1] recommended that in exceptional cases, a physician might prescribe vasopressors to improve cerebral blood flow. If drug-induced hypertension is used, close neurological and cardiac monitoring is recommended (Class I, Level of Evidence C), and also advise that drug-induced hypertension, outside the setting of clinical trials, is not recommended for treatment of most patients with acute ischemic stroke (Class III, Level of Evidence B). This case lends support to the growing body of literature that supports the use of pharmacological blood pressure augmentation to treat acute brain ischemia. Patients with cervical carotid occlusion represent the ideal candidates for hemodynamic augmentation treatment, as collateral flow could be recruited from multiple pathways (external carotid branches, contralateral internal carotid via anterior communicating artery, and posterior circulation via posterior communicating artery).

References

1. Adams HP Jr, del Zoppo G, Alberts MJ, Bhatt DL, Brass L, Furlan A, Grubb RL, Higashida RT, Jauch EC, Kidwell C, Lyden PD, Morgenstern LB, Qureshi AI, Rosenwasser RH, Scott PA, Wijdicks EF. American Heart Association; American Stroke Association Stroke Council, Clinical Cardiology Council, Cardiovascular Radiology and Intervention Council, and the Atherosclerotic Peripheral Vascular Disease and Quality of Care Outcomes in Research Interdisciplinary Working Groups. Guidelines for the early management of adults with ischemic stroke: a guideline from the American Heart Association/American Stroke Association Stroke Council, Clinical Cardiology Council, Cardiovascular Radiology and Intervention Council, and the Atherosclerotic Peripheral Vascular Disease and Quality of Care Outcomes in Research Interdisciplinary Working Groups. *Stroke* 2007;38:1655–711.
2. Stead LG, Gilmore RM, Decker WW, Weaver AL, Brown RD Jr. Initial emergency department blood pressure as predictor of survival after AIS. *Neurology* 2005;65:1179–83.
3. Stead LG, Decker WW, Weaver AL, Brown RD Jr. Does emergency department blood pressure determine survival following acute ischemic stroke? *Acad Emerg Med* 2004;11:539–40.
4. Oliveira-Filho J, Silva SCS, Trabuco CC, Pedreira BB, Sousa EU, Bacellar A. Detrimental effect of blood pressure reduction in the first 24 hours of acute stroke onset. *Neurology* 2003;61:1047–51.
5. Vleck M, Schillinger M, Lang W, Lalouscheck W, Bur A, Hirschl MM. Association between course of blood pressure within the first 24 hours and functional recovery after acute ischemic stroke. *Ann Emerg Med* 2003;42:619–26.
6. Castillo J, Leira R, Garcia MM, et al. Blood pressure decrease during the acute phase of ischemic stroke is associated with brain injury and poor stroke outcome. *Stroke* 2004;35:520–6.
7. Beauchamp N, Bryan RN. Acute Cerebral Ischemic Infarction: a pathophysiologic review and radiologic perspective. *Am J Roentgenol* 1998;171:73–84.
8. Heiss W. Quantitative neuroimaging for the evaluation of the effect of stroke treatment. *Cerebrovasc Dis* 1998;8:23–9.
9. Hillis AE, Wityk RJ, Beauchamp NJ, Ulatowski JA, Jacobs MA, Barker PB. Perfusion-weighted MRI as a marker of response to treatment in acute and subacute stroke. *Neuroradiology* 2004;46:31–9.
10. Rordorf G, Cramer SC, Efirid JT, Schwamm LH, Buonanno F, Koroshetz WJ. Pharmacological elevation of blood pressure in acute stroke: clinical effects and safety. *Stroke* 1997;28:2133–8.
11. Rordorf G, Koroshetz WJ, Ezzeddine MA, Segal AZ, Buonanno FS. A pilot study of drug-induced hypertension for treatment of acute stroke. *Neurology* 2001;56:1210–3.
12. Hillis AE, Kane A, Tuffiash E, Ulatowski JA, Barker PB, Beauchamp NJ, Wityk RJ. Reperfusion of specific brain regions by raising blood pressure restores selective language functions in subacute stroke. *Brain Lang* 2001;79:495–510.
13. Hillis AE, Barker PB, Beauchamp NJ, Winters BD, Mirski M, Wityk RJ. Restoring blood pressure reperfused Wernicke's area and improved language. *Neurology* 2001;56:670–2.
14. Hillis AE, Ulatowski JA, Barker PB, Torbey M, Ziai W, Beauchamp NJ, Oh S, Wityk RJ. A pilot randomized trial of induced blood pressure elevation: effects on function and focal perfusion in acute and subacute stroke. *Cerebrovasc Dis* 2003;16:236–46.
15. Koenig MA, Geocadin RG, de Grouchy M, Glasgow J, Vimal S, Restrepo L, Wityk RJ. Safety of induced hypertension therapy in patients with acute ischemic stroke. *Neurocrit Care* 2006;4:3–7.
16. Marzan AS, Hungerbuhler HJ, Studer A, Baumgartner RW, Georgiadis D. Feasibility and safety of norepinephrine-induced arterial hypertension in acute ischemic stroke. *Neurology* 2004;62:1193–5.