

Vascular

Successful surgical treatment of a hemophiliac infant with nontraumatic acute subdural hematoma

Naci Balak, MD^a, Gökalep Silav, MD^a, Yilmaz Kiliç, MD^a, Çetin Timur, M.D.^b, İlhan Elmaci, MD^{a,*}

Departments of ^aNeurosurgery and ^bPaediatric Haematology, Göztepe Education and Research Hospital, Istanbul, TR-34740, Turkey

Received 14 May 2006; accepted 21 November 2006

Abstract

Background: The moderate hemophiliacs usually have no spontaneous bleeding, but bleed after minor or major trauma. The proper management of intracranial hemorrhage in hemophiliac children is a challenge.

Case Description: An 18-month-old male infant with moderate hemophilia A was admitted with fever, vomiting, and hypersomnia. There was no history of trauma or seizure. The CT scans showed an acute subdural hematoma in the right temporoparietooccipital region with midline shift and a coincidental right cerebellar arachnoid cyst. After bolus factor VIII replacement, a right temporoparietal craniotomy was performed, and the subdural hematoma was evacuated. The postoperative CT scans demonstrated no hematoma.

Conclusions: The possibility of intracranial hemorrhage in a moderate hemophiliac infant should be considered even if the patient has no history of trauma. The surgical treatment results in a successful outcome in hemophiliac children with subdural hematomas provided that an aggressive factor replacement therapy is initiated before surgery.

© 2007 Elsevier Inc. All rights reserved.

Keywords:

Hemophilia; Infants; Intracranial bleeding; Subdural hematoma

1. Introduction

Intracranial hemorrhage is an important cause of mortality and morbidity in patients with hemophilia [2,6,9]. Recurrences, sequels with seizures, mental retardation, and motor deficit are frequent [3,10]. Nuss et al reported that the incidence of hemophilia-associated intracranial hemorrhage is 0.0054 case per year including all ages [13]. In hemophiliac children, the prevalence and incidence of intracranial hemorrhage were reported to be 12% and 2%, respectively [12]. Trauma at birth or other traumas are the most frequent causes of intracranial bleeding in hemophiliacs [8,9]. However, the relationship of intracranial hemorrhage to preceding trauma is not always clear. There is no apparent cause of bleeding in about one third of the pediatric hemophiliacs with intracranial bleeding [9,12]. About 16% to 30% of all intracranial bleedings in hemophiliacs are subdural hematomas [9,12].

The generally recommended management in hemophiliacs with intracranial hemorrhage is conservative by factor replacement therapy [7]. Neurosurgery in a child with hemophilia may be considered only when the patient has life-threatening central nervous system bleeding [5,7]. We report a case of spontaneous acute subdural hematoma in an 18-month-old infant with hemophilia A. After replacement of factor VIII, the subdural hematoma was evacuated with craniotomy. Postoperative course of the patient was uneventful.

2. Case report

An 18-month-old male infant was seen at the pediatric emergency ward because of fever, vomiting, and hypersomnia. His history revealed that he had been diagnosed to

Abbreviations: aPTT, Activated partial thromboplastin time; CT, Computed tomography; PT, Prothrombin time.

* Corresponding author. Bagdat Cad. 505, D:4, Suadiye, Kadiköy, Istanbul, Turkey, TR-34740. Tel.: +90 216 372 8780; fax: +90 216 372 8780.

E-mail address: ilhanelmaci@yahoo.com (I. Elmaci).

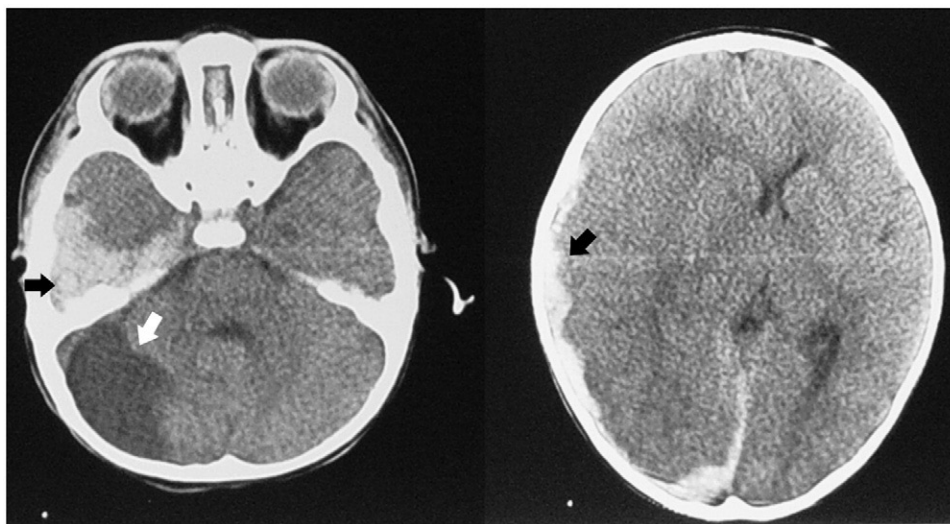


Fig. 1. The preoperative CT scans demonstrating an acute subdural hematoma in the right temporoparietooccipital region with midline shift (black arrows) and a coincidental right cerebellar arachnoid cyst (white arrow).

have hemophilia A, after bruises appeared on his fingertips at 4 months of age. There were no family members with hemophilia. On neurological examination, his pediatric coma score was 11 (best overall = 12, from Reilly et al [15]), without focalizing sign. There was no history of trauma or seizure. His hemoglobin level and platelet count were 7.2 g/dL and $451 \times 10^3/\mu\text{L}$, respectively. A factor VIII assay was requested at this time and was found to be 2% of normal. Immediately, an initial bolus of 500 U of factor VIII concentrate was administered. Subsequently, a cranial CT was carried out for the decreased coma score of the patient. The CT scans showed an acute subdural hematoma in the right temporoparietooccipital region with midline shift and a coincidental right cerebellar arachnoid cyst (Fig. 1). Medical therapy was continued by 60 U/kg every 8 hours of factor VIII and dexamethasone. After 12 hours, his coagulation profile showed PT = 12.5 seconds (normal PT = 12 seconds)

and aPTT = 38.5 seconds (normal aPTT = 26–40 seconds). Despite good laboratory response, the patient deteriorated toward a lower coma score. Thus, surgical intervention was decided because of the high risk of herniation. A right temporoparietal craniotomy was performed, and the subdural hematoma was evacuated. No excessive bleeding was evident in the operation. However, the patient was transfused 100 mL of pocket red blood cells intraoperatively because of his low hemoglobin value. Postoperative course was uneventful, and the patient was extubated. His postoperative hemoglobin was 8.1 g/dL. Ten hours after surgery, the CT scans showed no hematoma (Fig. 2). The therapy was maintained by factor VIII concentrate at 60 U/kg every 8 hours for 1 day, 60 U/kg every 12 hours for the following 7 days, and 60 U/kg every 24 hours for an additional 7 days. Result of a neurological examination at the time of discharge was normal.

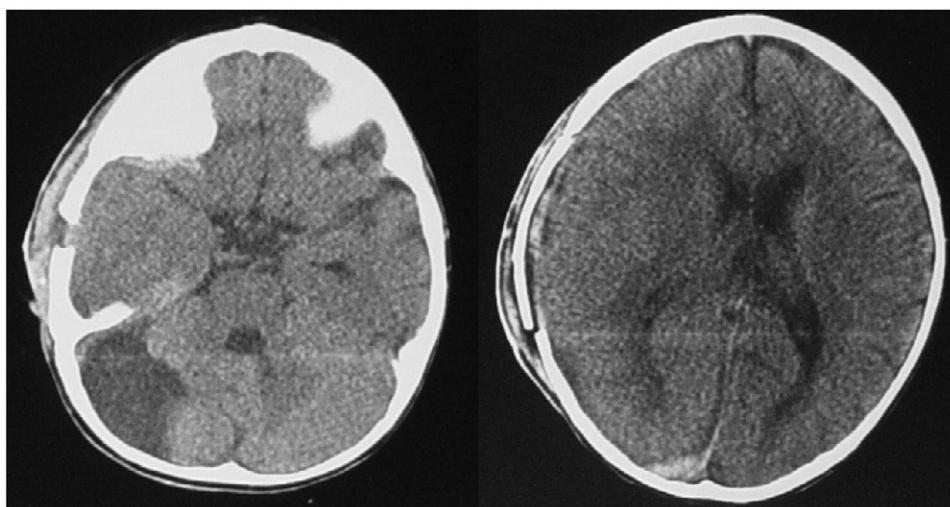


Fig. 2. The postoperative CT scans showing no hematoma.

3. Discussion

Bleeding disorders such as hemophilia, an X-linked coagulation disorder due to deficiency of factor VIII (hemophilia A) or factor IX (hemophilia B), account for a small but significant risk factor associated with intracranial hemorrhage [11,14]. The frequency of intracranial hemorrhage is high in young patients with hemophilia, with a median age of 2 years [9].

Severe and moderate hemophiliacs bleed more frequently than mild cases with hemophilia (severe, having less than 1% of the factor level; moderate, having 2%–5% of the factor level; mild, having 6%–20% of the factor level) [1,8]. Severe cases bleed spontaneously into joints and muscles. The moderate hemophiliacs have no spontaneous bleeding, but usually bleed after minor or major trauma [8]. In mild hemophiliacs, greater trauma is necessary for bleeding [8]. In hemophiliac children, intracranial hemorrhage is usually preceded by head trauma, in contrast to adults where 50% of cases occur without injury [4,8,11]. Our patient had moderate hemophilia, but had no known history of trauma. Therefore, the possibility of intracranial hemorrhage in a hemophiliac infant should always be considered in the emergency ward even if the patient has no history of trauma.

Surgery for subdural hematomas in hemophiliac children is debatable. Neurosurgery is generally avoided in hemophiliac children with intracranial hemorrhage [5,7]. On the other hand, Eyster et al stated that the indications for surgery in hemophiliacs with intracranial bleeding were similar to those for nonhemophiliacs with intracranial bleeding [8]. Furthermore, successful evacuation of subdural and intracerebral hematoma in a hemophiliac child was reported [5]. Eyster et al reported a 36.9% mortality rate in the cases with intracranial bleeding and a 10% mortality rate in the cases with subdural hematomas [8]. Although they wrote that they usually evacuated subdural hematomas, they did not mention in their article whether this rate of mortality belonged to the surgical or nonsurgical group of cases. Myles et al reported intracranial bleeding in 2 neonates with hemophilia A. Both of the patients were operated on, with the patient who was not treated with factor VIII preoperatively having poorer outcome [11]. Yue and Mann reported surgical treatment of 8 cases of subdural hematomas in hemophiliac children without deaths [17]. Nevertheless, surgical intervention may be dangerous in some circumstances. For instance, intracranial hemorrhage may be the first sign of hemophilia in infants who are not presented with the classical or obvious findings to make a diagnosis of hemophilia [11]. Therefore, some authors advised that prophylactic clotting therapy should be administered during surgery in all full-term male babies presenting with intracranial hemorrhage to prevent postoperative bleeding in an undiagnosed hemophiliac [11]. Concisely, there is uncertainty in the literature about the proper therapy for intracranial hemorrhages in hemophiliacs. This may lead to

delay in the management of these urgent cases. Furthermore, it is unclear how long one should wait before attempting cranial surgery if the laboratory coagulation profile does not show reasonable values despite replacement of bolus factor VIII.

Previous literature shows that cranial surgery in hemophiliac children is hazardous without prophylactic factor replacement [11]. In our case report, the patient was treated with the factor VIII replacement before and after surgery and had an excellent outcome. Avoiding neurosurgery and adopting a conservative management only in hemophiliacs result in higher mortality due to uncal herniation [16]. Andes et al drew attention that no hemophiliac patient given coagulation factor within 6 hours of head injury experienced intracranial hemorrhage [2]. Our case illustrates that neurosurgical treatment may be considered and results in a good outcome in hemophiliac children with subdural hematomas provided that preoperative diagnosis of hemophilia is made and an aggressive factor replacement therapy is initiated before surgery.

Acknowledgment

We thank Ms Roxanne McGrath for her assistance with the English translation.

References

- [1] Agrawal D, Mahapatra AK. Spontaneous subdural hematoma in a young adult with hemophilia. *Neurol India* 2003;51:114–5.
- [2] Andes WA, Wulff K, Smith WB. Head trauma in hemophilia. A prospective study. *Arch Intern Med* 1984;144:1981–3.
- [3] Bentancor N, Lavallo E, Vila VM, et al. Intracranial hemorrhage in hemophiliacs. Study of 10 episodes [in Spanish]. *Sangre (Barc)* 1992;37:43–6.
- [4] Bray GL, Luban NL. Hemophilia presenting with intracranial hemorrhage. An approach to the infant with intracranial bleeding and coagulopathy. *Am J Dis Child* 1987;141:1215–7.
- [5] Cermelj M, Negro F, Schijman E, et al. Neurosurgical intervention in a haemophilic child with a subdural and intracerebral haematoma. *Hemophilia* 2004;10:405–7.
- [6] De Tezanos Pinto M, Fernandez J, Perez Bianco PR. Update of 156 episodes of central nervous system bleeding in hemophiliacs. *Haemostasis* 1992;22:259–67.
- [7] Doughty HA, Coles J, Parmar K, Bullock P, Savidge GF. The successful removal of a bleeding intracranial tumour in a severe haemophilic using adjusted dose continuous infusion of monoclonal factor VIII. *Blood Coagul Fibrinolysis* 1995;6:31–4.
- [8] Eyster ME, Gill FM, Blatt PM, et al. Central nervous system bleeding in hemophiliacs. *Blood* 1978;51:1179–88.
- [9] Klinge J, Auberger K, Auerswald G, et al. Prevalence and outcome of intracranial haemorrhage in haemophiliacs—a survey of the paediatric group of the German Society of Thrombosis and Haemostasis (GHT). *Eur J Pediatr* 1999;158(Suppl 3):162–5.
- [10] Leblanc R, O’Gorman AM. Neonatal intracranial hemorrhage. A clinical and serial computerized tomographic study. *J Neurosurg* 1980;53:642–51.
- [11] Myles LM, Massicotte P, Drake J. Intracranial hemorrhage in neonates with unrecognized hemophilia A: a persisting problem. *Pediatr Neurosurg* 2001;34:94–7.

- [12] Nelson MD, Maeder MA, Usner D, et al. Prevalence and incidence of intracranial haemorrhage in a population of children with hemophilia. *Hemophilia* 1999;5:306–12.
- [13] Nuss R, Soucie JM, Evatt B. Changes in the occurrence of and risk factors for hemophilia-associated intracranial hemorrhage. *Am J Hematol* 2001;68:37–42.
- [14] Quinones-Hinojosa A, Gulati M, Singh V, et al. Spontaneous intracerebral hemorrhage due to coagulation disorders. *Neurosurg Focus* October, 2003;15(4):doc.3.
- [15] Reilly PL, Simpson DA, Sprod R, et al. Assessing the conscious level of infants and young children: a paediatric version of the Glasgow Coma Scale. *Child's Nerv Syst* 1988;4:30–3.
- [16] Shih SL, Lin JC, Liang DC, et al. Computed tomography of spontaneous intracranial haemorrhage due to haemostatic disorders in children. *Neuroradiology* 1993;35:619–21.
- [17] Yue CP, Mann KS. The surgical management of intracranial hematomas in hemophilic children. A prospective study. *Child's Nerv Syst* 1986;2:5–9.

Commentary

This is an interesting and innovative contribution. Albeit it addresses a condition thoroughly discussed by others, it is certainly worthy of publication. The practical approach of a geographically distant colleague may prove to be inspiring for the practice of the reader and beneficial for a particular patient.

Congratulations to the authors for a commitment to the patient's well-being and for teaming medicine with surgery.

Jorge Lazareff, MD

*Department of Neurosurgery
University of California Los Angeles (UCLA)
Los Angeles, CA 90095*