

# Congenital Aneurysm Presenting as Peripheral Facial Paresis

S. Iglesias<sup>a</sup> J. Hinojosa<sup>a</sup> J. Esparza<sup>a</sup> A. Muñoz<sup>b</sup> A. Otero<sup>a</sup>

<sup>a</sup>Pediatric Neurosurgical Department and <sup>b</sup>Neuroradiology Section, Hospital 12 de Octubre, Madrid, Spain

## Key Words

Congenital aneurysm · Facial paresis · Intracerebral hematoma

## Abstract

The incidence of intracranial aneurysms in infancy is relatively rare. They are infrequent in children less than 1 year old, and are an exception in the neonatal period. They usually originate in the internal carotid artery bifurcation, posterior circulation and seldom in the territory of the distal middle cerebral artery distribution. Infants often present with nonspecific symptoms: irritability, lethargy, vomiting, seizures and coma. Sometimes, they may present with unexpected clinical symptoms such as peripheral facial palsy. Subarachnoid hemorrhage is the most frequent presentation in this kind of aneurysms. Intracerebral hematoma is unusual. We present the case of a 10-week-old child harboring a middle cerebral artery aneurysm. To our knowledge, this is the first case of an aneurysm presenting as a peripheral facial paresis in a pediatric patient.

Copyright © 2007 S. Karger AG, Basel

## Introduction

The incidence of intracranial aneurysms in infancy is relatively rare. They usually originate in the internal carotid artery bifurcation, posterior circulation and seldom

in the territory of the distal middle cerebral artery distribution [1–4]. Infants often present with nonspecific symptoms: irritability, lethargy, vomiting, seizures and coma [5]. Subarachnoid hemorrhage is the most frequent presentation in this type of aneurysms.

We present the case of a 10-week-old child harboring a middle cerebral artery aneurysm. To our knowledge, this is the first case of an aneurysm presenting as a peripheral facial paresis in a pediatric patient.

## Case Report

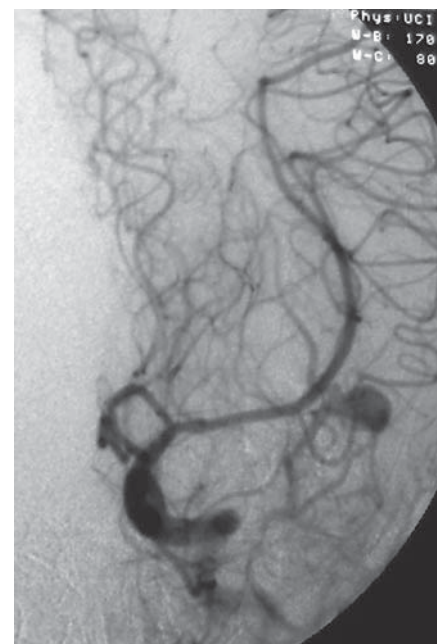
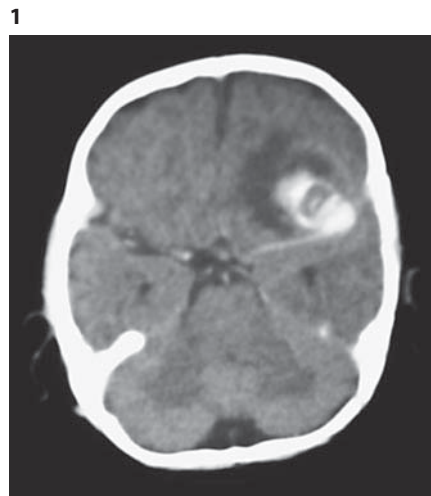
We report the case of a 10-week-old infant who presented to the Emergency Department with vomiting, diarrhea and hyporexia for the last 2 days. Past medical history and family history were unremarkable. Physical examination revealed irritability, drowsiness and seventh nerve peripheral paresis in the left side unnoticed until this moment by his family. He was able to move all extremities equally. Muscular tone and reflexes were all normal.

Computed tomography of the head revealed a left frontal lobe intracerebral hematoma associated with subarachnoid hemorrhage (fig. 1). Subsequent arteriography revealed a cerebral aneurysm arising from the left middle cerebral artery bifurcation (fig. 2).

Elective surgery was chosen and a left frontotemporal craniotomy performed. The hematoma was evacuated and the aneurysm sac was clipped and resected after coagulation and modeling of the neck. Postoperative course was uneventful. At the time of discharge he was asymptomatic. Facial paresis resolved completely within 3 months. No related congenital disorders have been found in the work-up.

**Fig. 1.** Axial unenhanced computed tomography scan demonstrating left frontal lobe intracerebral hematoma and associated subarachnoid hemorrhage.

**Fig. 2.** Left ICA angiogram, lateral view, revealing a cerebral aneurysm arising from the left middle cerebral artery bifurcation.



## Discussion

Intracranial aneurysms are relatively infrequent in the pediatric population, with a reported prevalence ranging from 0.5 to 4.6% of total intracranial aneurysms in large series [1–4]. In children less than 1 year old, they are even less frequent, accounting for 18% of childhood aneurysms and approximately 1% of aneurysms at any age [5].

Aneurysms in infants exhibit some well-known special features. Male predominance and predilection for internal carotid artery bifurcation or distal middle cerebral artery location have been reported [1–3, 5]. Posterior circulation aneurysms occur more frequently in children than in adults. Infants also seem to have a higher incidence of large/giant aneurysms and increased risk of aneurysms rupture [2–5]. Etiology is more likely to be traumatic or infectious. The most frequent presentation is subarachnoid hemorrhage. Intracerebral hematoma, as in the present case, is unusual [1, 4, 5].

It is well known that aneurysms in infants are sometimes associated with congenital disorders. Polycystic kidney disease, aortic coarctation, sickle cell anemia, type IV Ehlers-Danlos syndrome, type IV collagenopathy and pseudoxantoma elasticum are some of them [4–6].

Clinical presentation often consists of irritability, lethargy, vomiting, seizures and coma [5]. To our knowledge, a prior case in which peripheral facial paresis was a clinical feature of aneurysm in a pediatric patient has not been documented.

There are several explanations in the literature regarding pathophysiological aspects of peripheral facial paresis in the context of intracranial diseases.

Peripheral facial palsy could be secondary to direct compression of neural structures. A few reports of adult aneurysms and one report of cerebral venous thrombosis support this hypothesis [6–9].

Although not directly related to the current case, in a second theory, infections and other inflammatory diseases of the central nervous system have been associated with cranial nerve paralysis by a direct injury mechanism.

Yet another theory purports intracranial hypertension as the main factor in peripheral seventh nerve paresis by means of two different mechanisms. The increased intraluminal pressure in the nerve's satellite veins could either cause a reversible compromise in oxygen or glucose consumption or lead to venous blood brain barrier dysfunction with leakage of fluid and ions into the endoneurial space. Both mechanisms could account for neurapraxia. This theory could explain cases related to cerebral venous thrombosis or hydrocephalus reported in the literature [9, 10].

Some authors refer to arterial hypertension as one of the rare causes of peripheral facial paralysis in children, without relation to cerebral vascular diseases [11, 12].

We suggest intracranial hypertension as the main pathophysiological feature in the present case.

The therapeutic options for pediatric aneurysms are the same as those applied in adult patients. These options con-

sist of surgery and interventional neuroradiological techniques [13, 14]. Embolization performed using Guglielmi detachable coils is associated with a lower risk of complications and a lower percentage of complete occlusion mainly in giant aneurysms where recanalization or coil compaction may occur [2, 3]. Surgical clipping with parent artery preservation is an elective option, when is possible [5, 13]. Hunterian ligature of the afferent artery or trapping of the arterial segment harboring the aneurysm may be necessary in some cases with bypass or reconstruction of the artery. It should also be kept in mind that aneurysms in infants can spontaneously thrombose [2, 3, 5, 13, 14].

## Conclusion

Congenital aneurysms are rare and sometimes may present with unexpected clinical symptoms. We should be aware of the association of peripheral facial paresis with vascular diseases by different pathophysiological mechanisms because it could prevent delays in the diagnosis. The election of surgical clipping versus interventional endovascular techniques may vary depending on the surgeon's preference and experience, availability of endovascular treatment and characteristics and topography of the aneurysms to treat.

## References

- Huang J, McGirt MJ, Gailloud P, Tamargo RJ: Intracranial aneurysms in the pediatric population: case series and literature review. *Surg Neurol* 2005;63:424–433.
- Krapf H, Schöning M, Petersen D, Küker W: Complete asymptomatic thrombosis and resorption of a congenital giant intracranial aneurysm. *J Neurosurg* 2002;97:184–189.
- Gallia GL, Moore C, Jordan L, Gailloud P, Jallo G: Neonatal cavernous carotid artery aneurysm. *J Neurosurg* 2005;102:332–337.
- Motohashi O, Kameyama M, Imaizumi S, Mino M, Naganuma H, Ishii K, Onuma T: A distal anterior cerebral artery aneurysm in infant: disappearance and reappearance of the aneurysm. *J Clin Neurosci* 2004;11:86–88.
- Young WF, Pattisapu JV: Ruptured cerebral aneurysm in a 39-day-old infant. *Clin Neurol Neurosurg* 2000;102:140–143.
- Terao S, Hara K, Yoshida K, Ohira T, Kawase T: A giant internal carotid-posterior communicating artery aneurysm presenting with atypical trigeminal neuralgia and facial nerve palsy in a patient with autosomal dominant polycystic kidney disease: a case report. *Surg Neurol* 2001;56:127–131.
- Kurokawa R, Saito R, Nakamura Y, Kagami H, Ichikizaki K: Ruptured vertebral artery-posterior inferior cerebellar artery aneurysm associated with facial nerve paresis successfully treated with interlocking detachable coils. *Neurol Med Chir (Tokyo)* 1999;39:863–866.
- Constantino PD, Russell E, Reisch D, Breit RA, Hart C: Ruptured petrous carotid aneurysm presenting with otorrhagia and epistaxis. *Am J Otol* 1991;12:378–383.
- Straub J, Magistris MR, Delavelle J, Landis T: Facial palsy in cerebral venous thrombosis. Transcranial stimulation and pathophysiological considerations. *Stroke* 2000;31:1766–1769.
- Uldry PA, Fankhauser H, de Tribolet N: Trigeminal involvement and peripheral facial paralysis caused by Arnold-Chiari malformation with hydrocephalus. *Neurochirurgie* 1985;31:73–75.
- Harms MM, Rottevel JJ, Kar NC, Gabreels FJ: Recurrent alternating facial paralysis and malignant hypertension. *Neuropediatrics* 2000;31:318–320.
- Aynaci FM, Sen Y: Peripheral facial paralysis as initial manifestation of hypertension in a child. *Turk J Pediatr* 2002;44:73–75.
- Zhang YJ, Barrow DL, Day AL: Extracranial-intracranial vein graft bypass for giant intracranial aneurysm surgery for pediatric patients: two technical case reports. *Neurosurg* 2002;50:663–668.
- Song JK, Niimi Y, Brisman JL, Fernandez PM, Berenstein A: Multiple cerebral aneurysms in a neonate. *J Neurosurg* 2005;102:81–85.

Copyright: S. Karger AG, Basel 2007. Reproduced with the permission of S. Karger AG, Basel.  
Further reproduction or distribution (electronic or otherwise) is prohibited without permission  
from the copyright holder.