

Short communication

A pathogenic mutation on exon 21 of the *NOTCH3* gene causing CADASIL in an octogenarian paucisymptomatic patient

Francesca Pescini^a, Silvia Bianchi^b, Emilia Salvadori^a, Anna Poggesi^a, Maria Teresa Dotti^b, Antonio Federico^b, Domenico Inzitari^a, Leonardo Pantoni^{a,*}

^a Department of Neurological and Psychiatric Sciences, University of Florence, Italy

^b Department of Neurological and Behavioural Sciences, University of Siena, Italy

Received 8 August 2007; received in revised form 28 September 2007; accepted 4 October 2007

Available online 19 November 2007

Abstract

CADASIL (Cerebral Autosomal Dominant Arteriopathy with Subcortical Infarcts and Leukoencephalopathy) is an inherited small vessel disease causing migraine, early strokes, cognitive impairment and premature death. The disease is caused by *NOTCH3* gene puntiform mutations on one of the exons coding for the epidermal-growth factor (EGF)-like repeats of the extracellular domain of the NOTCH3 receptor. Mutations have been reported with higher frequency on some exons, and never on 6 out of a total of 23. We report for the first time a mutation (c.3471C>G) on exon 21 of the *NOTCH3* gene that leads to a cysteine substitution (p.1131C>W) in the EGF-like repeat 29 of the NOTCH3 receptor extracellular domain, and that is responsible for CADASIL in a functionally independent elderly man who came to our attention at the age of 79 because of a minor stroke. CADASIL suspicion aroused only from the finding of severe white matter changes extended to the temporopolar region on cerebral magnetic resonance imaging. This case report underlines that, when CADASIL is suspected, molecular analysis should be performed on all the *NOTCH3* exons coding for EGF-like repeats and not be limited to those where mutations have been found with higher frequency, and that the disease may be encountered also in mildly symptomatic elderly patients. The newly reported mutation might sustain a milder expressivity of the disease. © 2007 Elsevier B.V. All rights reserved.

Keywords: CADASIL; NOTCH3; Aging; Genotype; Phenotype; Leukoencephalopathy; Magnetic resonance imaging; Stroke

1. Introduction

CADASIL is an inherited small vessel disease causing cerebral periventricular and deep white matter changes (typically extending to the temporopolar region) and multiple lacunar infarcts in the basal ganglia and brainstem [1,2]. The main clinical manifestations are migraine more often with aura, early onset of stroke (30–50 years) and cognitive decline (50–60 years), psychiatric disturbances, and epilepsy [3–5]. The disease has a progressive course and severe disability and dementia develop in about three fourth of the patients at the end stage [6]. Premature death has been reported (at median age of 65 years for men and 71 years for women) [6].

The disease is caused by mutations in one of the exons (from 2 to 24) of the *NOTCH3* gene coding for the EGF-like repeat domains of the extracellular portion of the NOTCH3 receptor. Mainly, these are missense mutations leading to a cysteine substitution in the receptor [7,8]. Clustering of mutations on exons 3, 4, 5, 8, and 11 has been reported [8,9], while until now mutations on 6 exons (12, 13, 16, 17, 21, and 24) have never been published.

Here, we describe for the first time a missense mutation on exon 21 of the *NOTCH3* gene responsible for CADASIL in a minimally affected 82-year-old patient.

2. Materials and methods

Following informed consent, total genomic DNA was extracted from peripheral blood leucocytes using standard procedures. Polymerase chain reaction (PCR) was performed with primers (comprising intron–exon boundaries) specific

* Corresponding author. Department of Neurological and Psychiatric Sciences, University of Florence, Viale Morgagni 85, 50134 Florence, Italy. Tel.: +39 055 7947995; fax: +39 055 4298461.

E-mail address: pantoni@neuro.unifi.it (L. Pantoni).

for exons 2–24 of the *NOTCH3* gene. PCR was made in 25 μ l reaction volume containing 100 ng genomic DNA, 10 pmol forward and reverse primers, 100 mM dNTPs, 1 U DNA polymerase (Red Hot DNA polymerase; ABgene, UK), 1.5 mM MgSO₄, 1 \times Reaction buffer, using a DNA thermal cycler (PTC-200; MJ Research, Waltham, MA). Following purification of PCR products, sequencing was performed using the automated sequencer ABI 3730 (Applied Biosystems, Foster City, CA).

3. Case report

A 79-year-old man came to our observation for an acute episode of dysarthria and weakness of the right arm and lower part of his face from which he recovered almost

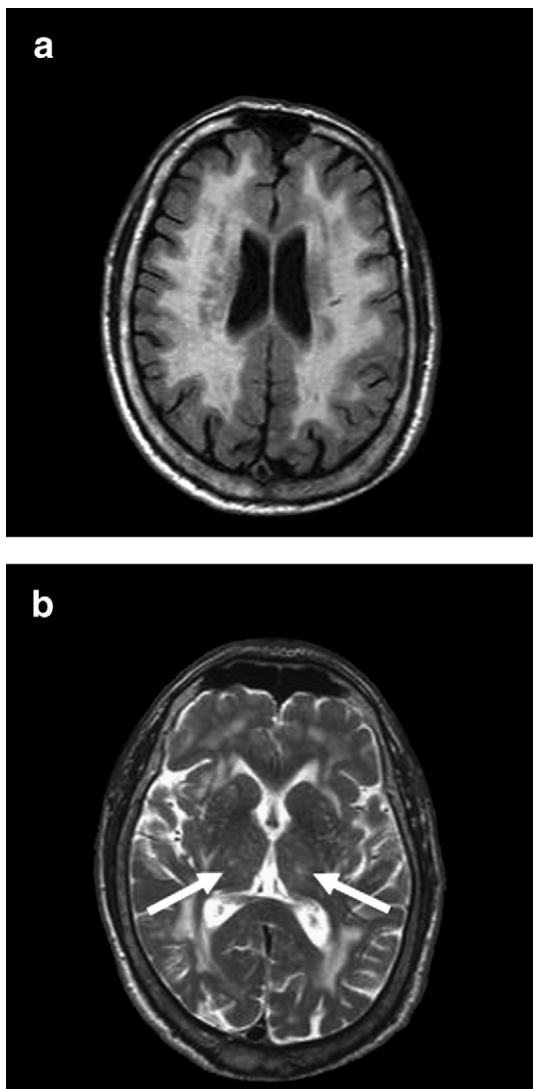


Fig. 1. Cerebral MRI. Diffuse, symmetric, and confluent hyperintense lesions in the periventricular and deep white matter on an axial FLAIR image (a), and bilateral thalamic lacunar infarcts on an axial T2-weighted image (b, arrows).

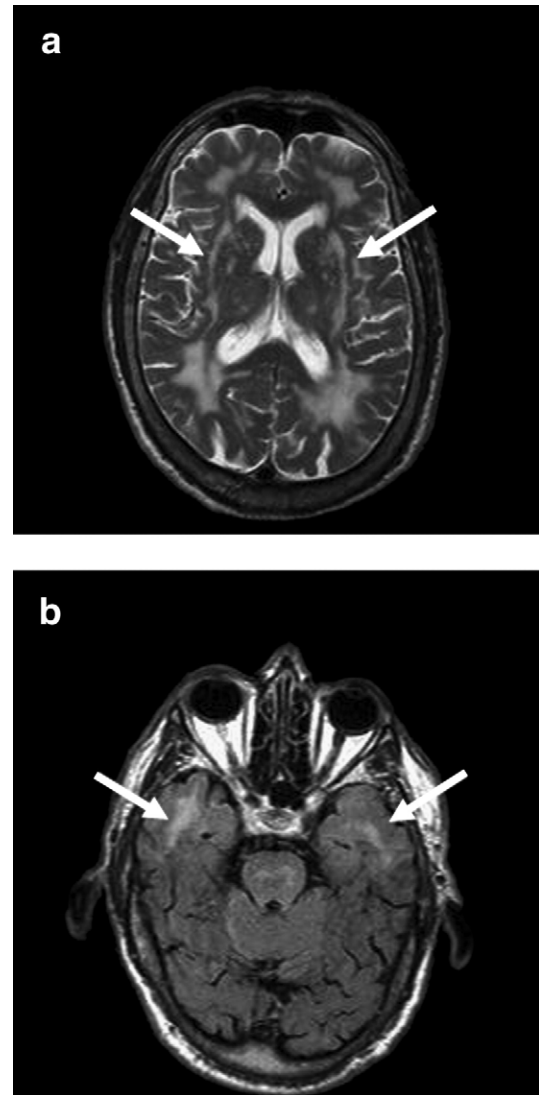


Fig. 2. Cerebral MRI. Extension of leukoencephalopathy to the external capsule bilaterally (arrows) on an axial T2-weighted image (a), and to the anterior temporal poles (arrows) on an axial FLAIR image (b).

completely in a few weeks. He had a 10-year history of hypertension and had been a cigarette smoker for as long as 62 years (20 packs year). Family history was negative for cerebro- and cardio-vascular diseases. Laboratory and instrumental evaluations were performed and revealed an increased carotid intima–media thickness on neurosonological evaluation, bradycardia on electrocardiogram, and mild hypertensive cardiac abnormalities on transthoracic echocardiogram. Cognitive deficits were not reported by the patient or his relatives and he was functionally independent in the activities of daily living. A neuropsychological evaluation showed only mild alterations in some cognitive domains such as attention and executive functions. Cerebral magnetic resonance imaging (MRI) showed a severe degree of white matter lesions that appeared confluent in the periventricular and deep areas and were associated with

multiple subcortical lacunar infarcts in the basal ganglia and thalami (Fig. 1). These alterations were initially deemed to represent expression of small vessel disease secondary to hypertension and aging. Treatment with anti-hypertensive agents was modified to improve blood pressure control, and aspirin was initiated. The patient was then followed-up with yearly clinical and functional assessment, and a cerebral MRI was repeated after 3 years. At the age of 82, he was still completely functionally autonomous (no item compromised in the instrumental activities of daily living scale [10]) and the neurological examination only showed mild signs of the previous stroke. No new cerebrovascular events had occurred and the cognitive and mood measurements remained stable during follow-up (Mini-Mental State Examination [11] score=27/30 both at baseline and 3-year follow-up, Geriatric Depression Scale [12] score=2/15 at baseline and 1/15 at 3-year follow-up). A better appreciation of the severity of white matter changes and of their extension to the external capsule and temporopolar regions (Fig. 2) when the second MRI was evaluated led to suspect CADASIL. Family history was then re-investigated under this light but only a history of migraine in one of the two sons emerged (Fig. 3). The diagnosis of CADASIL was confirmed when molecular genetic analysis revealed the heterozygous mutation c.3471C>G on exon 21 of the *NOTCH3* gene responsible for the replacement of a cysteine at position 1131 with a tryptophan (p.1131C>W) (Fig. 4). The mutation affects the EGF-like repeat 29 of the NOTCH3 receptor extracellular domain. The molecular analysis performed in the son with migraine according to the protocols for presymptomatic

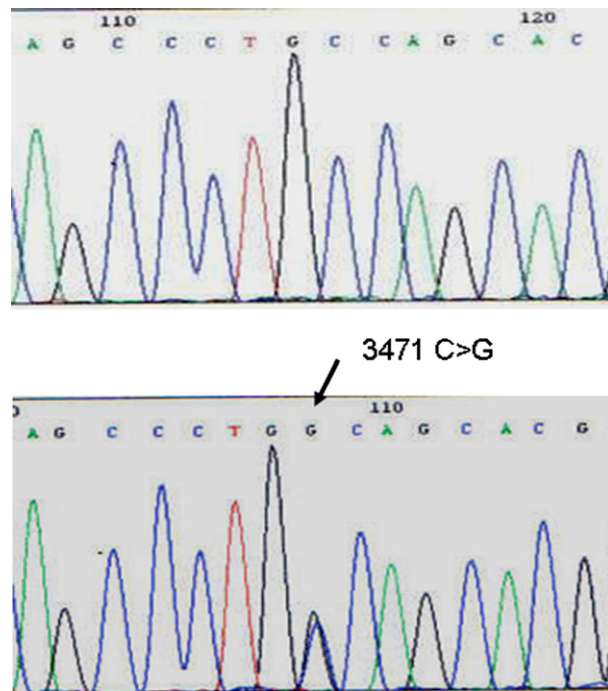


Fig. 4. Sequence chromatograms of exon 21 (*NOTCH3* gene) around nucleotide 3471 from a control individual (top) and the patient (bottom). The affected nucleotide is indicated by the arrow.

testing for Huntington disease ruled out the presence of the same mutation.

4. Discussion

We have described for the first time a pathogenic mutation responsible for CADASIL on exon 21 of the *NOTCH3* gene. The presence of a mutation leading to a cysteine substitution, that lies within an EGF-like repeat, follows the stereotyped nature of mutations typical of CADASIL, thus supporting the role of this novel mutation in causing the disease. A skin biopsy was not performed; however, it should be noted that the reported sensitivity of this exam in comparison with genetic testing is about 60% [13], with the consequence that a negative result would have not ruled out the presence of the disease.

Our report further expands the genetic spectrum of this disease and confirms the need of analysing all the exons from 2 to 24 when CADASIL is suspected, particularly in patients from countries where mutations have been found to be not restricted to a few exons [14,15]. Since the first studies that reported clustering of mutations in CADASIL [8], genetic alterations have been described on many of the 23 exons coding for the EGF-like repeats of NOTCH3 extracellular domain [9]. However, some of these exons are involved less frequently than others and up to now 6 had never been reported as interested by mutations. In addition to a true unbalanced distribution of mutations across the exons, this could partly depend on a biased laboratory approach in the past. In fact,

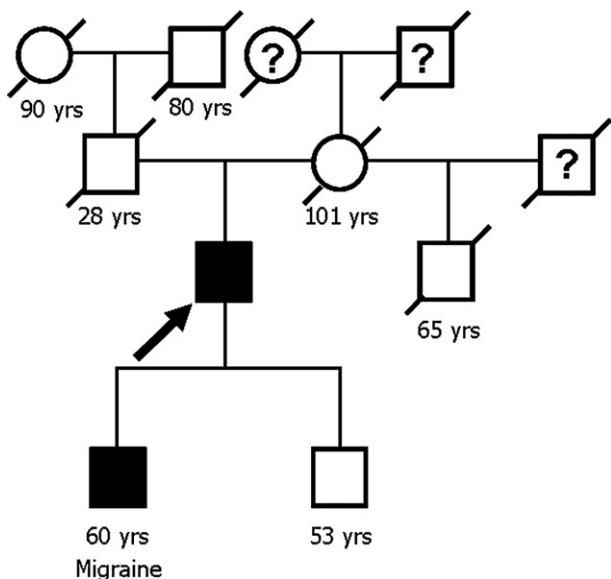


Fig. 3. Family pedigree. Our 82-year-old patient is indicated by the arrow. Symptomatic subjects for CADASIL typical disturbances are represented in black filled symbols. When known, age at death or current age (for living subjects) are reported. It is worthy to note the young age of death of patient's father, probably for nephritis.

being the molecular analysis of the *NOTCH3* gene expensive and time consuming, several laboratories had restricted the sequencing to the exons reported to have a higher probability of carrying the mutation. As a consequence, the disease might have gone undiagnosed in some patients and the hypothesis of an unbalanced distribution of mutations across the 23 exons could have been erroneously reinforced.

Our patient was initially considered to be affected by sporadic cerebral small vessel disease because of his advanced age, presence of vascular risk factors and absence of relevant family history. Only a re-evaluation of MRI findings led to hypothesise a diagnosis of CADASIL. The mild clinical picture that this octogenarian CADASIL patient presented, in fact, is not the one expected in a disease in which symptoms onset is generally in the mid-adult age and the course is progressively disabling. Few data can be found in the literature about such mildly affected elderly CADASIL patients [16,17]. In large European CADASIL series only few geriatric patients were included [3–6]. The oldest CADASIL patient (94 years) was reported in Finland, but no further clinical information was provided [18]. In a German study on the long-term prognosis of the disease, about 90% of male patients older than 70 years were bedridden [6]. The presence of paucisymptomatic CADASIL patients and the possible association between mild clinical pictures and some mutations could be another possible cause for the reported unbalanced pattern of mutations distribution because of a lack of disease suspicion in these cases. Although a genotype–phenotype correlation has not been proven in CADASIL and only few data support its existence [6,19], one might speculate that the novel mutation found in our patient has a very mild effect on the expressivity of the disease. The lack of typical CADASIL symptoms among the patient ancestors would support this hypothesis. Alternatively, a *de novo* mutation could have occurred in our patient or in his father, who died at young age because of a renal disease. Finally, in the hypothetic presence of a mutation with mild effect on the phenotype, hypertension and cigarette smoking could have contributed to the symptoms onset in our patient. In fact, since clinical features in CADASIL are highly variable, the role of possible additional modulating factors has been recently studied and smoking has been found related to earlier stroke occurrence [5].

5. Conclusions

The reported case contributes to expand the genotypic spectrum of CADASIL and underlines that the diagnosis of the disease can be missed if not all the *NOTCH3* exons 2–24 are analysed. Moreover, it confirms the heterogeneity of the clinical picture in CADASIL, and supports that paucisymptomatic patients can be encountered even in a geriatric age.

Whether this reported novel mutation is associated with a mild clinical picture remains a subject for future investigation.

References

- [1] Chabriat H, Levy C, Taillia H, Iba-Zizen MT, Vahedi K, Joutel A, et al. Patterns of MRI lesions in CADASIL. *Neurology* 1998;51:452–7.
- [2] Singhal S, Rich P, Markus HS. The spatial distribution of MR imaging abnormalities in cerebral autosomal dominant arteriopathy with subcortical infarcts and leukoencephalopathy and their relationship to age and clinical features. *Am J Neuroradiol AJNR* 2005;26:2481–7.
- [3] Chabriat H, Vahedi K, Iba-Zizen MT, Joutel A, Nibbio A, Nagy TG, et al. Clinical spectrum of CADASIL: a study of 7 families. *Cerebral autosomal dominant arteriopathy with subcortical infarcts and leukoencephalopathy*. *Lancet* 1995;346:934–9.
- [4] Dichgans M, Mayer M, Utner I, Bruning R, Muller-Hocker J, Rungger G, et al. The phenotypic spectrum of CADASIL: clinical findings in 102 cases. *Ann Neurol* 1998;44:731–9.
- [5] Singhal S, Bevan S, Barrick T, Rich P, Markus HS. The influence of genetic and cardiovascular risk factors on the CADASIL phenotype. *Brain* 2004;127:2031–8.
- [6] Opherk C, Peters N, Herzog J, Luedtke R, Dichgans M. Long-term prognosis and causes of death in CADASIL: a retrospective study in 411 patients. *Brain* 2004;127:2533–9.
- [7] Joutel A, Corpechot C, Ducros A, Vahedi K, Chabriat H, Mouton P, et al. Notch3 mutations in CADASIL, a hereditary adult-onset condition causing stroke and dementia. *Nature* 1996;383:707–10.
- [8] Joutel A, Vahedi K, Corpechot C, Troesch A, Chabriat H, Vayssiere C, et al. Strong clustering and stereotyped nature of Notch3 mutations in CADASIL patients. *Lancet* 1997;350:1511–5.
- [9] Federico A, Bianchi S, Dotti MT. The spectrum of mutations for CADASIL diagnosis. *Neurol Sci* 2005;26:117–24.
- [10] Lawton MP, Brody EM. Assessment of older people: self-maintaining and instrumental activities of daily living. *Gerontologist* 1969;9:179–86.
- [11] Folstein MF, Folstein SE, McHugh PR. “Mini-mental state”. A practical method for grading the cognitive state of patients for the clinician. *J Psychiatr Res* 1975;12:189–98.
- [12] Yesavage JA. Geriatric Depression Scale. *Psychopharmacol Bull* 1988;24:709–11.
- [13] Malandrini A, Gaudiano C, Gambelli S, Berti G, Serni G, Bianchi S, et al. Diagnostic value of ultrastructural skin biopsy studies in CADASIL. *Neurology* 2007;68:1430–2.
- [14] Dotti MT, Federico A, Mazzei R, Bianchi S, Scali O, Conforti FL, et al. The spectrum of Notch3 mutations in 28 Italian CADASIL families. *J Neurol Neurosurg Psychiatry* 2005;76:736–8.
- [15] Viana-Baptista M, Ferriera S, Costa P, Venancio M, Fernandes S, Carvalho F, et al. The spectrum of NOTCH3 mutations in Portuguese patients with CADASIL: implications for diagnostic strategies. *Cerebrovasc Dis* 2007;23(Suppl 2):75.
- [16] Mourad A, Levasseur M, Bousser MG, Chabriat H. CADASIL with minimal symptoms after 60 years. *Rev Neurol (Paris)* 2006;162:827–31.
- [17] Pescini F, Sarti C, Bianchi S, Bartolini L, Dotti MT, Federico A, et al. Mild clinical picture in 5 old CADASIL patients. *Cerebrovasc Dis* 2007;23(Suppl 2):75.
- [18] Kalimo H, Ruchoux MM, Viitanen M, Kalaria RN. CADASIL: a common form of hereditary arteriopathy causing brain infarcts and dementia. *Brain Pathol* 2002;12:371–84.
- [19] Lesnik Oberstein SA, van den Boom R, van Buchem MA, van Houwelingen HC, Bakker E, Vollebregt E, et al. Dutch CADASIL Research Group. Cerebral microbleeds in CADASIL. *Neurology* 2001;57:1066–70.