

Tuberculous meningoencephalitis in a pregnant woman presenting 7 years after removal of a cerebral granuloma

C. Liu · L. J. Christie · J. Neely · M. Gandhi ·
R. A. Jacobs · A. Bollen · C. A. Glaser

Received: 15 August 2007 / Accepted: 30 October 2007 / Published online: 22 November 2007
© Springer-Verlag 2007

Abstract We describe the unusual case of a young woman with a history of seizures and a granulomatous, likely tuberculous brain lesion that was surgically removed. She had an uneventful recovery without any additional therapy other than anti-epileptics. Seven years later, she presented during pregnancy with culture-confirmed tuberculous meningoencephalitis. This case highlights the spectrum of tuberculous central nervous system disease and the challenges in diagnosis.

Introduction

Central nervous system (CNS) involvement is one of the most serious complications of *Mycobacterium tuberculosis* disease. Clinical presentations may include meningitis or meningo-

encephalitis, epidural or subdural abscess, and intracerebral tuberculoma. Even with antituberculosis chemotherapy, CNS disease is associated with high morbidity and mortality [1]. We present the unusual case of a young woman with a probable CNS tuberculoma that was successfully treated with surgical therapy alone but reactivated years later during pregnancy as a meningoencephalitis.

Case report

A 29-year-old woman, 14 weeks pregnant, presented to her local emergency department (ED) in 2005 with fever, headache, and drowsiness.

The patient was healthy until the age of 22 in 1998 when she had a single complex seizure and was found to have a 2.5 cm × 4 cm right frontal lobe mass (Fig. 1a). Surgical resection and pathologic analysis of the lesion revealed granulomatous inflammation with surrounding lymphocytic and plasma cell infiltrate (Fig. 2). Stains for fungus and acid-fast bacillus (AFB) were negative and the patient was given a presumptive diagnosis of neurosarcoidosis. Unfortunately, the specimen was not submitted for bacterial, fungal, or AFB culture. She had an uneventful recovery with no seizures during 6 months of phenytoin treatment and no additional therapies. Six months prior to the current presentation, she briefly reinitiated antiepileptic therapy due to concern for a possible seizure consisting of olfactory hallucinations and brief bilateral hand jerking. Of note, this episode coincided with an earlier pregnancy that the patient electively terminated.

During the current presentation, the patient developed malaise and back pain, followed by subjective fever, headache, nausea, and vomiting. She presented to her local ED on two separate occasions over 2 weeks. She was

C. Liu (✉) · M. Gandhi · R. A. Jacobs
Division of Infectious Diseases, San Francisco General Hospital,
University of California,
1001 Potrero Avenue, Bldg 30, 4th floor,
San Francisco, CA 94110, USA
e-mail: catherine.liu@ucsf.edu

J. Neely
Department of Neurology, University of California,
San Francisco, CA, USA

A. Bollen
Department of Pathology and Laboratory Medicine,
University of California,
San Francisco, CA, USA

L. J. Christie · C. A. Glaser
Viral and Rickettsial Disease Laboratory,
California Department of Public Health,
Richmond, CA, USA

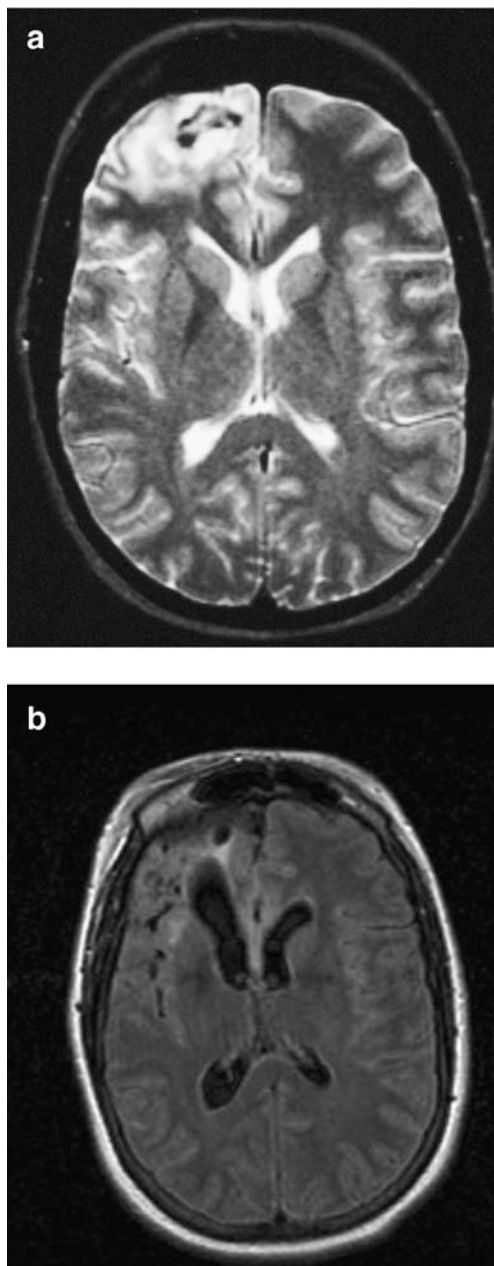


Fig. 1 **a** Brain magnetic resonance imaging (MRI) (1998) revealing a 2.5 cm×4 cm right frontal lobe mass. **b** Brain MRI (2005) showing right frontal lobe encephalomalacia and diffuse meningeal T2 prolongation

thought to have migraine headache and was treated with morphine. On day 16, she returned to the ED with fever, persistent headache and nausea, and new drowsiness.

The patient also had a history of a positive tuberculin skin test (TST), but the date of this test was unknown and it was unknown if the patient ever received treatment for latent tuberculosis (TB). The patient is of Mexican-American heritage, and was born in the United States. She lived in Mexico from age 6 months to 4 years and during her 17th year, spending the intervening time in the

United States. She does not drink alcohol or use illicit drugs. She has no pets. Her family history was notable for multiple family members with TB in the distant past but she had no known recent TB contacts or international travel.

Upon presentation to her local ED, she had a temperature of 39°C. Her other vital signs were normal. She was slightly drowsy but fully oriented. Her physical exam was otherwise normal. Laboratory studies were notable for hyponatremia and hypokalemia. Cerebrospinal fluid (CSF) obtained by lumbar puncture revealed white blood cells (WBCs) 286 cells/mm³ (75% lymphocytes), red blood cells (RBCs) 80 cells/mm³, protein 237 mg/dL and glucose 8 mg/dL. CSF gram stain, routine bacterial culture, cryptococcal antigen, and polymerase chain reaction (PCR) testing for TB were negative. Cranial computed tomography scan (CT) revealed the prior right frontal craniotomy with interval development of right frontal

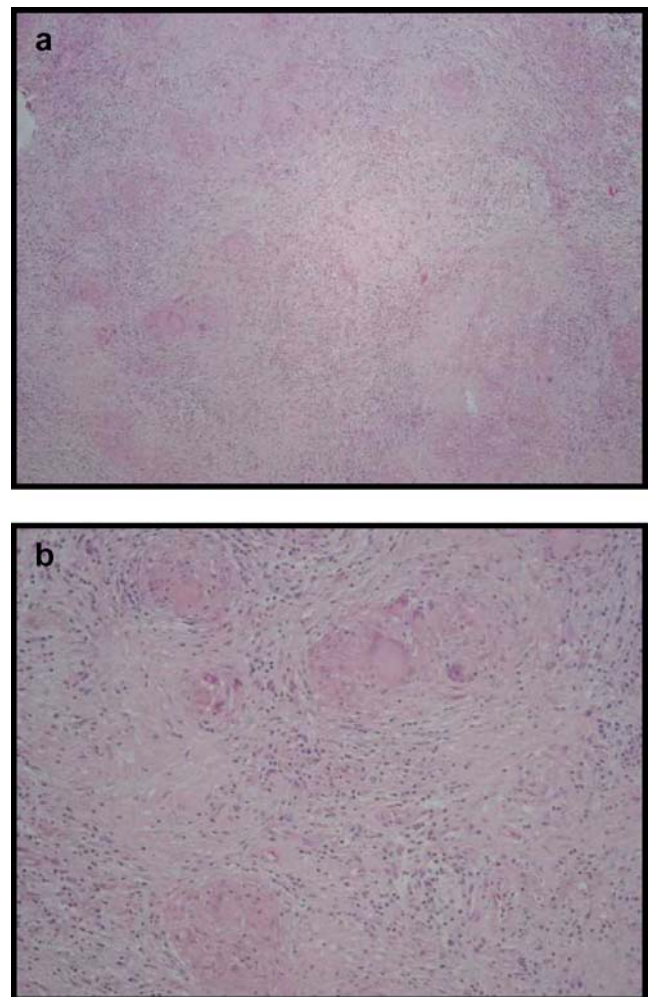


Fig. 2a, b Brain tissue from right frontal biopsy (1998), stained with hematoxylin and eosin. **a** Granulomatous inflammation with surrounding lymphocytic and plasma cell infiltrate and several areas of necrosis. **b** Giant cells within the granuloma

encephalomalacia. Chest radiography and CT were normal. She was started on empiric therapy for bacterial meningitis with ceftriaxone and ampicillin. Rifampin, isoniazid, pyrazinamide, ethambutol (RIPE), and dexamethasone were also started due to concern for possible tuberculous meningitis. Because of worsening drowsiness, disorientation, and new diplopia, she was transferred to a tertiary care medical center on day 24 of illness.

Upon transfer, the patient's temperature was 36.2°C, blood pressure 156/93, pulse 93 beats per minute, and respirations 18 breaths per minute. Her general medical exam was notable for meningismus and a gravid uterus. On neurologic exam, she was drowsy and oriented to person, month, and year but not day nor place. Language was normal. She had bilateral abducens nerve paresis. Other cranial nerves, motor, and sensory exam were normal. She had no dysmetria. Her gait was mildly unsteady.

Laboratory studies included peripheral WBC count 7,200 cells/mm³, hematocrit 33.5% and platelets 225,000/mm³. Her electrolytes and liver function tests were normal except for a sodium of 122 mEq/L. Repeat CSF analysis revealed WBC 850 cells/mm³ (56% neutrophils, 36% lymphocytes), RBCs 22 cells/mm³, protein 196 mg/dL, and glucose 18 mg/dL. CSF gram stain and bacterial culture were negative. She was continued on RIPE and dexamethasone. Other antimicrobials were discontinued.

Brain magnetic resonance imaging (MRI) revealed right frontal lobe encephalomalacia and diffuse meningeal T2 signal prolongation consistent with meningitis (Fig. 1b). Repeat chest radiography was normal, and a TST was negative. Numerous studies to identify a causative infectious agent were negative. These included CSF herpes simplex virus and varicella zoster virus PCR, CSF and serum cryptococcal antigen, serum antibody tests for human immunodeficiency virus, West Nile virus, human T-cell lymphotropic virus I and II, and coccidioides. Serum rapid plasmid reagin, cytomegalovirus antigenemia assay, and urinary histoplasmosis antigen tests were negative. AFB stains of three induced sputums and CSF were negative. Serum angiotensin converting enzyme was normal. Histopathology slides from the 1998 surgical resection reviewed in detail by the tertiary care medical center's neuropathologists showed areas of confluent granulomas with some areas of necrosis that were not previously appreciated. The California Encephalitis Project (CEP) facilitated acquisition and testing of the original formalin-fixed paraffin block for mycobacterium immunohistochemical staining and PCR by the Centers for Disease Control and Prevention and for mycobacterium PCR by the John L. McLellan Memorial Hospital in Little Rock, AK. Additionally, the CEP coordinated testing of the patient's CSF for TB by PCR at the Contra Costa Public Health Laboratory. All testing was negative. The patient's fever,

drowsiness, and hyponatremia gradually resolved on empiric therapy for tuberculous meningitis. Incidentally, she also underwent elective termination of her pregnancy. She was discharged to home in good condition with only mild residual right abducens nerve paresis.

Soon thereafter, the patient's CSF AFB culture grew out pan-sensitive *Mycobacterium tuberculosis*. She completed 1 year of anti-TB therapy and made a full recovery with no complications.

Discussion

Meningitis is one of the most serious forms of *Mycobacterium tuberculosis* disease, with mortality rates exceeding 50% [1]. Disease within the brain can develop from hematogenous spread at the time of the initial infection or from reactivation of previously sequestered intracranial disease. If CNS disease does not occur during hematogenous dissemination, the immune system may sequester the TB organisms in the form of Rich foci, which can later coalesce into granulomatous tuberculomas or rupture into the subarachnoid space months to years later, causing meningitis or meningoencephalitis [2, 3]. Pathologically, tuberculomas may appear as caseating (or occasionally non-caseating) granulomas on brain biopsies, although AFB staining is often negative [4]. The differential diagnosis for granulomatous CNS lesions include bacteria such as *Brucella* spp., *Tropheryma whippelii*, *Mycobacterium* spp., fungal pathogens such as *Coccidioides immitis*, *Histoplasma capsulatum*, *Blastomyces dermatitidis*, *Cryptococcus* spp., *Candida* spp., *Aspergillus* spp., *Mucor* spp., and *Cladosporium* spp., amoeba such as *Balamuthia mandrillaris*, as well as non-infectious etiologies such as sarcoidosis, Wegener's granulomatosis or other inflammatory conditions [5–8].

The diagnosis of CNS TB in the absence of pulmonary or other systemic disease remains challenging. AFB staining and culture, as well as TB PCR of the CSF are insensitive [3, 9]. AFB culture requires large quantities of CSF and growth can take up to 6–8 weeks. Although the yield of AFB culture may be low, it should be performed when possible as a positive result is diagnostic and would have altered the initial management of the case patient and potentially her course. While awaiting AFB stain and culture data, supportive evidence should be sought, including positive tuberculin skin testing, characteristic CSF and chest radiograph findings, and a history of contact with a case of TB or travel to an endemic location.

During this patient's initial presentation in 1998, she did not have any systemic symptoms suggestive of TB. The initial finding of non-necrotizing granulomas paired with negative AFB staining of the brain biopsy sample led to the

exclusion of TB and presumptive diagnosis of neurosarcoidosis. However, despite not receiving medical therapy for sarcoidosis, the patient remained asymptomatic for the succeeding 7 years. It is also unusual for sarcoidosis to manifest in the CNS without any evidence of systemic disease [10]. The absence of new intraparenchymal or pulmonary lesions at the time of her second admission also makes neurosarcoidosis unlikely [11].

The most likely explanation for her clinical presentation is that her prior brain lesion represented a tuberculoma that was surgically cured. Successful treatment of tuberculoma with surgical resection alone has been reported prior to the introduction of streptomycin, para-aminosalicylic acid, and isoniazid [12]. There may have been sufficient residual bacilli that remained latent to reactivate during pregnancy, particularly in the absence of concomitant anti-TB therapy at the time of surgical resection. Her initial presentation is consistent with previous reports of CNS tuberculomas; they are usually not accompanied by coexistent meningeal involvement and the frontal lobe is a commonly involved region. Furthermore, in the majority of cases, the AFB stain is negative [10, 13]. Of interest, some authors have postulated a link between *Mycobacterium* infection, immune dysregulation and the development of sarcoidosis. In some cases, mycobacterial DNA has been isolated from sarcoidosis specimens [14, 15].

Although pregnancy has not been associated with an increased risk of developing active TB [16], there have been reports of tuberculous meningitis [17] and disseminated TB with multiple cerebral tuberculomas in pregnant women [18, 19]. Early diagnosis or empiric therapy in suspected cases is critical to good outcomes [20]. The state of relative immunosuppression may have contributed to this patient having had flares of disease that were temporally related to her pregnancies. A seizure-like event with olfactory hallucinations and brief bilateral hand jerking occurred during an earlier pregnancy. Her current presentation of meningoencephalitis also coincided with pregnancy.

This case is an intriguing presentation of an unusual sequence of diseases and highlights the importance of employing a multidisciplinary approach in recognizing the myriad manifestations of TB: an initially undefined granulomatous brain lesion, likely tuberculous, was treated with surgical resection and was followed 7 years later by the development of tuberculous meningoencephalitis during pregnancy.

Acknowledgments We thank the laboratory staff in the Viral and Rickettsial Disease Laboratory and Contra Costa Public Health Laboratory and John L. McLellan Memorial Hospital. This study was supported by the Centers for Disease Control and Prevention Emerging Infections Program (U50/CCU915546-09).

References

- Girgis NI, Sultan Y, Farid Z, Mansour MM, Erian MW, Hanna LS, Mateczun AJ (1998) Tuberculosis Meningitis, Abbassia Fever Hospital - Naval Medical Research Unit No. 3 - Cairo, Egypt, from 1976–1996. *Am J Trop Med Hyg* 58(1):28–34
- Dunlap NE, Bass J, Fujiwara P, Hopewell P, Horsburgh CR, Salfinger M, Simone PM (2000) Diagnostic standards and classification of tuberculosis in adults and children. *Am J Respir Crit Care Med* 161(4):1376–1395
- Thwaites G, Chau TTH, Mai NTH, Drobniowski F, McAdam K, Farrar J (2000) Tuberculous meningitis. *J Neurol Neurosurg Psychiatry* 68:289–299
- Pagnoux C, Genereau T, Lafitte F, Congy F, Chiras J, Herson S (2000) Brain tuberculomas. *Ann Med Intern* 151(6):448–455
- Strickland-Marmol LB, Fessler RG, Rojiani AM (2000) Necrotizing sarcoid granulomatosis mimicking an intracranial neoplasm: clinicopathologic features and review of the literature. *Mod Pathol* 13(8):909–913
- Thomas G, Murphy S, Staunton H, O'Neill S, Farrell MA, Brett FM (1998) Pathogen-free granulomatous diseases of the central nervous system. *Human Pathol* 29(2):110–115
- Silbert SW, Parker E, Horenstein S (1976) Whipple's disease of the central nervous system. *Acta Neuropathol* 36(1):31–38
- Finsterer J, Kladosek A, Nagelmeier I-E, Becherer A, Matula C, Stradal K-H, Wolf K, Czech T, Stanek G (2000) Chronic granulomatous meningitis With multiple cranial nerve lesions, hydrocephalus, stroke, sinus thrombosis, and epilepsy. *South Med J* 93(11):1108–1111
- Pai M, Flores LL, Pai N, Hubbard A, Riley LW, Colford JM Jr (2003) Diagnostic accuracy of nucleic acid amplification tests for tuberculous meningitis: a systematic review and meta-analysis. *Lancet Infect Dis* 3:633–643
- Bayindir C, Mete O, Bilgic B (2006) Retrospective study of 23 pathologically proven cases of central nervous system tuberculomas. *Clin Neurol Neurosurg* 108(4):353–357
- Jackson RJ, Goodman JC, Huston DP, Harper RL (1998) Parafalcine and bilateral convexity neurosarcoidosis mimicking meningioma: case report and review of the literature. *Neurosurg Clin N Am* 42(3):635–638
- Dastur HM (1983) Diagnosis and neurosurgical treatment of tuberculous disease of the CNS. *Neurosurg Rev* 6(3):111–117
- Giese A, Kucinski T, Hagel C, Lohmann F (2003) Intracranial tuberculomas mimicking a malignant disease in an immunocompetent patient. *Acta Neurochir* 145(6):513–517
- Wong CF, Yew WW, Wong PC, Lee J (1998) A case of concomitant tuberculosis and sarcoidosis with mycobacterial DNA present in the sarcoid lesion. *Chest* 114(2):626–629
- Drake WP, Pei Z, Pride DT, Collins RD, Cover TL, Blaser MJ (2002) Molecular analysis of sarcoidosis tissues for mycobacterium species DNA. *Emerg Infect Dis* 8(11):1334–1341
- Espinal MA, Reingold AL, Lavandera M (1996) Effect of pregnancy on the risk of developing active tuberculosis. *J Infect Dis* 173(2):488–491
- Jana N, Vasishtha K, Saha SC, Ghosh K (1999) Obstetrical outcomes among women with extrapulmonary tuberculosis. *N Engl J Med* 341(9):645–649
- Capon A, Noterman J, Hubert JP, Klasterky J, Flament-Durand J (1975) Multiple tuberculomas of the brain. Report of a case. *Acta Neurochir* 32(3–4):303–312
- Gaspardo EL, Tazoniero P, de Carvalho Neto A (2003) Disseminated tuberculosis in a pregnant woman presenting with numerous brain tuberculomas: case report. *Arq Neuro-Psiquiatria* 61(3B):855–858
- Kingdom JC, Kennedy DH (1989) Tuberculous meningitis in pregnancy. *Br J Obstet Gynaecol* 96(2):233–235