

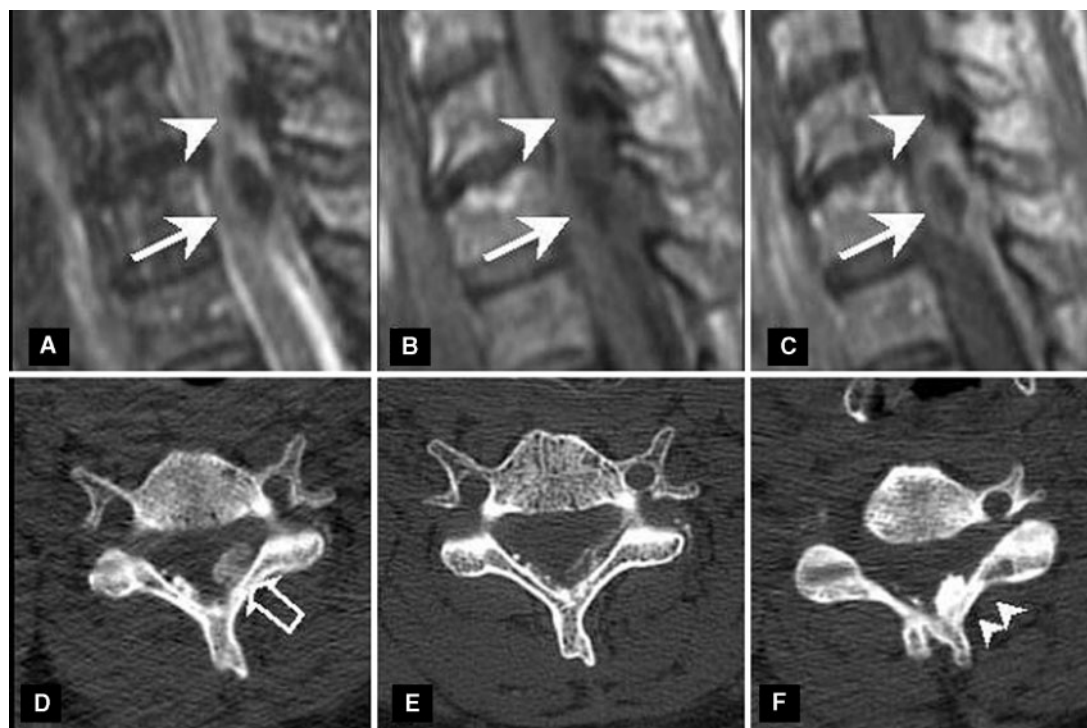FIG. 1. Imaging of the cervical spine. MRI (A, B, C) made during the acute clinical stage (day 3). Sagittal T2-weighted image (A) and T1-weighted image before (B) and after (C) administration of gadolinium. It shows two calcifications inside the ligamentum flavum. The C7 calcification (arrow) in state of resorption has an inflammatory rim that is hyper-intense on T2-weighted imaging and hypo-intense on T1-weighted images and that shows contrast enhancement. The C6 ligamentum flavum calcification (arrow head) has no inflammatory aspect on MRI. A 3D CT scan in axial view (D, E, F). During the acute clinical stage (day 3) it shows a cloud-like calcification inside the ligamentum flavum at C7 (D: empty arrow), less dense than a second calcification inside the C6 ligamentum flavum (F: double arrow head). Control CT scan at day 10: near complete disappearance of the calcification at C7 (E). There was no change of the C6 calcification.

cervico-brachial neuralgia. CT and MRI are important to confirm the diagnosis and to show associated inflammatory phenomena. We hypothesize that the calcification resorption was either caused directly by inflammation, or by a non-inflammatory process with concomitant release of calcium crystals that lead to an acute inflammatory response. Furthermore, our case illustrates that resorption of ligamentum flavum calcification can be associated with disappearance of symptoms. Before surgical treatment is considered, in absence of neurological deficits, a medical symptomatic treatment could be proposed first during spontaneous resorption of calcific deposits.

#### Rheumatology key message

- Ligamentum flavum calcifications should be considered in the differential diagnosis of acute cervico-brachial neuralgia.

*Disclosure statement:* The authors have declared no conflicts of interest.

G. SALIOU<sup>1</sup>, M. THÉAUDIN<sup>2</sup>, F. GRADOS<sup>3</sup>, G. CLAVEL<sup>3</sup>,  
P. LEHMANN<sup>1</sup>, D. R. RUTGERS<sup>1</sup>, J. N. VALLÉE<sup>1</sup>

<sup>1</sup>Service de Neuroradiologie diagnostic et interventionnelle, Centre Hospitalier et Universitaire d'Amiens, Amiens, <sup>2</sup>Service de Neurologie, Centre Hospitalier et Universitaire du Kremlin Bicêtre, Le Kremlin Bicêtre and <sup>3</sup>Service de Rhumatologie, Centre Hospitalier et Universitaire d'Amiens, Amiens, France  
Accepted 25 July 2007

Correspondence to: G. Saliou, Service de Neuroradiologie diagnostic et interventionnelle, Centre Hospitalier et Universitaire d'Amiens, 2 Place Victor Pauchet, 80054 Amiens cedex 1, France. E-mail: guisaliou@yahoo.com

- 1 Cabre P, Pascal-Moussellard H, Kaidomar S *et al*. Six cases of cervical ligamentum flavum calcification in Blacks in the French West Indies. *Joint Bone Spine* 2001;68:158–65.
- 2 Kamakura K, Nanko S, Furukawa T, Mannen T, Toyokura Y. Cervical radiculomyelopathy due to calcified ligamenta flava. *Ann Neurol* 1979;5:193–5.
- 3 Kawano N, Matsuno T, Miyazawa S *et al*. Calcium pyrophosphate dihydrate crystal deposition disease in the cervical ligamentum flavum. *J Neurosurg* 1988;68:613–20.
- 4 Khan MH, Smith PN, Donaldson WF 3rd. Acute quadriplegia caused by calcification of the entire cervical ligamentum flavum in a white female—report of an unusual case and a brief review of the literature: case report. *Spine* 2005;30:E687–91.
- 5 Muthukumar N, Karuppaswamy U. Tumoral calcium pyrophosphate dihydrate deposition disease of the ligamentum flavum. *Neurosurgery* 2003;53:103–8discussion 108–9.
- 6 Ellman MH, Vazquez T, Ferguson L, Mandel N. Calcium pyrophosphate deposition in ligamentum flavum. *Arthritis Rheum* 1978;21:611–3.
- 7 Imai S, Hukuda S. Cervical radiculomyelopathy due to deposition of calcium pyrophosphate dihydrate crystals in the ligamentum flavum: historical and histological evaluation of attendant inflammation. *J Spinal Disord* 1994;7:513–7.
- 8 Mula M, Bordin G, Naldi P *et al*. Crowned dens syndrome in an elderly man. *Neurology* 2001;56:275.
- 9 Canhao H, Fonseca JE, Leandro MJ *et al*. Cross-sectional study of 50 patients with calcium pyrophosphate dihydrate crystal arthropathy. *Clin Rheumatol* 2001;20:119–22.
- 10 Doherty M, Dieppe P. Clinical aspects of calcium pyrophosphate dihydrate crystal deposition. *Rheum Dis Clin North Am* 1988;14:395–414.

*Rheumatology* 2008;47:107–109  
doi:10.1093/rheumatology/kem264  
Advance Access publication 22 November 2007

#### Aggressive CNS lupus vasculitis in the absence of systemic disease activity

SIR, A 35-yr-old woman was diagnosed with systemic lupus erythematosus (SLE) at age 25 when she presented with fever, arthralgia, alopecia, photosensitive rash and oral ulceration associated with high-titre anti-nuclear antibodies (ANA) (1:320).

Double-stranded DNA (dsDNA) antibodies were 20 IU/ml [normal range (NR) <50] and IgG anti-cardiolipin antibodies became elevated (35 U/ml, NR <5 U/ml). Two months later, while there continued to be active systemic disease activity [1] and strongly positive ANA, she developed mononeuritis multiplex and had four generalized tonic-clonic seizures and was treated with carbamazepine (800 mg/day). She was treated with prednisolone (25 mg/day) and hydroxychloroquine (400 mg/day) and over the next decade her SLE remained quiescent, except for the development of hypertension, a transient bullous rash and osteopenia. Immunosuppression and carbamazepine were discontinued at the age of 30 yrs.

She was admitted to the hospital with a 2-month history of fever, nausea, abdominal pain and diarrhoea. There was a fever (37.8°C) and diffuse abdominal tenderness with no masses or organomegaly. She was normotensive with a normal cardiovascular and respiratory examination. There was no alopecia, lymphadenopathy, rash, arthritis or synovitis. Anti-dsDNA antibodies (DNA ELISA 45, NR 0–50 IU/ml), antiphospholipid (APL) antibodies (IgG 1.9, IgM 2.3, NR 0–5 U), complement C3 (1.6, NR 0.9–1.80 g/l) and C4 (0.20, NR 0.10–0.40 g/l) were all normal. ANA were positive at low titre (1:10) and anti-Ro antibodies undetectable. Chest X-ray, echocardiogram and blood cultures were unremarkable. An abdominal ultrasound suggested cholecystitis and i.v. cefuroxime was commenced. She then had a secondary generalized tonic-clonic seizure. Post-ictally, there was a mild left hemiparesis with brisk left upper limb reflexes.

An MRI brain (Fig. 1A) showed abnormalities highly suggestive of herpes simplex virus (HSV) encephalitis. Immunological markers for active SLE, including ANA, dsDNA, anti-Ro and APL antibodies, remained within normal limits. The serum C-reactive protein was elevated (121.8 mg/l) as was the erythrocyte sedimentation rate (ESR) (>120 mm/h), consistent with the diagnosis of cholecystitis. There was a normochromic, normocytic anaemia (Hb 9.1 g/l), normal platelet count and APTT. Cerebrospinal fluid (CSF) was sterile with a slightly elevated protein (0.71 g/l), normal glucose (CSF 3.3 mmol/l, serum 6.0 mmol/l) and 2 lymphocytes/ml present. HSV PCR was negative and oligoclonal bands were absent.

The clinical course deteriorated over the next 2 days with persistent fever, a worsening left hemiparesis and coma, despite treatment with i.v. aciclovir. An EEG confirmed generalized non-specific encephalopathic slowing and excluded continuous non-convulsive seizure activity. Repeat MRI brain (Fig. 1B) showed marked progression. The complete absence of systemic SLE autoimmune activity (i.e. negative ANA, dsDNA antibodies and normal complement levels) was striking and the cause of the problem remained obscure. Due to the rapid deterioration and lack of a response to aciclovir, a right temporal lobe brain biopsy was performed. This was consistent with active small vessel lymphocytic vasculitis (Fig. 1E–G). She was treated with i.v. methylprednisolone (1 g daily for 3 days) and monthly i.v. cyclophosphamide (750 mg) for 6 months. There was marked improvement in clinical condition and MRI appearances (Fig. 1C and D). She relapsed 6 months later without elevation of ESR, ANA or antineutrophil cytoplasmic antibody (ANCA), requiring a further course of cyclophosphamide, again with a good recovery, and is currently maintained on azathioprine (2 mg/kg) and phenytoin (200 mg/day).

## Discussion

The American College of Rheumatology recognizes 19 SLE neuropsychiatric syndromes [2] including psychosis, stroke, seizures and subtle abnormalities of cognitive function. Independent predictors of neuropsychiatric damage include systemic disease activity, Caucasian ethnicity and the presence of APL and anti-Ro antibodies [3]. Vasculitis is a rare manifestation, occurring in less than 7% of neuropsychiatric lupus [4, 5].

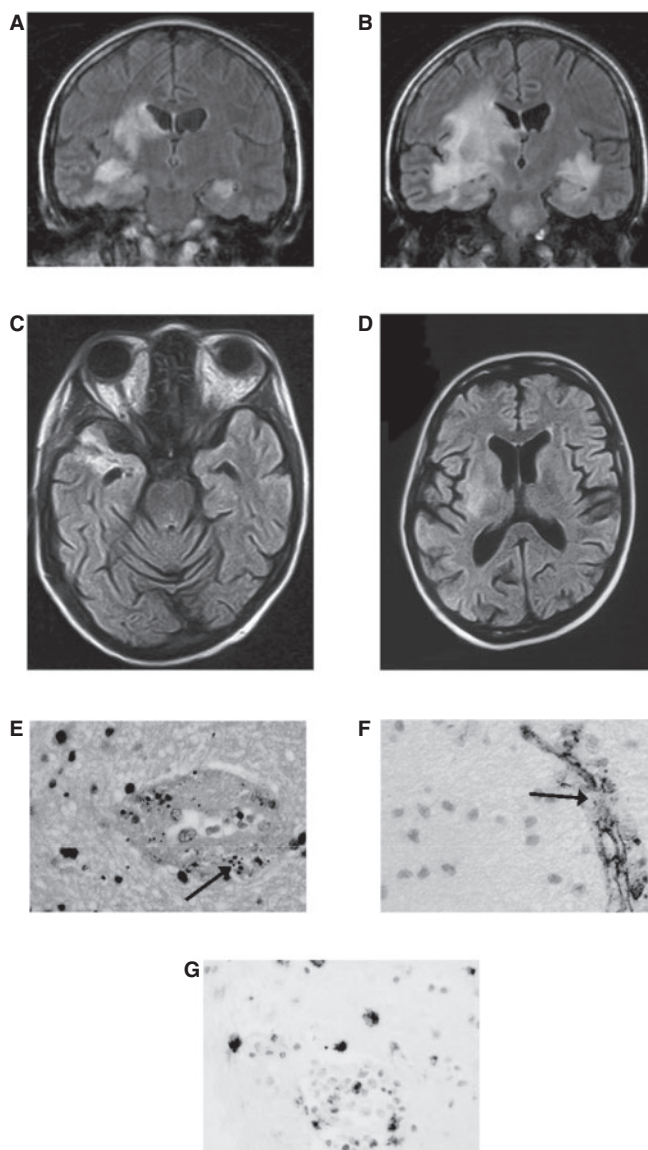


FIG. 1. MRI brain and histological appearances. (A) Initial MRI, 3 days after the onset of seizures. A coronal fluid-attenuated inversion recovery (FLAIR) sequence shows increased signal intensity in both hippocampi, which extends into the temporal white matter on the right. There is also hyperintensity of the right lentiform and caudate nuclei and internal capsule. (B) Follow-up MRI 7 days after (A). The coronal FLAIR sequence shows marked progression of the high-signal intensity areas, which now also involve the right corona radiata and insula, and left temporal white matter. In addition, there is a new lesion in the mid-brain and upper brainstem. (C, D) Axial FLAIR images performed 8 weeks after (B) show dramatic improvement. The high-signal change in the brainstem and left hemisphere has resolved. There remains some residual hyperintensity of the posterior part of right lentiform nucleus and right anterior temporal lobe, which has lost volume. (E) Haematoxylin and eosin stain showing necrosis and nuclear debris (arrow) within a small white matter vessel, consistent with a necrotising vasculitis. (F) Focal disruption of the endothelium (arrow) by inflammatory infiltrates on CD34 immunostaining. (G) Lymphocyte and macrophage infiltrates around small vessels on CD68 immunostaining.

CNS SLE vasculopathy is usually a non-inflammatory process affecting small arterioles and capillaries leading to micro-infarcts and haemorrhages [6]. CNS vasculitis presenting without systemic SLE activity is extremely rare.

The initial MRI brain in our patient showed abnormal signal in both hippocampi, unusual for SLE [7] but a common feature of viral encephalitis [8]. The clinical and radiological deterioration and the lack of response to aciclovir prompted the early decision to proceed to brain biopsy, enabling the correct diagnosis of CNS vasculitis to be made and for immunosuppression to commence [9].

This case highlights the importance of considering active CNS lupus even in the absence of both clinical systemic activity and immunological markers for SLE. A high index of clinical suspicion led to the correct diagnosis of CNS SLE vasculitis.

### Rheumatology key message

- CNS vasculitis in SLE although rare may occur without evidence of systemic disease activity.

*Disclosure statement:* The authors have declared no conflicts of interest.

C. M. EVERETT<sup>1</sup>, T. D. GRAVES<sup>1</sup>, S. LAD<sup>1</sup>, H. R. JÄGER<sup>2</sup>,  
M. THOM<sup>3</sup>, D. A. ISENBERG<sup>4</sup>, M. G. HANNA<sup>1</sup>

<sup>1</sup>Department of Molecular Neuroscience and Centre for Neuromuscular Disease, Institute of Neurology and the National Hospital for Neurology & Neurosurgery, <sup>2</sup>Lysholm Department of Neuroradiology, National Hospital for Neurology and Neurosurgery, Queen Square, <sup>3</sup>Department of Neuropathology, Institute of Neurology, Queen Square House, London WC1N 3BG and <sup>4</sup>Centre For Rheumatology Research, University College London, The Windeyer Building, 46 Cleveland Street, London W1T 4JF, UK

Accepted 3 September 2007

Correspondence to: M. G. Hanna, Department of Molecular Neuroscience and Centre for Neuromuscular Disease, Institute of Neurology and the National Hospital for Neurology and Neurosurgery, Queen Square, London WC1N 3BG, UK. E-mail: m.hanna@ion.ucl.ac.uk

- Hay EM, Bacon PA, Gordon C *et al*. The BILAG index: a reliable and valid instrument for measuring clinical disease activity in systemic lupus erythematosus. *Q J Med* 1993;86:447–58.
- Nived O, Sturfelt G, Liang MH, De Pablo P. The ACR nomenclature for CNS lupus revisited. *Lupus* 2003;12:872–6.
- Mikdashi J, Handwerker B. Predictors of neuropsychiatric damage in systemic lupus erythematosus: data from the Maryland lupus cohort. *Rheumatology* 2004;43:1555–60.
- Devinsky O, Petito CK, Alonso DR. Clinical and neuropathological findings in systemic lupus erythematosus: the role of vasculitis, heart emboli, and thrombotic thrombocytopenic purpura. *Ann Neurol* 1988;23:380–4.
- Hanly JG, Walsh NM, Sangalang V. Brain pathology in systemic lupus erythematosus. *J Rheumatol* 1992;19:732–41.
- Ellis SG, Verity MA. Central nervous system involvement in systemic lupus erythematosus: a review of neuropathologic findings in 57 cases, 1955–1977. *Semin Arthritis Rheum* 1979;8:212–21.
- Graham JW, Jan W. MRI and the brain in systemic lupus erythematosus. *Lupus* 2003;12:891–6.
- Kennedy PG. Viral encephalitis: causes, differential diagnosis, and management. *J Neurol Neurosurg Psychiatry* 2004;75(Suppl 1):i10–5.
- Sanna G, Bertolaccini ML, Mathieu A. Central nervous system lupus: a clinical approach to therapy. *Lupus* 2003;12:935–42.

*Rheumatology* 2008;47:109–110

doi:10.1093/rheumatology/kem230

Advance Access publication 27 November 2007

### Methotrexate pneumonitis precipitated by switching from oral to parenteral administration

SIR, Methotrexate pneumonitis is well recognized as an acute respiratory illness which can complicate rheumatoid arthritis (RA) in around 1 in every 100 patient-years of methotrexate (MTX) therapy [1]. Mortality is significant at ~25% [2, 3], and the differential diagnosis includes atypical infection and RA-related interstitial pulmonary fibrosis. Most cases have been reported to occur within the first year of treatment with oral therapy, and are often idiosyncratic. However, it is established that patients with underlying lung disease are at an increased risk of MTX pneumonitis [4]. We report a case of pneumonitis

occurring in an RA patient 4 weeks after switching from oral MTX to subcutaneous administration, and highlight the reasons for this.

A 71-year-old lady presented with inflammatory polyarthritis in early 2004, and was found to be sero positive (RF 1/160) with radiological evidence of erosions. She was initially started on salazopyrin, which was soon discontinued due to nausea and rash, and was replaced with oral MTX in June 2004. This was gradually increased up to a dose of 20 mg weekly, and hydroxychloroquine was added in 2005. Clinical response was poor, so in August 2006, she was converted from oral to subcutaneous administration of MTX (20 mg). Her past medical history was otherwise unblemished and her exercise tolerance previously unlimited. Chest X-ray was normal as was spirometry, although her transfer factor was only 58% predicted prior to commencing oral MTX in 2004. She has a 40 pack-year smoking history.

She was admitted 6 weeks after commencing subcutaneous MTX with a 10-day history of increasing shortness of breath (SOB), exercise tolerance reduced to 10 yards, a dry cough and fever. She had bibasal lung crackles and severe hypoxia (pO<sub>2</sub> 6.7 on room air), without finger clubbing or fever. Her white cell count and renal function were normal, but CRP was elevated at 324. Chest X-ray showed basal reticular shadows bilaterally, and high resolution CT showed basal ground glass shadowing with no underlying pulmonary fibrosis.

A diagnosis of MTX pneumonitis was suspected and treatment with high-dose steroids, oxygen and folinic acid was commenced [5]. Bronchoalveolar lavage was performed to exclude atypical infection. Pulmonary function was performed and compared to baseline values from 2 yrs earlier. She had a restrictive defect with a marked reduction in transfer factor of 29% predicted. She made a full recovery over the following 10 days and treatment with an alternative disease-modifying drug is planned.

MTX pneumonitis may be precipitated by changing the route of drug administration. This is most likely in older patients with baseline impairment of gas transfer and reinforces the need for full pulmonary function testing at commencement of MTX therapy. Increased bioavailability of MTX as a result of eliminating variation in gut absorption may account for the increased efficacy of parenteral over oral treatment. We suggest that this may precipitate pneumonitis in susceptible individuals, and that clinicians consider reducing the weekly dose by 2.5 mg when switching patients to parenteral therapy.

### Rheumatology key message

- We recommend lowering the dose of methotrexate by 2.5 mg when switching from oral to S/C administration.

*Disclosure Statement:* The authors have declared no conflicts of interest.

K. COLLINS, H. ASPEY, A. TODD, V. SARAVANAN, M. RYNNE,  
C. KELLY

*Rheumatology and General Medicine, Queen Elizabeth Hospital, Gateshead, Tyne and Wear, UK*

Accepted 23 July 2007

Correspondence to: C. Kelly. E-mail: clive.kelly@ghnt.nhs.uk

- Grove ML, Hassell AB, Hay EM, Shadforth MF. Adverse reactions to disease modifying anti rheumatic drugs in clinical practice. *Q J Med* 2001;94:309–19.
- Imokawa S, Colby TV, Leslie KO, Helmers RA. Methotrexate pneumonitis: review of the literature and histopathological findings in nine patients. *Eur Respir J* 2000;15:373–81.