

Pseudohysterical Hemiparesis

Yutaka Tanaka, MD,* Martin L. Albert, MD,†‡§ Masao Miyazaki, MD,|| and Koji Fujita, MD¶

Abstract: Four patients with the diagnosis of hysterical hemiparesis and normal magnetic resonance imagings were referred to us for further evaluation. All were being treated with antidepressant or anti-anxiety drugs or both, with no benefit. In all 4 cases single photon emission computed tomography revealed decreased regional cerebral blood flow in frontal regions in cortical areas corresponding to their neurologic deficits. In all 4 cases improvement followed neurologic treatment. We suspect that reduced blood flow in frontal regions may have produced the neurologic deficits. We call these conditions “pseudohysterical hemiparesis.”

Key Words: Neurological diagnosis, hemiparesis, hysteria.

(*J Nerv Ment Dis* 2007;195: 874–876)

Neurologists are often called upon to distinguish conversion reaction from organic neurologic disease. Conversion reaction as a cause of hemiparesis (hysterical hemiparesis) is rare (Halligan et al., 2000; Keane, 1986; Mannen and Imamura, 1967). Neural concomitants of such a syndrome are unknown. Reports suggest that cortical regions may be functionally impaired in individuals with depressive states associated with conversion reactions (Maes et al., 1993; Someya et al., 1997; Yazici and Kostakoglu, 1998; Yoshida et al., 2002). In this article, we present the findings of clinical evaluations and ancillary studies in 4 patients, originally diagnosed with hysterical hemiparesis.

CASE REPORTS

Case 1 was a 64-year-old, right-handed man with a history of hypertension. His chief complaint was visual impairment affecting his ability to drive, precipitated by stress at work. He ran his own foundry, but the business situation was deteriorating. When the problem began, he noticed that he hit

the left side of his body against a drawer and he leaned to the left when sitting in a chair. Thereafter, he had frequent falls. He was fearful when driving, due to a perceived loss of depth perception. Neuropsychological evaluation revealed left unilateral neglect, constructional apraxia, impairment of visual depth perception, and impairment of clock drawing. He had no visual field defect. He had slight dysarthria and mild left hemiparesis, but his deep reflexes were normal without Babinski signs. All laboratory data were normal. His carotid echogram and brain magnetic resonance imaging (MRI) (T1-weighted MR image, Figure 1) revealed no abnormal findings. He was given a diagnosis of conversion reaction with depression, and treated with selective serotonin reuptake inhibitors (SSRIs) and diazepam with no improvement. A subsequent evaluation of regional cerebral blood flow (rCBF) was carried out with 99m-Technetium ethylcysteinate dimmer-single photon emission computed tomography (ECD-SPECT; Figure 1), demonstrating decrease in rCBF in the right orbitofrontal and dorsolateral frontal regions. He was treated with 60,000 units of urokinase and his symptoms improved.

Case 2 was a 46-year-old, right-handed man with a history of insulin-dependent diabetes mellitus. Onset of his illness was abrupt with mild right-sided weakness, dysarthria, and paresthesia on the right half of his face. His present illness was preceded by severe stress at his job as a computer programmer. Ten days after onset, the right hemiparesis progressed. On admission, his Mini Mental State Examination was 28/30 and Hamilton Depression Score was 26/60. He had dysarthria and right hemiparesis. His deep reflexes were decreased without Babinski signs. Sensory examination revealed decreased superficial sensation on right upper and lower limbs. Laboratory data were normal except for his blood sugar (198 mg/dL) and HbA1c (7.8%). His T1-weighted MRI (Figure 2) and magnetic resonance angiography were normal. He was given the diagnosis of hysterical hemiparesis due to depression, and treated with SSRIs and diazepam with no effect. A 99m-Technetium ECD-SPECT scan (Figure 2) revealed a decrease in rCBF in the left dorsolateral frontal and thalamic regions. He was then treated with 60,000 units of urokinase with improvement in his hemiparesis and sensory impairment. His depression, however, remained unchanged.

Case 3 was a 41-year-old, right-handed woman with a history of chronic hepatitis B. Her chief presenting complaint was left hemiparesis. Her present illness was preceded by severe troubles at home: she quarreled with her husband and felt mentally tormented. After a 2-week period, during which she felt as if her body was swollen, she suddenly developed left hemiparesis and hemiparesthesia. On examination, she

*Neurology, Tanaka Clinic, Nara, Japan; †Harold Goodglass Aphasia Research Center VA Health Care System, Boston, Massachusetts; ‡Department of Neurology, Boston University School of Medicine, Boston, Massachusetts; §VA Boston Health Care System, Boston, Massachusetts; ||Department of Neurology, Ise Keiyu Hospital, Ise, Mie, Japan; and ¶Department of Internal Medicine, Sakakibara Onsen Hospital, Tsu, Mie, Japan.

Supported in part by the National Institutes of Health (NIDCD) and the Medical Research Service of the Department of Veterans Affairs.

Send reprint requests to Yutaka Tanaka, MD, Tanaka Clinic, 124 Shiomagito, Heguri-Cho, Ikoma-Gun, Nara, 636-0933, Japan. E-mail: EZZ05540@nifty.com.

Copyright © 2007 by Lippincott Williams & Wilkins

ISSN: 0022-3018/07/19510-0874

DOI: 10.1097/NMD.0b013e31815688cd

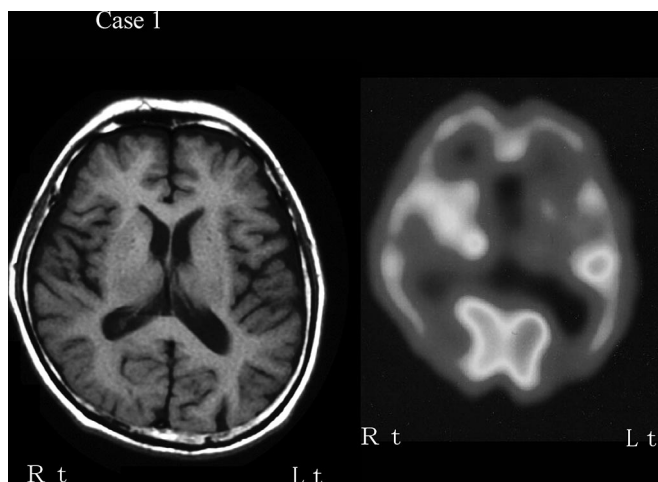


FIGURE 1. MRI and SPECT findings of case 1. Left: T1-weighted MR image (TR/TE = 300/14.0 milliseconds). Right: ECD-SPECT.

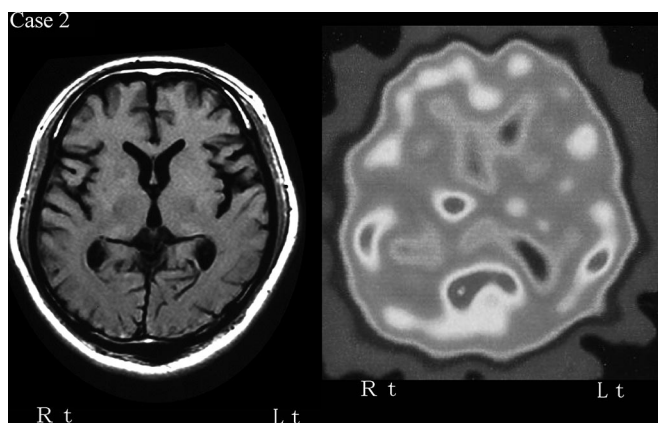


FIGURE 2. MRI and SPECT findings of case 2. Left: T1-weighted MR image (TR/TE = 450/18.0 milliseconds). Right: ^{123}I -IMP (early image).

had a left hemiparesis, with increased deep tendon reflexes, but no Babinski sign. Superficial sensation was slightly decreased in her left leg. Her attention and orientation abilities were slightly diminished. Her Hamilton Depression Score was 29/60. The sole abnormal finding in her blood laboratory work-up was mild anemia. Her T1-weighted MRI (Figure 3) was normal. She was given the diagnosis of conversion reaction secondary to depression, and was treated with SSRI's and diazepam with no improvement. ECD-SPECT (Figure 3) revealed a decrease in rCBF in the right frontal region. After treatment with urokinase, her neurologic symptoms resolved, although she continues to have mild depression.

Case 4 was a 40-year-old, right-handed woman with an unremarkable health history. Her chief presenting complaint was left hemiparesis. For some time, after her father died, she had an ongoing disagreement with her relatives over an inheritance. In addition, she had conflict in the marital relationship. She was in torment and fatigued easily. One day,

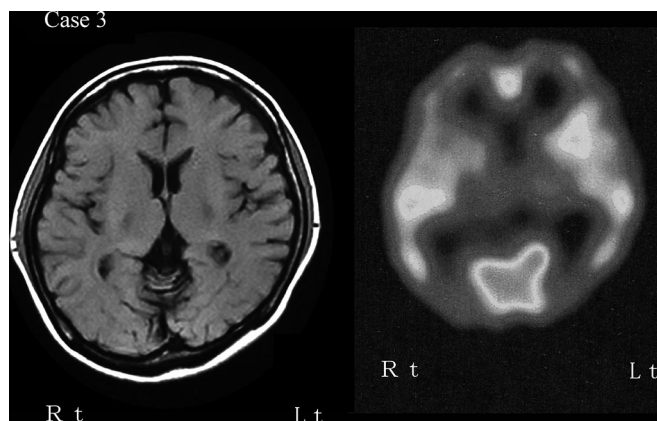


FIGURE 3. MRI and SPECT findings of case 3. Left: T1-weighted MR image (TR/TE = 450/18.0 milliseconds). Right: ECD-SPECT.

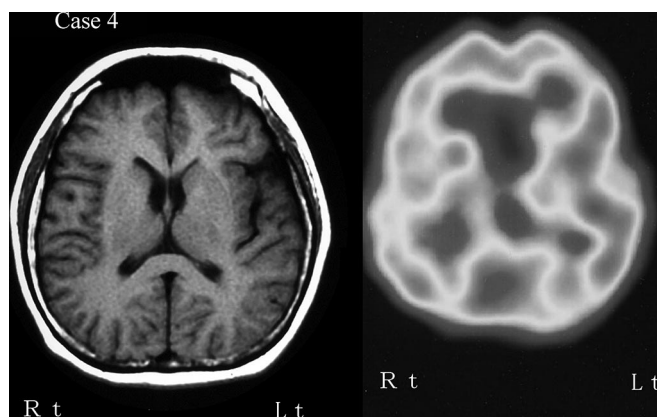


FIGURE 4. MRI and SPECT findings of case 4. Left: T1-weighted MR image (TR/TE = 300/14.0 milliseconds). Right: ^{123}I -IMP SPECT (early image).

during this period she suddenly developed vertigo and dysarthria. When we saw her, she was depressed, and carried the diagnosis of functional neurologic deficit. On examination, she had a quite noticeable rash on her face. She had neither nystagmus nor dysarthria, but a mild left hemiparesis was present. Tandem gait was normal and Romberg sign was absent. She had a mild, left hemihypesthesia. Her Hamilton Depression Score was 20/60. Her T1-weighted MRI (Figure 4) was normal. On further evaluation, we found her ^{123}I -iodoamphetamine SPECT (Figure 4) to reveal a decrease in rCBF in the right posterior lateral frontal and thalamic regions. Titers of antinuclear antibody and immune complex were high. We suspected that her symptoms were the consequence of a vasculitis and treated her with steroids. Her symptoms improved temporarily, but when we discontinued steroids, her symptoms deteriorated. Treatment again with steroids caused the neurologic signs and rash to disappear, although her depression has persisted.

DISCUSSION

Stress and depression may induce focal neurological signs with no evidence of organic lesions in the brain. Such

cases are termed hysterical hemiparesis or conversion reaction (Halligan et al., 2000; Keane, 1986; Mannen and Imamura, 1967). The diagnosis of conversion reaction or functional neurologic deficit is all too easy to make when no obvious cause of neurologic deficit is discerned, especially, as in these cases when the MRI is normal. However, as these cases demonstrate, correlations among depression, neurologic signs, and decreased cerebral blood flow may be relevant. A negative MRI does not rule out the possibility that a cerebral metabolic abnormality may be the cause of the neurologic deficit. Abundant evidence now documents a correlation between stress, depression, and reduced cerebral blood flow (Maes et al., 1993; Someya et al., 1997; Yazici and Kostakoglu, 1998, Yoshida et al., 2002). In all of our patients SPECT revealed decreased rCBF in frontal regions, in cortical areas associated with their specific symptoms. For all 4 patients improvement followed neurologic treatment. We suspect that stress or depression or both caused reduced blood flow in frontal regions in these patients, producing their neurologic deficits. Perhaps these clinical conditions could be called "pseudohysterical hemiparesis."

ACKNOWLEDGMENTS

The authors thank Lisa Connor, PhD, and Nicola Wolfe, PhD, for comments and advice in preparation of this article.

REFERENCES

- Halligan PW, Athwal BS, Oakley DA, Frackowiak RS (2000) Imaging hypnotic paralysis: Implications for conversion hysteria. *Lancet*. 355:986–987.
- Keane JR (1986) Wrong-way deviation of the tongue with hysterical hemiparesis. *Neurology*. 36:1406–1407.
- Maes M, Dierckx R, Herbert Y, Meltzer HY, Ingels M, Schotte C, Vandewoude M, Calabrese J, Cosyns P (1993) Regional cerebral blood flow in unipolar depression measured with Tc-99m-HMPAO single photon emission computed tomography: Negative findings. *Psychiatry Res*. 50:77–88.
- Mannen S, Imamura MJ (1967) Babinski: Organic hemiparesis and hysterical hemiparesis. *Shinkei-Shinpo*. 11:662–674 (in Japanese).
- Someya T, Ozeki Y, Teng Cheuk Y, Buchsbaum MS (1997) Abnormalities of regional cerebral blood flow in major depressive disorders; comparisons between depressive state, euthymic state and normal controls. *Rhinsho Seishin Igaku*. 26:523–532 (in Japanese).
- Yazici KM, Kostakoglu L (1998) Cerebral blood flow changes in patients with conversion disorder. *Psychiatr Res*. 83:163–168.
- Yoshida T, Ha-Kawa S, Yoshimura T, Minami T, Kinoshita T, Sawada S (2002) 99m Tc-ECD Brain perfusion SPECT for evaluation of major depressive disorder. *Jpn J Med Imaging*. 21:61–66 (in Japanese).