

Unravelling Boléro: progressive aphasia, transmodal creativity and the right posterior neocortex

William W. Seeley,¹ Brandy R. Matthews,¹ Richard K. Crawford,¹ Maria Luisa Gorno-Tempini,¹ Dean Foti,² Ian R. Mackenzie³ and Bruce L. Miller¹

¹Memory and Aging Center, Department of Neurology, UCSF, ²Department of Medicine, Division of Neurology, and

³Department of Pathology, University of British Columbia, Canada

Correspondence to: William W. Seeley, M.D., Box 1207, 350 Parnassus Ave, Ste. 706, San Francisco, CA 94143-1207, USA.

E-mail: wseeley@memory.ucsf.edu

Most neurological lesion studies emphasize performance deficits that result from focal brain injury. Here, we describe striking gains of function in a patient with primary progressive aphasia, a degenerative disease of the human language network. During the decade before her language deficits arose, Anne Adams (AA), a life-long scientist, developed an intense drive to produce visual art. Paintings from AA's artistic peak revealed her capacity to create expressive transmodal art, such as renderings of music in paint, which may have reflected an increased subjective relatedness among internal perceptual and conceptual images. AA became fascinated with Maurice Ravel, the French composer who also suffered from a progressive aphasia, and painted his best-known work, 'Boléro,' by translating its musical elements into visual form. Later paintings, achieved when AA was nearly mute, moved towards increasing photographic realism, perhaps because visual representations came to dominate AA's mental landscape during this phase of her illness. Neuroimaging analyses revealed that, despite severe degeneration of left inferior frontal-insular, temporal and striatal regions, AA showed increased grey matter volume and hyperperfusion in right posterior neocortical areas implicated in heteromodal and polysensory integration. The findings suggest that structural and functional enhancements in non-dominant posterior neocortex may give rise to specific forms of visual creativity that can be liberated by dominant inferior frontal cortex injury.

Keywords: primary progressive aphasia; corticobasal degeneration; voxel-based morphometry; cross modal integration; creativity

Abbreviations: AA = Anne Adams; CBD = corticobasal degeneration; IFC = inferior frontal cortex; PPA = primary progressive aphasia; STS = superior temporal sulcus; VBM = voxel-based morphometry.

Received July 14, 2007. Revised and Accepted October 8, 2007. Advance Access publication December 5, 2007

Introduction

Highly creative individuals weave together drive, skill and imagination to generate new ideas and actions. Artists further employ the ability to link related sensory, conceptual and emotional images through a chosen output medium. Despite the importance of artistic creativity in human affairs, brain mechanisms underlying this capacity have remained mysterious and difficult to study. Innovators across disciplines, however, have often suffered from neuropsychiatric illness (Post, 1994), suggesting that patients with focal brain lesions may help reveal how the brain supports the creative process. Visual artistic skills are often impaired after posterior cortical lesions, especially when the non-dominant hemisphere is affected (Grossman, 1988; Kleiner-Fisman *et al.*, 2003). In contrast, new or improved

visual creativity may emerge in the context of focal anterior brain disease (Miller *et al.*, 1998; Chatterjee, 2004). This report seeks to explore how anterior and posterior systems interact to support visual artistic creativity.

Primary progressive aphasia (PPA) is a neurodegenerative condition that slowly erodes speech and language functions (Mesulam, 1982). Some patients with PPA develop new artistic or musical abilities, offering a potential window into the creative process (Miller *et al.*, 1996; Miller *et al.*, 1998; Miller *et al.*, 2000). PPA deficits result from atrophy of the dominant perisylvian cortex, and patients with a frontal-insular variant develop difficulty with grammar, syntax and articulation in conjunction with non-fluent, effortful and apractic speech (Gorno-Tempini *et al.*, 2004a). Even PPA patients without new talents show superior visuospatial

cognition when compared to other dementia patients (Mendez *et al.*, 1996). PPA describes a broad clinical syndrome (Gorno-Tempini *et al.*, 2004a); its underlying histopathology is most often corticobasal degeneration (CBD), progressive supranuclear palsy, frontotemporal lobar degeneration or Alzheimer's disease (Mesulam, 2001; Josephs *et al.*, 2006; Knibb *et al.*, 2006).

Perhaps the most famous patient with a PPA-related illness was Maurice Ravel (1875–1937), the French composer who developed a progressive language and motor disorder during the late stages of his career. Ravel completed his best-known work, 'Boléro', in 1928, at age 53. 'Boléro' alternates between two main melodic themes, repeating the pair eight times over 340 bars with increasing volume and layers of instrumentation. In parallel, the piece holds methodically to two simple, alternating, staccato bass lines. 'Boléro' is an exercise in compulsivity, structure and—some have suggested—perseveration (Amaducci *et al.*, 2002), that builds without a key change until its 326th bar, when it stridently accelerates into a collapsing finale. Ravel's illness may have begun, subclinically, around the time 'Boléro' was composed, when his handwriting began to deteriorate (Alonso and Pascuzzi, 1999; Amaducci *et al.*, 2002). Overt declines, at first limited to spelling errors in musical scores and letters, were indisputable by 1931 (Cardoso, 2004). Symptoms progressed relentlessly thereafter. Speech and language declined, with halting and frustrated output but relatively preserved comprehension for both language and music (Alajouanine, 1948). Prominent apraxia and right-sided motor deficits later accompanied his aphasia, prompting recent suspicions that the underlying histopathology was CBD (Baeck, 1996; Amaducci *et al.*, 2002). Ravel died due to complications of an attempted neurosurgical treatment in 1937.

In this report, we describe Anne Adams (AA, 1940–2007), a patient with the frontal-insular form of PPA who developed new and extraordinary visual creativity during the course of her illness. Initially unaware of her illness and knowing nothing of Ravel's, AA became fascinated with Ravel and translated 'Boléro' into visual form, painting the elements of each bar with vigorous attention to detail and structure. We highlight the evolution of AA's art, from her preclinical phase through her progressive dementia. We focus on her tribute to Ravel, 'Unravelling Boléro', which captures the emergent trans-modal creativity she enjoyed during the early stages of her illness. Finally, we provide convergent structural and functional imaging evidence that specific regions within AA's non-dominant posterior neocortex were not only intact but enhanced in structure and function. This report is the first to correlate a lesion-related gain of artistic function with localized neural tissue enhancements. The findings provide a new functional-anatomic framework for understanding human artistic creativity.



Fig. 1 Early work. AA painted 'Hennings Building' in 1991, 9 years before her PPA symptoms began. Watercolour.

Case description

AA biography, clinical features and artistic timeline

At the time of her death, AA was a 67-year-old right-handed woman. She graduated from college with honours degrees in physics and chemistry and was married to Robert Adams, a mathematician. After college, she taught college chemistry for 3 years before taking a 14-year academic hiatus to raise her four children. At age 35, she returned to school and studied rat ovarian surface epithelium *en route* to a doctorate in cell biology. She held academic positions for 4 years thereafter until age 46, when her son was involved in a life-threatening motor vehicle accident. AA took leave from academics, expecting to care for her son during a protracted recovery. Around this time, she began to paint. Her son quickly recovered, but she continued to paint, deciding not to return to academics. AA had a lifelong interest in art and music and occasionally pursued painting as a hobby, but she was not an accomplished painter, and her early work consisted of simple drawings and architectural watercolours (Fig. 1). Classical perspective and muted colour schemes predominated, and she made few attempts to portray non-visual sensory information.

Over the ensuing 6 years, however, her artistic interests evolved. She spent increasing time in her studio, often the majority of her waking hours. By the time AA was 52,



Fig. 2 Emergent transmodal creativity. AA painted 'Unravelling Boléro' in 1994, 6 years before PPA symptoms began. Gouache.

her paintings had become far more vibrant, colourful and multifaceted. She began to represent auditory stimuli in visual form through paintings such as 'Rondo alla Turquoise' and 'Rhapsody in Blue' that captured her visual interpretations of musical pieces, as well as her increasing tendency to pun. At age 53, still 7 years before PPA symptoms arose, AA began to conceive 'Unravelling Boléro' (Fig. 2). She described the piece, titled with a deliberate play on words, as a visual analysis of 'Boléro'. Following a scheme laid out in exacting, compulsive detail (Supplementary Fig. 1), AA translated Ravel's score into a serpentine array of vertical figures assembled into rows, which wind in 'zig-zag' fashion across each panel of the diptych display. At age 58, 4 years after completing 'Unravelling Boléro', she shifted from painting music to painting more abstract concepts, including numbers. One such piece, named 'pi', maps a 32×46 digit matrix of coloured squares onto the first 1471 digits of pi (plus the decimal point), assigning white, black and constituent colours of the white light spectrum to each integer from zero to nine (Fig. 3). AA reported no speech or language deficits throughout this period of intense creativity.

AA's first definite language symptoms began around age 60, when her speech initiation faltered and she began

to make errors in grammar. Comprehension remained intact, and she communicated well with nonverbal methods. Other cognitive domains were spared for at least 2 years. During this period, AA's paintings moved unmistakably toward photographic realism, reproducing the visual world with high surface fidelity. Symmetry and structural detail were emphasized (Fig. 4), and she often painted natural objects or buildings (Figs 5 and 6). Over time, her fluency deteriorated, and when first seen at our centre at age 64, AA was nearly mute. She often required 10–15 s to initiate speech, and her best efforts resulted in 3–4 word phrases (Supplementary Video). She remained socially composed though easily frustrated. Her neurological examination was otherwise unremarkable. AA's medical history was notable only for long-standing migraines and a left acoustic neuroma, which had resulted in mild hearing loss. She took only donepezil, without benefit. Neuropsychological testing (see Supplementary Methods) revealed deficits limited to speech, language and executive functions, as well as a tendency to perseverate. Table 1 compares AA's neuropsychological test performance to that of 30 age-matched, highly educated, right-handed healthy women who served as controls in our structural neuroimaging analyses.




Fig. 3 In 1998, 2 years before PPA symptoms, AA painted 'pi', in which she transformed the decimal expansion of pi into a visual matrix to capture the random nature of that expansion. Rather than translating one sensory modality into another as in 'Unravelling Boléro', in 'pi' AA translates an abstract, conceptual image (numerical randomness) directly into visual form. Gouache.



Fig. 4 In 2000, as her PPA symptoms arose, AA painted an 'ABC Book of Invertebrates'. Each letter of the alphabet was assigned an organism, which was painted in mandala format. Examples shown include (from upper left, clockwise): 'E' for earthworm, 'O' for octopus, 'R' for rotifer and 'P' for peacock worm. This period revealed AA's increasing tendency to render symmetric images. Gouache.

After her UCSF evaluation, AA's illness progressed rapidly, with worsening limb apraxia and right upper extremity dystonia that impeded painting. Her gait became shuffling. She ceased to communicate verbally but interacted with her husband through gestures and picture symbols. This constellation of symptoms suggested underlying CBD. Anne Adams died at age 67 due to progressive neurological decline with severe motor and respiratory impairment resulting in aspiration pneumonia.

Artistic composition analysis: transmodal creativity in 'Unravelling Boléro'

AA's extensive notes on 'Unravelling Boléro' reveal her fascination with Ravel's composition and artistry, as well as her own extraordinary attention to detail (Table 2, Supplementary Fig. 1). The painting includes one upright rectangular figure for each of 'Boléro's' bars. AA's artistic choices, combined with the repetitive nature of 'Boléro', result in an orderly arrangement of figures, countered by her use of the zig-zag winding scheme. The height of AA's figures grows in parallel with the volume of Ravel's orchestra, and the colour scheme remains unified until the surprise key change in bar #326, which AA marked with a run of visually salient orange and pink bars that herald 'Boléro's' dramatic conclusion (Fig. 7).

Some facets of music, such as rhythm or intensity, retain their meaning whether presented through auditory or visual media. Through crossmodal matching, the brain can determine, for example, whether a tone and light have been presented for an equal duration or with the same cadence (Calvert, 2001). Other musical elements, like pitch, are purely auditory and have no natural visual analogue. Pitch can, however, be represented visually through abstract symbols, as in musical notation, or through any other chosen representational scheme. In 'Unravelling Boléro', AA performed three types of auditory to visual transformation (Table 2). For intensity, rhythm and duration, she performed direct transformations, choosing natural visual analogues for auditory elements (e.g. height for volume when considering intensity). For elements without a concrete intermodal representation, she performed more abstract transformations (e.g. shape for note quality, perhaps when considering musical texture). For still other elements, she applied her own aesthetic preferences to create novel transmodal schemes (e.g. colour for pitch, see Supplementary Fig. 1). AA's husband relates that she did not report synaesthetic phenomena, such as seeing colours while hearing notes; rather, she created such associations internally before rendering them in paint.

Neuroimaging analyses

Structural MRI and voxel-based morphometry (VBM)

To follow her acoustic neuroma, AA underwent surveillance MR imaging of the base of the brain from 1997 onwards,



Fig. 5 Increasing photographic realism. In 2002, 2 years after her illness became clinically apparent, AA painted ‘Arbutus leaves’, which reflects a trend toward increasingly photographic reproductions of stimuli she encountered. Gouache.



Fig. 6 In 2004, AA painted ‘Amsterdam’ shortly before her UCSF evaluation. At UCSF, she could scarcely communicate through spoken language but her motor examination was unremarkable. ‘Amsterdam’ was one of many paintings from this period that focused on buildings, with a particular emphasis on facades and surrounding surfaces. Gouache.

Table 1 Demographic and neuropsychological variables for AA and 30 healthy female control subjects used in neuroimaging analyses

	AA	Controls ^a
Age	64.0	67.3 (7.7)
Education (years)	20.0	17.8 (1.8)
MMSE (max. = 30)	20.0	29.6 (0.6)
CVLT–SF 4 trials (max. = 36)	17.0	30.8 (3.2)
CVLT–SF 30-s recall (max. = 9)	6.0	8.5 (1.2)
CVLT–SF 10-min recall (max. = 9)	5.0	7.8 (1.9)
Modified Rey-O copy (max. = 17)	15.0	16.3 (1.0)
Modified Rey-O delayed recall (max. = 17)	12.0	12.8 (2.3)
Digit Span Backwards	2.0	5.5 (1.1)
Modified Trails (correct lines/min)	6.5	34.2 (11.3)
Modified Trails (errors)	2.0	0.1 (0.3)
Design Fluency (correct designs/l min)	3.0	10.4 (2.9)
Design Fluency (correct repetitions/l min)	5.0	1.9 (2.8)
M and N (perseverations)	2.0	0.1 (0.4)
Phonemic Fluency (‘D’ words/l min)	1.0	16.3 (4.8)
Semantic Fluency (animals/l min)	4.0	23.8 (5.4)
Abbreviated BNT (max. = 15)	11.0	14.6 (1.0)
Calculations (max. = 5)	3.0	4.9 (0.3)

^aData shown for controls indicate mean (SD). BNT = Boston Naming Test; CVLT–SF = California Verbal Learning Test—Short Form; MMSE = Mini Mental State Examination. See Supplementary Methods for a description of the neuropsychological battery.

well before she was scanned for her language symptoms. These images provide a rare glimpse into the early degeneration of PPA and show emergent atrophy within the left inferior and opercular frontal regions, anterior insula and striatum. In Fig. 8, MRIs from 1998–2004 are shown with representative paintings from the year of each MRI. Images

Table 2 Auditory to visual mapping in AAs 'Unravelling Boléro'

Musical feature from bars of 'Boléro'	Intermodal representation	Visual feature in figures of 'Unravelling Boléro'
Volume (<i>pp</i> to <i>fff</i>)	Intensity	Height (1 to 20 U)
Time per bar (three beats)	Rhythm	Width (3 U)
Time within piece (start to finish)	Duration	Location (upper left to lower right) ^a
The 'quality' of the favourite note in each bar ^b	Texture?	Geometric shapes within top half of each figure
Bass line (pitch series)	Shape?	Contour of transverse line dividing figure
Melodic pitch ^b	None	Colour, assigning one colour for each note of the scale
Instrumentation	None	Silver, gold and copper paint overlying lower (bass line) half of figure

^aTemporally adjacent musical bars are strung together in contiguous figures that 'zig-zag' without returns at the end of each line. ^bIn her records, AA designated one note as the 'most interesting' from each treble clef bar (see also Fig. 7 and Supplementary Fig. 1).

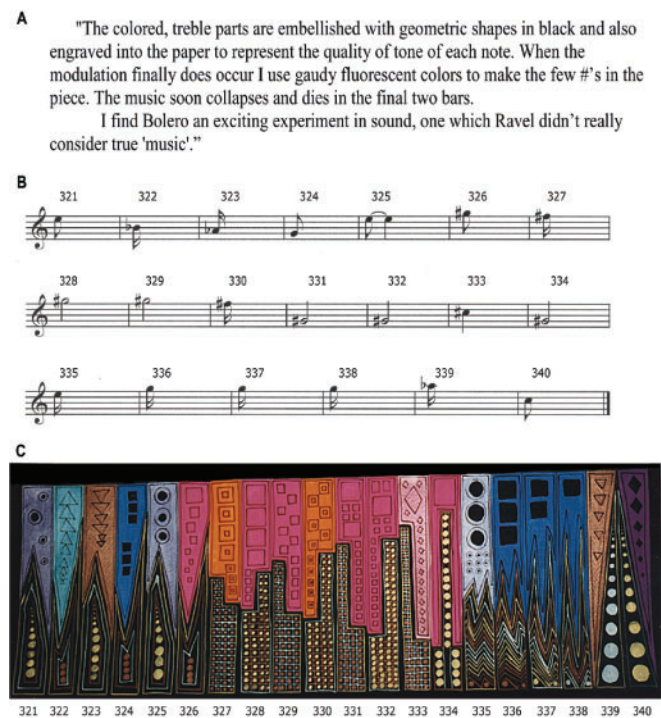


Fig. 7 Representation of the key change in Ravel's 'Boléro'. **(A)** AA recorded her plans to paint the key change in 'Boléro' (type transcribed from handwritten notes). **(B)** Musical notation representing AA's favourite or 'most interesting' treble clef notes for bars 321–340. **(C)** The excerpt from 'Unravelling Boléro' painted to represent bars 321–340. AA used both visual (musical score) and auditory (a 'Boléro' performance) inputs when composing 'Unravelling Boléro'. Never did she experience direct sensory linkage phenomena akin to synaesthesia.

covering regions superior to the frontal operculum were not available until 2002.

We used AA's 2004 UCSF MRI to compare AA's brain structure to a group of 30 age-matched, highly educated, right-handed healthy female control subjects whose characteristics are shown in Table 1. VBM, a statistical technique designed for whole-brain analysis of grey matter structure, was employed. VBM has been successfully applied to single patients with PPA (Gorno-Tempini *et al.*, 2004b),

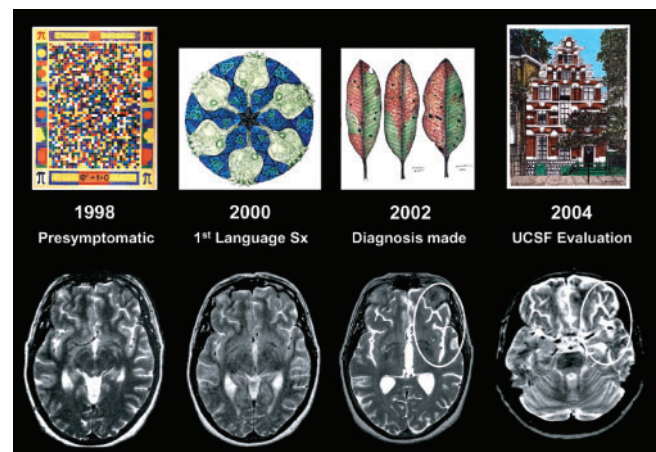


Fig. 8 Serial MRI scans performed to follow AA's acoustic neuroma, showing emergent atrophy within the left frontal operculum. Scans performed before AA's PPA diagnosis reveal no definite cortical atrophy, which becomes evident by 2002 around the left fronto-insular region, with widening of sulci and the Sylvian fissure compared to the right hemisphere (ovals). Each MRI is paired with a representative painting from the same year.

with gross pathological confirmation of regional tissue loss detected *in vivo* with VBM (Sanchez-Valle *et al.*, 2006). First, using an optimized VBM procedure (Good *et al.*, 2001), we sought brain regions with decreased grey matter content in AA compared to healthy controls (see Supplementary Methods online). As expected, AA showed significant atrophy of left inferolateral frontal cortex (including Broca's area), frontal insula and striatum, with less extensive changes in the same regions of the right hemisphere ($P < 0.001$, whole brain uncorrected, Figs 9A and 10A and Supplementary Table 1). At this threshold, atrophy was also seen in the left anterior hippocampus/uncus and left thalamus. The left inferolateral frontal ($-42, 29, 2; z = 4.64$), caudate ($-13, 9, 11; z = 5.42$), and hippocampus ($-26, -14, -20; z = 4.63$) remained significant after multiple comparisons correction across a large frontal, temporal and deep grey matter region-of-interest (ROI; $P < 0.05$, corrected for family wise error, FWE). Next, we sought brain regions in which AA showed

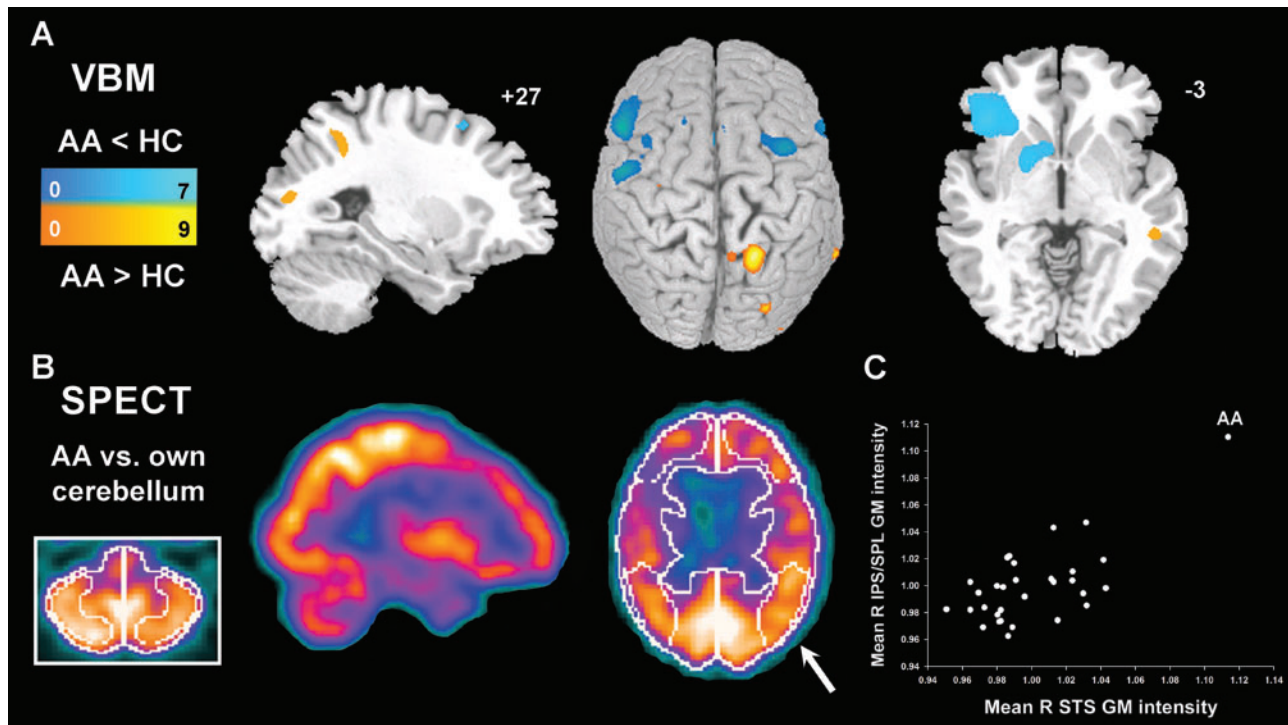


Fig. 9 Neuroimaging results. **(A)** Grey matter reductions in AA vs. controls (blue colourscale) were accompanied by focal areas of increased grey matter intensity in right posterior neocortex (orange colourscale). Bars indicate t -scores. Displayed voxels are significant at $P < 0.001$ (whole brain, uncorrected). **(B)** AA showed increased cerebral perfusion in only one ROI examined, the right parietal cortex (arrow, 112% of cerebellar baseline). **(C)** Mean grey matter intensities from right IPS/SPL and right STS ROIs (arbitrary units), plotted against each other for each subject, show the degree to which AA's values exceeded those of controls. For axial images, the left side of the image corresponds to the left side of the brain. Sagittal images are from right hemisphere. VBM data are superimposed on slice and surface-rendered images of the Montreal Neurological Institute template brain. HC = healthy controls.

increased local grey matter content, testing the hypothesis that AA would demonstrate greater volume in right posterior regions involved in visual imagery and visuoconstructive ability. Across the whole brain, we identified four areas with increased grey matter in AA vs. controls: (i) right intraparietal sulcus/superior parietal lobule (IPS/SPL); (ii) right superior temporal sulcus (STS); (iii) right parietal operculum; and (iv) right lateral occipital cortex. Of these, the IPS/SPL (BA 7; 21, -51 , 42 ; $z = 4.77$) and STS (BA 21; 49, -37 , -8 ; $z = 4.37$) remained significant after a multiple comparisons correction across a right temporo-parieto-occipital ROI ($P < 0.05$, corrected for FWE).

Cerebral perfusion imaging

In 2002, AA underwent a clinical whole-brain cerebral perfusion scan as part of her diagnostic evaluation at the University of British Columbia. Technetium ECD was injected under basal conditions, and tomographic images of the whole brain were obtained. Images were scored for regional technetium uptake as a percentage of cerebellar (baseline) uptake (Fig. 9B). This study revealed decreased perfusion in the left frontal lobe (71–85% of baseline), with lesser reductions in comparable right frontal regions

(79–99%), mirroring the atrophy pattern detected with VBM. Remarkably, of the eight cortical regions evaluated, increased perfusion was seen in only one: the same right superior parietal area (112% of baseline) that showed increased grey matter intensity in the VBM analysis.

Neuropathology

AA underwent neuropathological examination by one of the authors (I.R.M.) at the University of British Columbia, following standard dementia assessment procedures. The post-mortem brain weighed 1188 g. There was severe gross bifrontal atrophy, left worse than right, consistent with the VBM and perfusion scan findings (Fig. 10A and C). Other regions, including temporal and parietal lobes, striatum and thalamus showed more marked asymmetry, with worse left-sided atrophy. Consistent with neuroimaging evidence that AA's right parietal cortex was normal or supranormal during the peak of her creativity, at autopsy her right parietal cortex was grossly normal (Fig. 10C) whereas all other lobes were atrophic. There was moderate depigmentation of the substantia nigra.

Histopathological features (Fig. 10E–J) included non-specific degenerative changes of neuronal loss and gliosis

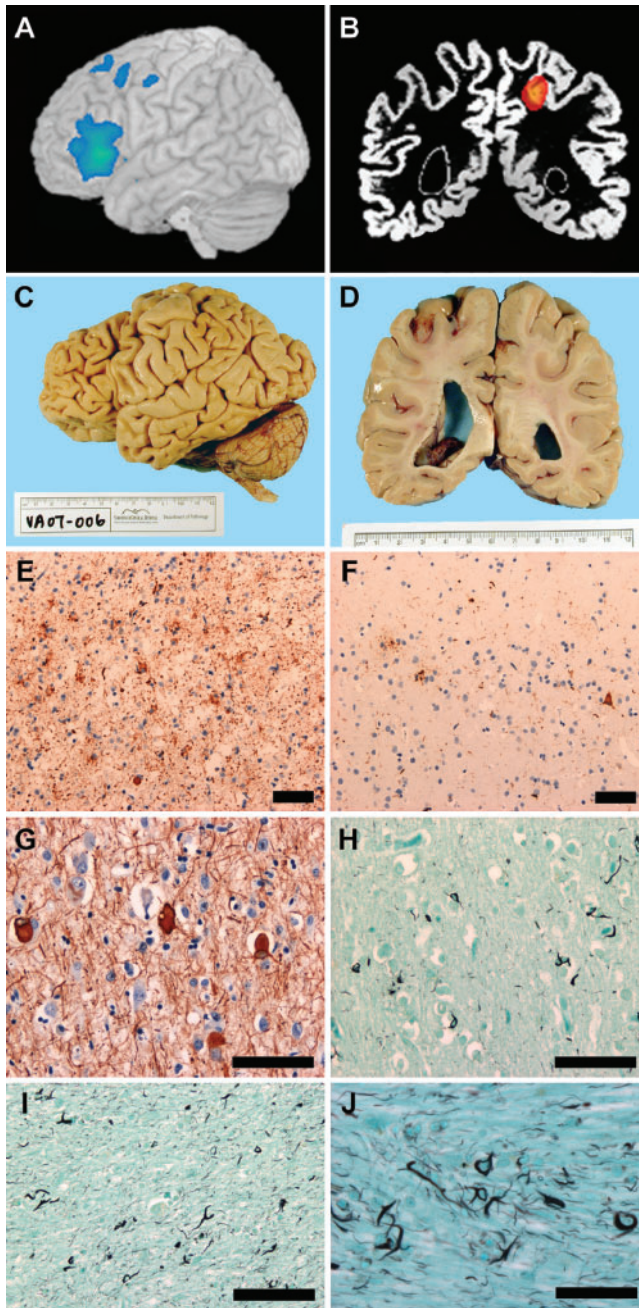


Fig. 10 Neuropathological findings. (A, C) Severe atrophy of left IFC, including Broca's area, was demonstrated with VBM (A) and at autopsy (C). The interval between MRI acquisition and death was 3 years. (B, D) VBM also revealed increased grey matter in AA vs. controls in the right IPS (B), and this region was structurally normal (or better) at autopsy (D). VBM data in (B) are superimposed on AA's segmented grey matter image to facilitate comparison with post-mortem examination. In (B) and (D), the right side of the image corresponds to the right side of the brain. (E) Tau immunohistochemistry showed severe tau pathology in left IFC, whereas right parietal cortex (F) was relatively unremarkable. (G) Ballooned neurons in deep layers of left frontal cortex (phosphorylated neurofilament stain). (H) Thorny astrocytes in frontal cortex (Gallyas silver stain). (I, J) Abundant argyrophilic pathology in subcortical white matter, including coiled bodies and numerous threads. The findings confirm a diagnosis of CBD. Scale bars represent 80 microns (C–I) and 40 microns (J).

reflecting the pattern of gross involvement, with frontal cortex severely affected while temporal and parietal cortex, striatum and thalamus were affected moderately on the left and mildly on the right. There was moderate loss of pigmented neurons from the substantia nigra. Gross and histopathological features are summarized by region in Supplementary Table 2. Abundant neuronal and glial pathology was demonstrated with tau immunohistochemistry and Gallyas silver stain. In the neocortex, neuronal inclusions included pre-tangles, small neurofibrillary tangle-like inclusions and rare dense Pick body-like inclusions. Glial pathology included numerous coiled bodies in oligodendrocytes, thorn-shaped astrocytes and abundant neuritic and thread pathology. Tufted astrocytes and astrocytic plaques were both rare. Swollen, achromatic neurons in deeper layers of the neocortex were numerous in some cortical regions and best demonstrated with phosphorylated neurofilament immunohistochemistry. The white matter was filled with tau-positive coiled bodies and thread pathology. The striatum, globus pallidus, thalamus and midbrain all demonstrated abundant tau-positive neuronal and glial pathology. Sections of medulla and spinal cord showed a normal population of lower motor neurons. No senile plaques, Lewy bodies or ubiquitinated inclusions of the motor neuron disease type were identified. Consistently, all histopathological features were more severe on the left than the right (Fig. 10 and Supplementary Table 2). Typical findings in CBD include asymmetric frontal or parietal degeneration accompanied by cortical neuronal and glial tau-immunoreactive inclusions and abundant thread and coil pathology in deep subcortical white matter. Therefore, AA's neuropathology was most consistent with a pathological diagnosis of CBD.

Discussion

Art reflects the inner world of the artist, whether the artist is healthy or diseased. We studied an exceptional artist, AA, whose visual creativity arose and intensified as her language system began to degenerate. AA's artistic timeline suggests that, early in the course of left fronto-insular degeneration, she experienced a heightened relatedness among internal perceptual and conceptual images. At her creative peak, AA painted 'Unravelling Boléro', in which she translated Ravel's music into a visual image through concrete, abstract and novel intermediary representations (Table 2). Structural and functional imaging analyses converged to suggest that, in AA, right posterior regions had undergone localized enhancements within heteromodal associative (IPS/SPL) and polymodal (STS) neocortices. In the healthy brain, these areas help to integrate multimodal perceptual data with each other, possibly through abstract, conceptual representations. Taken together, these observations suggest that intense connectivity among non-dominant posterior neocortices may support certain forms of transmodal creativity that are inhibited, at least in part, by the healthy dominant IFC.

Artistic timeline in relation to PPA symptoms

While PPA may enhance artistic creativity even before language deficits arise (Miller *et al.*, 1996; Miller *et al.*, 1998), the progressive neurodegeneration that follows may undercut or constrain the creative process. AA’s capacity for transmodal art peaked with ‘Unravelling Boléro’, painted 6 years before language deficits became apparent (Fig. 11). During this preclinical stage, AA retained the frontally mediated drive, generation and mental flexibility required to harness her newfound internal imagery. Next, just 2 years before PPA symptoms, AA’s art evolved from visual representations of auditory stimuli (‘Unravelling Boléro’) to visual representations of abstract concepts (‘pi’). Two years later, as language symptoms arose, AA’s art shifted toward high-fidelity visual reproductions of objects and scenes (‘Arbutus Leaves’ or ‘Amsterdam’). As modelled in Fig. 11, this later, more stimulus-driven painting style may have reflected a declining ability to

cross-link related perceptual images through posterior neocortical connections. Failure of these connections, in turn, may have resulted from infiltrating white matter tau pathology (Fig. 10). Primary and secondary visual areas, intact but isolated, could have provided a substrate for increasingly unimodal, symmetric and photographic art. At the time of her UCSF evaluation, AA was functionally mute, dysexecutive and perseverative, yet still producing works like ‘Amsterdam’ and ‘Ghent’ (Supplementary Fig. 2). Despite profound apparent deficits in verbal and visual fluency, AA’s drive to paint persisted for as long as her right hand could manipulate a brush.

Relationship between anterior vs. posterior and dominant vs. non-dominant cortices

In addition to its roles in language processing, the IFC is thought to exert supervisory control over attention, response selection and posterior sensory representations (Aron *et al.*, 2004; Konishi *et al.*, 2005; Matthews *et al.*, 2005).

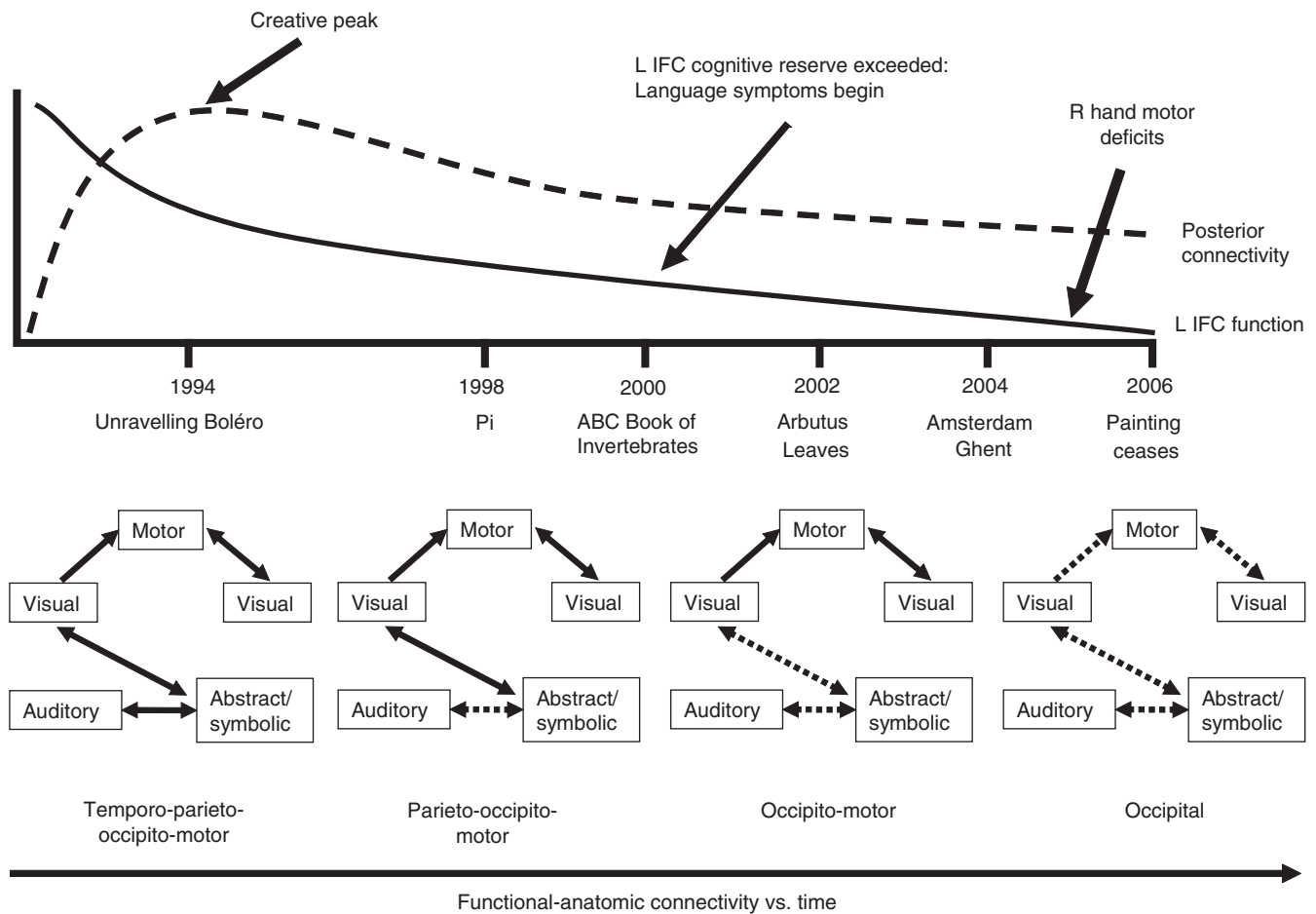


Fig. 11 Functional-anatomic model for AA’s artistic timeline. AA’s art peaked 6 years before overt PPA symptoms, at a time when incipient left IFC histopathology may have begun to accumulate. Heightened connectivity across multiple posterior cortices would have been required for ‘Unravelling Boléro’ and, to a lesser extent, for ‘Pi’, whereas AA’s later works emphasized visual imagery without representing other sensory or conceptual modalities. Progressive disconnection among posterior regions (dashed lines), owing to low-grade cortical or, more likely, extensive white matter tau pathology, may have contributed to the trends in AA’s art. Visual→Motor→Visual linkages refer to use of the motor system to translate an internal visual image into an external visual art form. L IFC = left inferior frontal cortex.

In 1986, Lhermitte described two left inferior frontal lesion patients with environmental dependency, a syndrome he hypothesized might result from liberation of parietal activity (Lhermitte, 1986). Environmentally dependent patients act on their surroundings as if driven by irrepresentable context- or stimulus-response linkages. Furthermore, whereas patients with non-dominant frontotemporal injury may become hypergraphic (Waxman and Geschwind, 1974; Mendez, 2005), those with dominant hemisphere disease are often drawn to visual form and objects (Edwards-Lee *et al.*, 1997; Seeley *et al.*, 2005). This visual interest can become all-consuming and at times manifest as emergent visual creativity (Miller *et al.*, 1996; Miller *et al.*, 1998). AA illustrates these principles in a new way. Her left fronto-insular degeneration was heralded by a blossoming of artistic potential and a penchant for transmodal imagery. ‘Liberated’ posterior regions showing structural and functional enhancements in AA are thought to support perceptual imagery, translation and integration. Only the right hemisphere showed evidence for enhancement. This asymmetry could result from direct effects of CBD on the left hemisphere; alternatively, the left and right hemispheres may maintain a balance in the healthy brain that was disrupted by AA’s left inferior frontal degeneration.

Functional-anatomic significance of AA’s thriving posterior brain regions

Regions showing structural and functional enhancements in AA have received previous attention for their roles in sensorimotor and audiovisual transmodal integration. The right IPS and SPL are heteromodal association areas that contribute to multiple aspects of visually guided cognition, including visuomotor search and attentional control (Corbetta *et al.*, 2002; Seeley *et al.*, 2007) as well as sensory transcoding, such as that required for music sight-reading (Sergent *et al.*, 1992; Schon *et al.*, 2002). A VBM study of professional musicians, amateurs and non-musicians showed a positive correlation between right superior parietal cortex volume and musical skill, suggesting that focal enhancements of this area may relate to innate musical predisposition or long-term practice (Gaser and Schlaug, 2003). An analogous study of visual artists has yet to be performed. AA’s enhanced right lateral occipital focus, adjacent to the transverse occipital sulcus, has likewise been associated with reading music (Nakada *et al.*, 1998; Schon *et al.*, 2002) and activates preferentially in response to symmetric *vs.* asymmetric visual pattern stimuli (Tyler *et al.*, 2005), perhaps explaining AA’s affinity for symmetric visual images. Finally, the STS is a polymodal area with robust connections to the lateral frontal lobe (Seltzer and Pandya, 1989) and helps to link arbitrary auditory-visual stimulus pairs (Calvert, 2001; Tanabe *et al.*, 2005). In monkeys, the IPS/SPL, STS and parieto-occipital area form a densely interconnected network in which the IPS

serves as a major hub (Cavada and Goldman-Rakic, 1989). We propose that enhanced structure, function and connectivity among these posterior regions helped AA derive new associations between auditory, visual, and conceptual representations. Fortunately, AA possessed the drive and latent potential required to turn mental images into paintings.

Limitations

Our findings do not definitively show when, why, or even if AA’s right posterior cortices changed during the course of her illness. Possibly, posterior functions were superior in AA at baseline. Alternatively, as has been shown in group analyses of hippocampal volume after intensive spatial learning (Maguire *et al.*, 2000), AA may have undergone a use-related expansion of posterior cortex in response to her practice of art. A third possibility, supported by the time course of her functional gains, is that early degeneration within AA’s left IFC disinhibited her right posterior cortices, causing her to experience a more vivid and connected perceptual world as her inner speech and other linguistic functions declined. These potential accounts are not mutually exclusive.

Relationship between AA and Ravel

In a twist of historical coincidence or disease-related convergence, AA was enchanted by Ravel’s ‘Boléro’, composed by a man with the same syndrome, PPA, and possibly the same underlying histopathology, CBD (Baeck, 1996; Amaducci *et al.*, 2002). AA’s interest in ‘Boléro’ arose before she developed overt PPA symptoms or learned of Ravel’s illness. Furthermore, AA painted ‘Unravelling Bolero’ at nearly the same age and disease stage that characterized Ravel when he wrote ‘Bolero’, suggesting that some patients with early PPA may be drawn to themes of repetition, texture and symmetry, perhaps because their thriving posterior cortices are increasingly tuned to these stimulus qualities. Whatever its basis, the relationship between AA and Ravel sheds new light on how neural systems interact to enhance the creative process.

Supplementary Materials

Supplementary materials are available at *Brain* online.

Acknowledgements

This study was funded by National Institutes of Health (P50 AG03006, P01 AG019724). We thank Drs Anne and Robert Adams for participating in dementia research and Robert Adams for his contributions to this manuscript.

References

- Alajouanine T. Aphasia and artistic realization. *Brain* 1948; 71: 229–41.
- Alonso RJ, Pascuzzi RM. Ravel’s neurological illness. *Semin Neurol* 1999; 19 (Suppl 1): 53–7.

- Amaducci L, Grassi E, Boller F. Maurice Ravel and right-hemisphere musical creativity: influence of disease on his last musical works? *Eur J Neurol* 2002; 9: 75–82.
- Aron AR, Robbins TW, Poldrack RA. Inhibition and the right inferior frontal cortex. *Trends Cogn Sci* 2004; 8: 170–7.
- Baek E. Was Maurice Ravel's illness a corticobasal degeneration? *Clin Neurol Neurosurg* 1996; 98: 57–61.
- Calvert GA. Crossmodal processing in the human brain: insights from functional neuroimaging studies. *Cereb Cortex* 2001; 11: 1110–23.
- Cardoso F. The movement disorder of Maurice Ravel. *Mov Disord* 2004; 19: 755–7.
- Cavada C, Goldman-Rakic PS. Posterior parietal cortex in rhesus monkey: I. Parcellation of areas based on distinctive limbic and sensory corticocortical connections. *J Comp Neurol* 1989; 287: 393–421.
- Chatterjee A. The neuropsychology of visual artistic production. *Neuropsychologia* 2004; 42: 1568–83.
- Corbetta M, Kincade JM, Shulman GL. Neural systems for visual orienting and their relationships to spatial working memory. *J Cogn Neurosci* 2002; 14: 508–23.
- Edwards-Lee T, Miller BL, Benson DF, Cummings JL, Russell GL, Boone K, et al. The temporal variant of frontotemporal dementia. *Brain* 1997; 120: 1027–40.
- Gaser C, Schlaug G. Brain structures differ between musicians and non-musicians. *J Neurosci* 2003; 23: 9240–5.
- Good CD, Johnsrude IS, Ashburner J, Henson RN, Friston KJ, Frackowiak RS. A voxel-based morphometric study of ageing in 465 normal adult human brains. *Neuroimage* 2001; 14: 21–36.
- Gorno-Tempini ML, Dronkers NF, Rankin KP, Ogar JM, Phengrasamy L, Rosen HJ, et al. Cognition and anatomy in three variants of primary progressive aphasia. *Ann Neurol* 2004a; 55: 335–46.
- Gorno-Tempini ML, Murray RC, Rankin KP, Weiner MW, Miller BL. Clinical, cognitive and anatomical evolution from nonfluent progressive aphasia to corticobasal syndrome: a case report. *Neurocase* 2004b; 10: 426–36.
- Grossman M. Drawing deficits in brain-damaged patients' freehand pictures. *Brain Cogn* 1988; 8: 189–205.
- Josephs KA, Duffy JR, Strand EA, Whitwell JL, Layton KF, Parisi JE, et al. Clinicopathological and imaging correlates of progressive aphasia and apraxia of speech. *Brain* 2006; 129: 1385–98.
- Kleiner-Fisman G, Black SE, Lang AE. Neurodegenerative disease and the evolution of art: the effects of presumed corticobasal degeneration in a professional artist. *Mov Disord* 2003; 18: 294–302.
- Knibb JA, Xuerab JH, Patterson K, Hodges JR. Clinical and pathological characterization of progressive aphasia. *Ann Neurol* 2006; 59: 156–65.
- Konishi S, Chikazoe J, Jimura K, Asari T, Miyashita Y. Neural mechanism in anterior prefrontal cortex for inhibition of prolonged set interference. *Proc Natl Acad Sci USA* 2005; 102: 12584–8.
- Lhermitte F. Human autonomy and the frontal lobes. Part II: patient behaviour in complex and social situations: the "environmental dependency syndrome". *Ann Neurol* 1986; 19R: 335–43.
- Maguire EA, Gadian DG, Johnsrude IS, Good CD, Ashburner J, Frackowiak RS, et al. Navigation-related structural change in the hippocampi of taxi drivers. *Proc Natl Acad Sci USA* 2000; 97: 4398–403.
- Matthews SC, Simmons AN, Arce E, Paulus MP. Dissociation of inhibition from error processing using a parametric inhibitory task during functional magnetic resonance imaging. *Neuroreport* 2005; 16: 755–60.
- Mendez MF. Hypergraphia for poetry in an epileptic patient. *J Neuropsychiatry Clin Neurosci* 2005; 17: 560–1.
- Mendez MF, Cherrier M, Perryman KM, Pachana N, Miller BL, Cummings JL. Frontotemporal dementia versus Alzheimer's disease: Differential cognitive features. *Neurology* 1996; 47: 1189–94.
- Mesulam MM. Slowly progressive aphasia without generalized dementia. *Ann Neurology* 1982; 11: 592–8.
- Mesulam MM. Primary progressive aphasia. *Ann Neurol* 2001; 49: 425–32.
- Miller BL, Boone K, Cummings JL, Read SL, Mishkin F. Functional correlates of musical and visual ability in frontotemporal dementia. *Br J Psychiatry* 2000; 176: 458–63.
- Miller BL, Cummings J, Mishkin F, Boone K, Prince F, Ponton M, et al. Emergence of artistic talent in frontotemporal dementia. *Neurology* 1998; 51: 978–82.
- Miller BL, Ponton M, Benson DF, Cummings JL, Mena I. Enhanced artistic creativity with temporal lobe degeneration. *Lancet* 1996; 348: 1744–5.
- Nakada T, Fujii Y, Suzuki K, Kwee IL. 'Musical brain' revealed by high-field (3 Tesla) functional MRI. *Neuroreport* 1998; 9: 3853–6.
- Post F. Creativity and psychopathology. A study of 291 world-famous men. *Br J Psychiatry* 1994; 165: 22–34.
- Sanchez-Valle R, Forman MS, Miller BL, Gorno-Tempini ML. From progressive nonfluent aphasia to corticobasal syndrome: a case report of corticobasal degeneration. *Neurocase* 2006; 12: 355–9.
- Schon D, Anton JL, Roth M, Besson M. An fMRI study of music sight-reading. *Neuroreport* 2002; 13: 2285–9.
- Seeley WW, Bauer AM, Miller BL, Gorno-Tempini ML, Kramer JH, Weiner M, et al. The natural history of temporal variant frontotemporal dementia. *Neurology* 2005; 64: 1384–90.
- Seeley WW, Menon V, Schatzberg AF, Keller J, Glover GH, Kenna H, et al. Dissociable intrinsic connectivity networks for salience processing and executive control. *J Neurosci* 2007; 27: 2349–56.
- Seltzer B, Pandya DN. Intrinsic connections and architectonics of the superior temporal sulcus in the rhesus monkey. *J Comp Neurol* 1989; 290: 451–71.
- Sergent J, Zuck E, Terriah S, MacDonald B. Distributed neural network underlying musical sight-reading and keyboard performance. *Science* 1992; 257: 106–9.
- Tanabe HC, Honda M, Sadato N. Functionally segregated neural substrates for arbitrary audiovisual paired-association learning. *J Neurosci* 2005; 25: 6409–18.
- Tyler CW, Baseler HA, Kontsevich LL, Likova LT, Wade AR, Wandell BA. Predominantly extra-retinotopic cortical response to pattern symmetry. *Neuroimage* 2005; 24: 306–14.
- Waxman SG, Geschwind N. Hypergraphia in temporal lobe epilepsy. *Neurology* 1974; 24: 629–36.