

Kaleidoscopic vision and a jerking leg on the ski slope

Stefan Kiechl, Martin Furtner, Michael Knoflach, Philipp Werner, Johann Willeit

Lancet 2007; 370: 1878

Department of Neurology,
Medical University Innsbruck,
Austria (S Kiechl MD,
M Furtner MD, M Knoflach MD,
P Werner MD, J Willeit MD)

Correspondence to:
Dr Stefan Kiechl, Department of
Neurology, Medical University
Innsbruck, Anichstraße 35,
A-6020 Innsbruck, Austria
stefan.kiechl@i-med.ac.at

In March, 2005, a 48-year-old woman was flown to our hospital by rescue helicopter after she fell while skiing. Shortly before she fell, she started to see objects in a distorted or fragmented way, and to see geometric shapes. The images of the objects and shapes were constantly changing, and she described her experience as like “looking through a kaleidoscope”. She closed her eyes in turn: vision in her right eye was normal; vision in her left eye was monochrome, fragmented, and changing. Her right leg started to jerk briskly and irregularly, causing her to fall. She did not lose consciousness; nor was she hurt. She had had migraine attacks, without an aura, for more than 30 years, but had had no attacks for several weeks. She had no risk factors for epilepsy. Nonetheless, the emergency physicians provisionally diagnosed a partial seizure.

The patient was right-handed. Blood pressure was normal, at 140/90 mm Hg, as was visual acuity. However, on standing, the patient had vertigo; within seconds, her right arm and leg started to jerk repeatedly. The jerking promptly ceased when she lay down. Fundoscopy and gazing into the sun caused her vision to be as though of a picture with poor resolution, or one consisting of fine granules; she would then go blind in her left eye. Vision returned to normal once the patient stopped gazing at bright lights. MRI, magnetic-resonance angiography (MRA), and high-resolution ultrasonography revealed a high-grade (>90%) stenosis of the left carotid artery, caused by dissection of the artery wall (figure). Ultrasonography also showed significant impairment of blood flow in the left middle cerebral artery, with a loss of autoregulation. There was evidence of collateral blood supply via the

ophthalmic artery, leptomeningeal pathways, and anterior and posterior communicating arteries. The patient was given a plasma expander (hydroxyethyl starch) and norepinephrine to raise her mean arterial pressure above 100 mm Hg, and heparin to reduce the risk of clotting. She was also told to remain lying in bed, and to wear sunglasses. Her symptoms resolved within 48 h, but recurred 4 days after admission; additionally, she now had brief episodes of aphasia and right-sided hemiparesis. Repeat MRI and MRA showed that the wall haematoma had expanded, so the left carotid artery was now blocked. MRI also showed two pinhead-sized diffusion abnormalities, implying small strokes, in the left frontal lobe. Transcranial duplex ultrasonography showed that mean flow velocity in the left middle cerebral artery was now just 60% of the velocity on the right. We considered placing a stent in the carotid artery; however, the patient's condition rapidly improved, through an increase in collateral blood flow. 10 days after admission, treatment with hydroxyethyl starch and norepinephrine was discontinued; 4 days later, heparin was replaced by warfarin, which we prescribed for 12 months. On further assessment, we found no evidence of fibromuscular dysplasia, polycystic kidney disease, Ehlers-Danlos syndrome, or Marfan's syndrome, all illnesses associated with arterial dissection. When last seen, in March, 2006, the patient was well.

Although the unilateral limb jerks seemed to signify epilepsy, the postural onset of clinical signs indicated that the illness was probably vascular. Low-flow transient ischaemic attacks (TIAs) can cause limbs to swing, jerk, or tremble.¹ Such movements are nearly always unilateral; the face is generally unaffected.¹ These attacks are ascribed to a focal low-perfusion state in the carotid artery territory, and loss of autoregulation.^{1,2} Similarly, our patient's visual symptoms were caused by a vascular mechanism. Retinal ischaemia delayed regeneration of visual pigments, leading to kaleidoscopic vision and blindness. Transient painless amaurosis precipitated by exposure to bright light is known as retinal claudication.^{3,4} Retinal claudication and TIAs with limb-shaking are thought to occur in 3% and 8%, respectively, of patients with carotid artery occlusion.⁵

References

- 1 Baquis GD, Pessin MS, Scott RM. Limb shaking—a carotid TIA. *Stroke* 1985; **16**: 444–48.
- 2 Fisher CM. Concerning recurrent transient cerebral ischemic attacks. *Can Med Assoc J* 1962; **86**: 1091–99.
- 3 Furlan AJ, Whisnant JP, Kearns TP. Unilateral visual loss in bright light. An unusual symptom of carotid artery occlusive disease. *Arch Neurol* 1979; **36**: 675–76.
- 4 Kaiboriboon K, Piriyaawat P, Selhorst JB. Light-induced amaurosis fugax. *Am J Ophthalmol* 2001; **131**: 674–76.
- 5 Klijn CJ, Kappelle LJ, van Huffelen AC, et al. Recurrent ischemia in symptomatic carotid occlusion: prognostic value of hemodynamic factors. *Neurology* 2000; **55**: 1806–12.

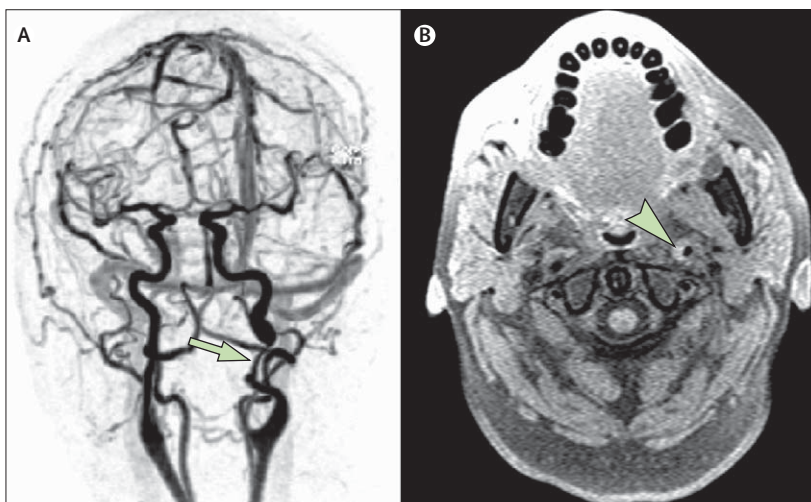


Figure: Carotid artery dissection
(A) MRA, showing a string-like stenosis caused by dissection of the left internal carotid artery (arrow). (B) MRI with T1 weighting, showing a semilunar area of hyperintensity, typical of haematoma, in the artery wall (arrowhead).