

Are your MRI contrast agents cost-effective?

Learn more about generic Gadolinium-Based Contrast Agents.



AJNR

**Cortical Blindness, Transient and Otherwise,
Associated with Detachable Coil
Embolization of Intracranial Aneurysms**

Y. Niimi, M.J. Kupersmith, S. Ahmad, J. Song and A. Berenstein

This information is current as
of April 12, 2024.

AJNR Am J Neuroradiol 2008, 29 (3) 603-607

doi: <https://doi.org/10.3174/ajnr.A0858>

<http://www.ajnr.org/content/29/3/603>

ORIGINAL
RESEARCH

Y. Niimi
M.J. Kupersmith
S. Ahmad
J. Song
A. Berenstein

Cortical Blindness, Transient and Otherwise, Associated with Detachable Coil Embolization of Intracranial Aneurysms

BACKGROUND AND PURPOSE: Cortical visual loss is a rare complication of cerebral angiography without a definitive pathophysiology. Given the rapid increase in endovascular procedures used to treat cerebral aneurysms, we explored the prevalence of this complication and whether we could add to the understanding of this disorder.

MATERIALS AND METHODS: We performed a retrospective review of all procedures performed with the same contrast agent and detachable coils for treatment of posterior circulation aneurysms by 1 endovascular surgery service from 1996 to 2006. All patients were evaluated before and after each procedure by a team that included a neuro-ophthalmologist.

RESULTS: Of 137 intra-arterial treatment procedures performed for posterior circulation aneurysms, we identified 4 patients with cerebral vision loss complications. During the same time period, >500 aneurysms of the anterior cerebral circulation were treated without this complication. The visual field loss was unilateral in 2 and bilateral in 2 patients. Recovery was complete in 3 and almost normal in the fourth patient. The amount of contrast used and the duration of the procedure were similar among all patients. The 4 patients had no identified specific risk factors for developing procedure-associated occipital dysfunction, all 4 had undergone prior angiography, and 1 patient had undergone repeat coiling, without complication.

CONCLUSION: The 2.9% prevalence of cerebral visual loss with endovascular coil treatment of posterior circulation aneurysms is higher than that for angiography alone. Our patients recovered well with corticosteroid and intravenous hydration treatment. Recognizing the self-limiting nature of this problem might prevent an unneeded intervention.

Endosaccular occlusion procedures with detachable coils are used with increasing frequency in the treatment of intracranial aneurysms because of clinical effectiveness, good clinical outcome, and low complication rates.^{1,2} Endovascular procedures necessitate repeated intra-arterial contrast injections to evaluate therapeutic progress and to avoid or reverse complications such as emboli or unplanned arterial occlusion. Transient cortical blindness is a rare but known complication after administration of angiographic contrast agent,³ which has been reported in 0.3%–1% of patients undergoing vertebral angiography.^{4,5} The prevalence could be higher in patients with vasculopathy, even with carotid artery injections,⁶ or with older techniques.^{7,8} The exact mechanism for this problem has not been proved. We encountered this complication in 4 patients who had endovascular treatment of posterior circulation aneurysms, which has been reported twice.^{9,10}

Methods and Patients

We performed a retrospective review of the data base of all patients undergoing endovascular treatment for posterior circulation intracranial aneurysms to identify those patients diagnosed with cortical blindness after endovascular embolization. All patients were treated by 1 endovascular service during the 10 years from October 1996

through July 2006. All endovascular procedures were performed by experienced interventional neuroradiologists, and all patients were evaluated before and after therapy by a single neurologist/neuro-ophthalmologist. The technique applied in the endovascular treatment of these intracranial aneurysms was similar to that published before.^{2,11} The procedures were performed with the patients under general anesthesia, and systemic heparinization was provided throughout. Arteriography was performed by using full-strength (300 mg I/mL) or half-strength iopromide, a nonionic water-soluble contrast agent. The amount of contrast agent injected into the posterior circulation and the time between the first and the last posterior circulation injection were analyzed. With high-resolution digital fluoroscopy and road-mapping, a 2–3F microcatheter was positioned in the sac of the aneurysm. Detachable coils were delivered sequentially and deployed into the aneurysm until tight coil packing was achieved. Immediate postembolization angiography in multiple projections was performed and evaluated by the interventional neuroradiologist to ensure that there were no angiographic signs of distal embolizations as well to document the status of the aneurysm closure.

Results

We identified 117 patients who had undergone 137 endovascular procedures for 140 posterior circulation aneurysms. We excluded patients (none of whom had cortical blindness) with incomplete data, a concomitant brain or dural arteriovenous malformation, or an anterior circulation aneurysm treated at the same time as the posterior circulation aneurysm or if the aneurysm was treated by parent artery occlusion. There was no development of cortical blindness by the endovascular treatment of >500 anterior circulation aneurysms during this period. There were 86 basilar apex aneurysms, 17 basilar trunk,

Received July 27, 2007; accepted September 4.

From the Departments of Neuro-Ophthalmology and Endovascular Surgery, Hyman Newman Institute of Neurology and Neurosurgery, Roosevelt Hospital Center, New York; and Albert Einstein School of Medicine, New York.

Please address correspondence to Mark J. Kupersmith, MD, Division of Neuro-Ophthalmology, Roosevelt Hospital, 1000 10th Ave, 10th Floor, INN, New York, NY 10019; e-mail: mkuper@chpnet.org

DOI 10.3174/ajnr.A0858

10 posterior cerebral artery, 13 posterior inferior cerebellar artery, 12 superior cerebellar artery aneurysms, 1 vertebral artery aneurysm, and 1 anterior inferior cerebellar artery aneurysm. Two posterior circulation aneurysms were treated at the same time in 3 patients. Ninety-five aneurysms were small, <10 mm, and 45 aneurysms were larger. The average aneurysm size was 8.8 mm (SD, 3.9). Thirteen patients had 2, 1 had 3, and 2 had 4 treatments, mostly for the same aneurysm. Twenty-nine procedures were performed with balloon or stent assistance.

For the 137 procedures, the volume of nonionic 300-mg I/mL contrast injected into the posterior circulation was 61–600 mL (average, 257 mL with an SD of 109 mL) during 1–6.3 hours (average, 2.8 hours with an SD of 1.1 hours). Contrast injection into the posterior circulation per hour ranged from 24.4 to 240 mL/h (average, 94.4 mL/h; SD, 30.9 mL/h).

Four patients developed cerebral visual deficits after coil embolization. There were 3 men and 1 woman with ages ranging from 41 to 54 years (mean, 46 years). Three patients had a basilar apex aneurysm, and 1 had a superior cerebellar aneurysm. The size of the 4 aneurysms ranged from 6 to 18 mm, with a mean of 12.1 mm, which, in 3 patients, was larger than the average size of the whole series. Two patients had a history of hypertension, and 1 patient had a history of diabetes. None had fluid or electrolyte problems, and only 1 patient had a recent subarachnoid hemorrhage. Three patients underwent coiling of the aneurysm with balloon- or stent-assisted technique, 1 of whom had 3 previous coiling treatments for the same aneurysm, including 1 balloon-assisted technique, without causing cortical blindness. The other patient who developed cortical blindness without balloon- or stent-assisted coiling subsequently underwent a second procedure without development of cortical blindness.

For these 4 patients, 62–384 mL (mean, 242 mL; SD, 136.5 mL) of 300-mg I/mL contrast agent was injected during 2.5–5.2 hours (mean, 3.4 hours; SD, 1.2 hours). Injected contrast volume per hour ranged from 24.8 to 142.2 mL/h (mean, 75.1 mL/h). The volume and duration of contrast injection were not significantly different from the amounts in the whole series. All 4 patients developed visual deficits within several hours to 1 day after the procedure. Two patients developed a right homonymous hemianopia, and 2 patients had bilateral field deficits and central vision loss. Angiography showed evidence of transient vasospastic/occlusive or embolic process in 1 patient (case 2). Visual field deficits resolved completely in 3 patients within 1 month and incompletely, but significantly, in 1 patient.

Case Reports

Case 1. A 41-year-old man with a left superior cerebellar artery aneurysm (with 2 remote subarachnoid hemorrhages), which recurred after 3 prior coil embolizations (1 with balloon-assisted technique) and coil compaction, underwent an embolization procedure of an 18 × 18 × 18 mm aneurysm with a 6-mm neck. During the previous 3 coiling procedures, 61–360 mL of nonionic contrast material was injected into the posterior circulation during 1.5–2.5 hours (rate, 24.4–240 mL/h) without development of visual field deficits. The fourth coiling procedure was performed with a balloon-assisted technique, by using a total of 297 mL of nonionic contrast material

(300 mgI/mL) injected into the posterior arterial circulation for 3.3 hours. Six detachable coils with a total length of 99 cm were deployed, and there were no artery occlusions on the postprocedural control angiogram. The patient was neurologically unchanged immediately following the procedure, but within 3 hours of awakening from general anesthesia, the patient noted acute bilateral loss of vision, having only light perception or hand-motion detection in both eyes. He was agitated but had normal pupils and ophthalmoscopy findings and no other neurologic signs or symptoms. Emergent non-contrast CT of the brain showed a small old low-attenuation area in the right parietal region with normal occipital lobes. Due to a previously placed ferromagnetic clip, an MR imaging was not performed. A cerebral angiogram, performed the next day, showed no evidence of vessel occlusion or emboli in the posterior cerebral arteries. The patient was treated with the postcoiling regimen typically used during that time period: dexamethasone, 4 mg every 8 hours, tapered for several days; intravenous heparin for 72 hours; and intravenous fluid to maintain normal blood pressure. He regained vision in 3 days with an incomplete homonymous hemianopia, and by 1 month, the visual acuity was 20/20 in each eye with mild left partial homonymous hemianopia worse inferiorly, which was minimally abnormal (Fig 1A, -B).

Case 2. A 46-year-old man, who was neurologically normal with a strabismic amblyopic left eye, in the evaluation of non-specific head and neck pain was found to have a 14 × 11 × 11 mm basilar apex aneurysm with an 8-mm neck and an 8-mm left terminal internal carotid artery aneurysm. The basilar aneurysm was treated with balloon remodeling-assisted endovascular embolization, and a total of 225 mL of 300-mg I/mL nonionic contrast was injected for 5.2 hours into the posterior arterial circulation. Ten detachable coils, including HydroCoils (MicroVention, Aliso Viejo, Calif) with a total length of 180 cm, were deployed with slight herniation of a coil into the P1 segment causing temporary occlusion of the left posterior cerebral and superior cerebellar arteries. In addition, several small distal posterior cerebral arteries appeared occluded, but all of these arteries were quickly opened following 2 mg of intra-arterial abciximab (ReoPro). A Neuroform stent (Boston Scientific, Natick, Mass) was placed across the neck in the P1 segment to secure the coils. The control angiogram showed no occluded vessels at the end of the procedure. The patient was neurologically intact, and the visual fields were unchanged immediately following the procedure. Approximately 1 hour later, the patient developed an attenuated right homonymous hemianopia by confrontation testing. Emergent noncontrast CT of the brain did not reveal intraparenchymal pathology. A cerebral angiography was performed to determine patency of the relevant arterial system, and both posterior cerebral artery territories filled with no obvious branch occlusions. Although there were no occluded arteries seen, 3 mg of intra-arterial ReoPro was injected into the posterior circulation. The patient was treated with dexamethasone, 4 mg every 8 hours, which was tapered during several days; intravenous fluids to maintain normal blood pressure; and intravenous heparin for 72 hours. He improved during the next 4 days with return to a normal visual field within 1 month. An unenhanced MR imaging study 11 days later, including diffusion images, did not show any abnormal signals.

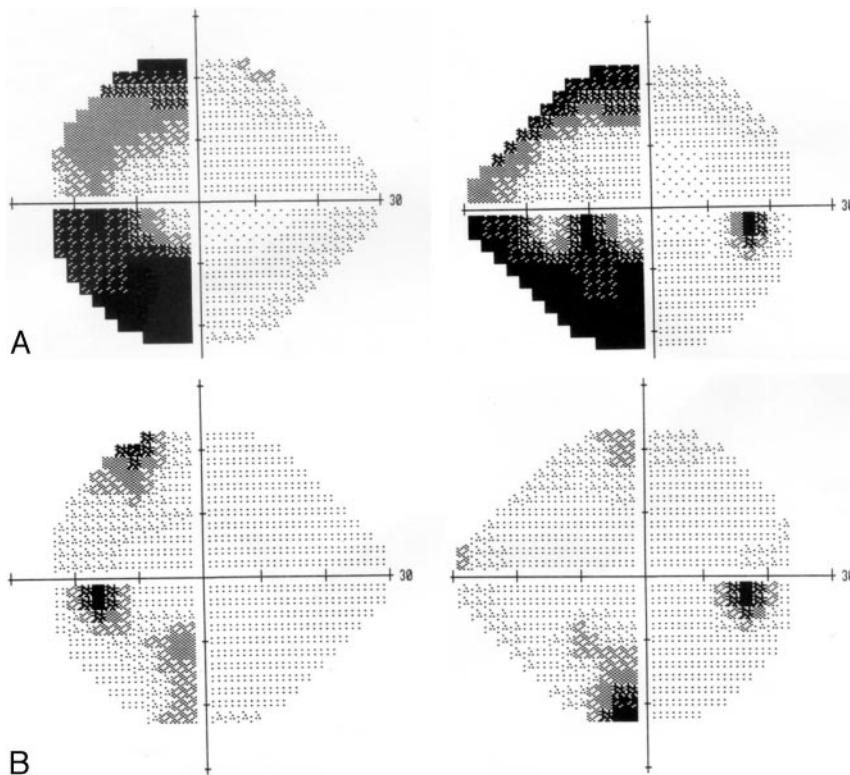


Fig 1. A, One week after cortical blindness, partial left homonymous visual field defect is seen. B, Minimal left homonymous visual field depression 4 years later.

Case 3. A 54-year-old woman had a 2-mm basilar apex aneurysm discovered after a subarachnoid hemorrhage. The patient was followed without treatment directed at the aneurysm, but repeat MR imaging/MR angiography 8 years later revealed an increasing size of the aneurysm. The patient, who was neurologically intact, underwent endovascular embolization of a $6 \times 5 \times 4$ mm basilar apex aneurysm with a 5-mm-wide neck, with a total of 62-mL of 300-mg I/mL nonionic contrast material injected for 2.5 hours into the posterior circulation. There were no anterior cerebral injections during this procedure (a prior planning angiogram had been obtained). Seven detachable coils with a total length of 63 cm were deployed with 2 stents from the basilar tip to each posterior cerebral artery, and there were no arterial occlusions on the postprocedural control angiogram (Fig 2). The patient was neurologically intact immediately following the procedure. Approximately 3 hours afterward, she noted severe vision loss to light perception in each eye, with normal pupillary responses to light and otherwise normal findings on neurologic examination. A brain MR imaging, performed the next day showed a subtle signal-intensity abnormality in the bilateral medial occipital lobes in the fluid-attenuation inversion recovery sequence (Fig 3A, -B), which normalized in 1 month. She developed left flank pain and azotemia 1 day later due to a renal capsular hemorrhage followed the next day by sepsis. Treatment included dexamethasone, 6 mg every 8 hours, fluid management, gentamycin and vancomycin, and cessation of heparin. The patient gradually improved 5 days later (Fig 4A) and had normal findings, including by threshold perimetry, 1 month postprocedure (Fig 4B).

Case 4. A 47-year-old man, who presented with a diffuse subarachnoid hemorrhage, was found to have a basilar apex aneurysm. The patient had been awake, alert, and following

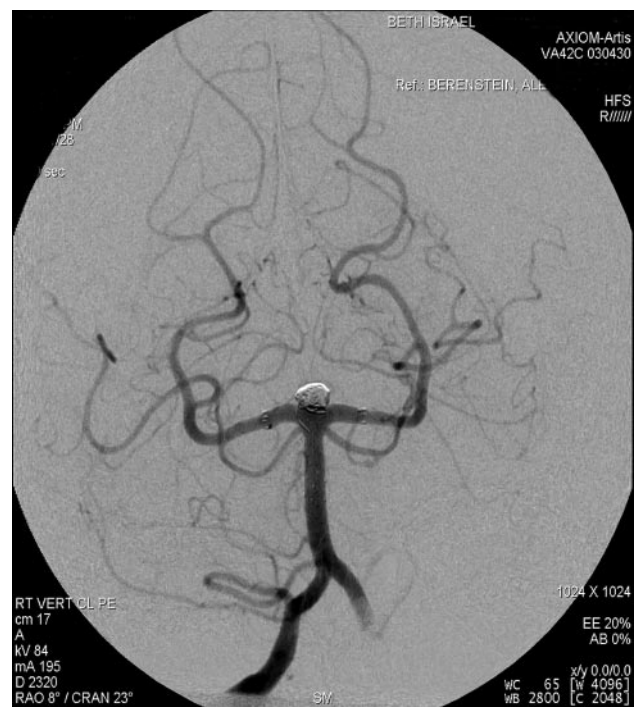


Fig 2. Anteroposterior vertebral artery injection showing a basilar aneurysm with coils and no posterior cerebral artery spasm or occlusion.

commands with mild confusion and recent memory difficulties as his only neurologic dysfunction before the procedure. The day after the bleed, he underwent endovascular embolization of the $9.5 \times 10.5 \times 8$ mm basilar apex aneurysm with a 5-mm-wide neck. A total of 384 mL of 300-mg I/mL nonionic contrast material was injected into the posterior circulation for 2.7 hours. Twelve detachable coils with a total length of 124

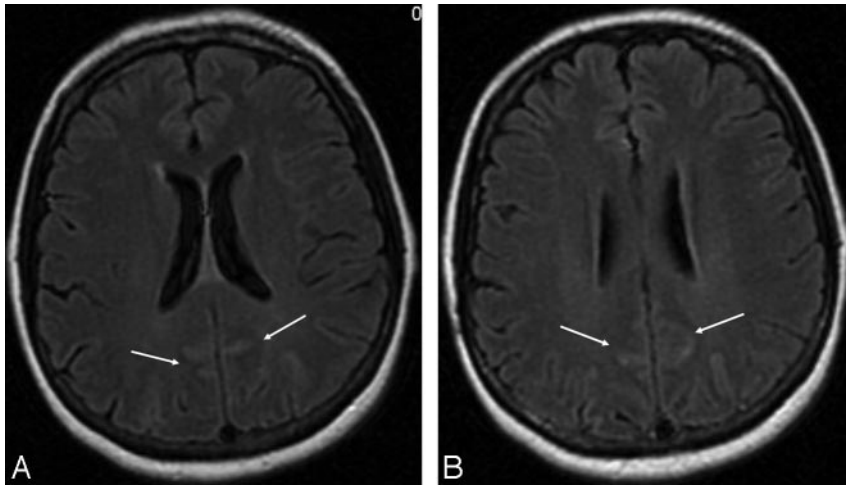


Fig 3. Transaxial MR imaging fluid-attenuation recovery sequences show bilateral medial occipital cortical abnormal bright signal intensity (arrows).

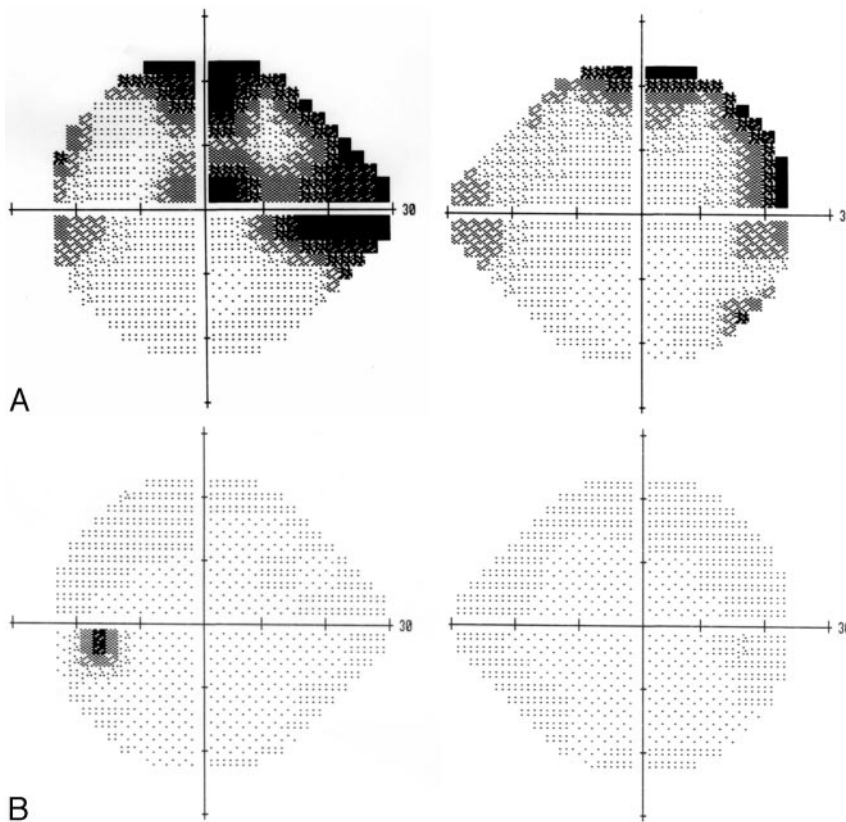


Fig 4. A, Five days after cortical blindness, visual field loss in the left more than right in eye in a nonspecific pattern is seen. B, One month later, the visual fields are normal.

cm, including HydroCoils, were deployed. There were no occluded arteries on the postprocedure control angiogram. The patient was neurologically unchanged immediately following the procedure. On postoperative day 1, the patient had the same preprocedural mental status, but he had a new attenuated right homonymous hemianopia found by confrontation testing. Findings of an emergent noncontrast CT scan of the brain as well as a follow-up study 2 days later were normal. The vision normalized during 1 week. He underwent recoiling of the same aneurysm due to recanalization 22 months later without development of visual loss. At this time, 89 mL of 300-mg I/mL nonionic contrast material was injected into the posterior circulation for 1.7 hours.

Discussion

Occipital dysfunction with vision loss occurred in 4 of 137 (2.9%) intra-arterial coiling procedures, a higher rate than the reported 1% or less for vertebral angiography.^{4,5} There was no clear correlation with the amount or infusion rate of contrast injected or with the duration of the intra-arterial procedure. Prior and subsequent angiograms and procedures did not cause the same complication in our 4 patients. Except for intra-arterial injection of a thrombolytic agent in case 2, the vision recovered without deviation from the protocol in use following endovascular treatment of intracranial aneurysms. Clinically, our cases differed from some prior reported cases because our patients had no other neurologic dysfunction or seizures.^{6,12} In the 3 patients who had CT scanning, none

showed contrast enhancement from the agent used during angiography,^{9,12} perhaps because the patients developed or were first noticed to have poor vision hours after the procedure when they woke up from the anesthesia.

Transient cortical blindness secondary to administration of a nonionic low-osmolar contrast agent is a rare complication, which has been reported after catheter cerebral angiography but has also been reported with intravenous contrast injections for CT in the presence of cerebral metastatic lesions.¹³ Most of the contrast agents have an osmolality range of 1.2–1.8 osmol, compared with 0.3 osmol for normal blood, which may open the normal endothelial cell tight junctions of the blood-brain barrier.^{14,15} This could be a possible mechanism if a patient was dehydrated but did not appear to occur in our 4 patients. Studies suggest that contrast media penetrates the blood-brain barrier as a function of dosage, contact time, concentration of anions in the material, and lipophilic characteristics. The clinical dysfunction occurs predominantly, but not exclusively, in the occipital area, which is responsible for the resultant cortical blindness.

Prolonged exposure to the contrast through repeated injections has been hypothesized, but not proved,¹⁶ to cause neuro or glial toxicity or depolarization, without disrupting the barrier if the contrast is transported across by virtue of its lipid solubility, or if local hyperosmolality opens tight junctions.¹³ Particularly if the posterior communicating arteries (PcomA) are hypoplastic or absent, the occipital lobes maybe more susceptible because the vast amount of contrast injected into the vertebral arterial system will end up in the posterior cerebral arteries. In fact, cases 1 and 4 had no PcomAs, case 2 had 1 very small PcomA, and case 3 had bilateral small PcomAs. This could result in the contrast perfusing a relatively small volume of brain tissue and not diffusing to wider areas of the brain as occurs with carotid angiography. The occipital lobes also appear more prone to transient disturbances such as migraine or spreading depression than other cerebral areas.¹⁷ Last, with high-resolution angiography, emboli (either blood or microcrystals from contrast) or vasospasm not seen with other methods is often demonstrated without obvious occlusions, and our patients, particularly case 2, might have had ischemia or blood-brain barrier disruption from microemboli, which increased the susceptibility to contrast toxicity.

This complication is a self-limited process. It is characterized by a decrease in vision with unilateral or bilateral visual field deficits and normal pupillary reaction to light and ophthalmoscopy. Most cases resolve within hours to days. Although cortical blindness has been principally described with posterior circulation angiography, cases have been reported with anterior cerebral circulation angiography¹⁰ and even with coronary angiography.¹⁸ Although no therapy has proved to be effective, some have advocated the use of aggressive intravenous hydration with a short course of corticosteroids,^{6,9} which is similar to the postcoiling regimen used in our service. The rationale for the use of steroids is stabilization of the blood-brain barrier, which could reduce the theoretic vasogenic edema.¹⁹ The prognosis is favorable, with rapid recovery

in most cases. However, this complication must be differentiated from an embolic or vaso-occlusive phenomenon, which may have a similar presentation but might require thrombolysis or thrombectomy.

Conclusion

Our patients in this series recovered well with corticosteroid and intravenous hydration treatment. The uncommon nature of this complication limits our ability to draw firm conclusions about the pathologic mechanism. When faced with such a case, it is essential to have a posttreatment angiogram that shows no arterial branch occlusions and an MR image or CT scan that shows no acute infarct. These can be used to avoid therapies that will not alter the eventual outcome and may have significant risk.

References

1. Gonzalez N, Murayama Y, Nien YL, et al. **Treatment of unruptured aneurysms with GDCs: clinical experience with 247 aneurysms.** *AJNR Am J Neuroradiol* 2004;25:577–83
2. Molyneux A, Kerr R, Yu LM, et al. **International subarachnoid aneurysm trial (ICAT) of neurosurgical clipping versus endovascular coiling in 2143 patients with ruptured intracranial aneurysms: a randomised comparison of effects on survival, dependency, seizures, rebleeding, subgroups, and aneurysm occlusion.** *Lancet* 2005;366:809–17
3. Horwitz NH, Wener L. **Temporary cortical blindness following angiography.** *J Neurosurg* 1974;40:583–86
4. Wishart DL. **Complications in vertebral angiography as compared to nonvertebral cerebral angiography in 447 studies.** *AJNR Am J Neuroradiol* 1971;113:527–37
5. Mani R, Eisenberg R. **Complications of catheter cerebral arteriography: analysis of 5,000 procedures. III. Assessment of arteries injected, contrast medium used, duration of procedures, and age of patient.** *AJR Am J Roentgenol* 1978;131:871–74
6. Lantos G. **Cortical blindness due to osmotic disruption of the blood-brain barrier by angiographic contrast material: CT and MRI studies.** *Neurology* 1989;39:567–71
7. Aasved H. **Visual disturbances following intracranial angiography.** *Acta Ophthalmol (Copenh)* 1962;40:297–302
8. Silverman S, Berman P, Bender M. **The dynamics of transient cortical blindness: report of nine episodes following vertebral angiography.** *Arch Neurol* 1961;4:333–48
9. Shinoda J, Ajimi Y, Yamada M, et al. **Cortical blindness during coil embolization of an unruptured intracranial aneurysm: case report.** *Neurol Med Chir (Tokyo)* 2004;44:416–19
10. Saigal G, Bhatia R, Bhatia S, et al. **MR findings of cortical blindness following angiography: is this entity related to posterior reversible leukoencephalopathy?** *AJNR Am J Neuroradiol* 2004;25:252–56
11. Viñuela F, Duckwiler G, Mawad M. **Guglielmi detachable coil embolization of acute intracranial aneurysm: perioperative anatomical and clinical outcome in 403 patients.** *J Neurosurg* 1997;86:475–82
12. Studdard WE, Davis DO, Young SW. **Cortical blindness after cerebral angiography: case report.** *J Neurosurg* 1981;54:240–44
13. Lalli AF. **Contrast media reactions: data analysis and hypothesis.** *Radiology* 1980;134:1–12
14. Rapoport S, Levitan H. **Neurotoxicity of x-ray contrast media: relation to lipid solubility and blood-brain barrier permeability.** *Am J Roentgenol Radium Ther Nucl Med* 1974;122:186–93
15. Grainger R. **Osmolality of intravascular radiological contrast media.** *Br J Radiol* 1980;53:739–46
16. Utz R, Ekholm S, Isaac L, et al. **Local blood-brain barrier penetration following systemic contrast medium administration: a case report and an experimental study.** *Acta Radiol* 1988;29:237–42
17. Kupersmith M. *Neurovascular Neuro-Ophthalmology.* Heidelberg, Germany: Springer-Verlag; 1993:441–65
18. Sculte-Alterdonreuberg G, Rub K, Scheglman K. **Simultaneous ischemic and neurotoxic brain damage after coronary angiography.** *Neurology Res* 2004;26:79–82
19. Fishman RA. **Brain edema.** *N Engl J Med* 1975;273:706–11