

# Assessment of Intra-arterial Injected Autologous Bone Marrow Mononuclear Cell Distribution by Radioactive Labeling in Acute Ischemic Stroke

Patricia Lavatori Correa, MD, MSc,\* Claudio T. Mesquita, MD, MSc, PhD,\*  
 Renata M. Felix, MD, MSc,\* Jader C. Azevedo, MD, MSc,\* Gustavo B. Barbirato, MD,\*  
 Carlos Henrique Falcão, MD,\* Constantino Gonzalez, MD,\* Maria Lucia Mendonça, MD,\*  
 Aquiles Manfrim, MD,\* Gabriel de Freitas, MD,† Cristina C. Oliveira, BSc,\* Daniel Silva, BSc,\*  
 Dione Ávila, RN,\* Radovan Borojevic, PhD,‡ Suzana Alves, MD,‡ Amarino C. Oliveira, Jr., MD,\*  
 and Hans F. Dohmann, MD,‡

**Objective:** To evaluate the feasibility of monitoring the autologous mononuclear bone marrow (ABMMN) cells implanted into the brain after acute ischemic stroke by the technique of labeling with Tc-99m-HMPAO.

**Case Report:** A 37-year-old man presented with aphasia, right-side hypoesthesia, and right homonymous hemianopsia after an acute ischemic stroke of the left middle cerebral artery. He was included in an autologous bone marrow mononuclear cell-based therapy research protocol about the safety of intra-arterial autologous bone marrow mononuclear cell transplantation for acute ischemic stroke. Nine days after the stroke he received  $3.0 \times 10^7$  ABMMN cells delivered into the left cerebral middle artery via a balloon catheter. Approximately 1% of these cells were labeled with 150 MBq (4 mCi) Tc-99m by incubation with hexamethylpropylene amine oxime (HMPAO).

**Results:** Brain perfusion images with Tc-99m ECD demonstrated hypoperfusion in the left temporal and parietal regions. The perfusion brain images were compared with tomographic views of the brain obtained 8 hours after ABMMN-labeled cell delivery, revealing intense accumulation of the ABMMN-labeled cells in the ipsilateral hemisphere. A whole-body scan was done and showed left brain, liver, and spleen uptake.

**Conclusions:** Our results showed that Tc-99m HMPAO can be used to label ABMMN cells for in vivo cell visualization, and that brain SPECT imaging with labeled ABMMN cells is a feasible noninvasive method for studying the fate of transplanted cells in vivo.

Additionally, our findings demonstrate the localization of these intra-arterially injected cells.

**Key Words:** labeled cells, stroke, cell therapy, brain

(*Clin Nucl Med* 2007;32: 839–841)

Ischemic stroke causes locally restricted loss of neuronal circuitry and supporting glial cells with functional deficits and disabilities.<sup>1</sup> Stem cell transplantation has emerged as a potential therapy for the penumbra zone in ischemic stroke. They may possess the potential of providing trophic support for cell survival, tissue repair, and functional recovery.<sup>2</sup> The ability to track stem cell transplants in the brain by in vivo neuroimaging may be valuable in assessing the ability of these cells to engraft the damaged tissue, and aid our understanding of how these cells may mediate functional recovery after transplantation. Some investigators have used Tc-99m HMPAO modified techniques to label bone marrow mononuclear cells and track them in vivo. Despite a predilection for granulocytes, this radiotracer can also label mononuclear cells and allows technically adequate imaging.<sup>3,4</sup>

We evaluated the feasibility of monitoring ABMMN cells implanted into the brain after acute ischemic stroke by brain scintigraphy with ABMMN labeled with Tc-99m HMPAO. We report the results of a patient studied by this technique, who was recruited for a clinical trial about safety of intra-arterial autologous bone marrow mononuclear cell transplantation for acute ischemic stroke<sup>5</sup> approved by the National Ethical Committee (CONEP 9396).

## CASE REPORT

A 37-year-old man was suddenly afflicted by difficulty in speaking and confusion. He had no history of hypertension, diabetes, or other risk factors for vascular disease. Neurologic examination on admission showed aphasia and apraxia, right-sided hypoesthesia, and right homonymous

Received for publication June 23, 2006; revision accepted February 14, 2007.

From the \*Hospital Procardiaco, †Universidade Federal do Rio de Janeiro; ‡Procep, Rio de Janeiro, Brazil.

Institution where work was performed: Hospital Procardiaco and Universidade Federal do Rio de Janeiro.

Reprints: Patricia Lavatori Corrêa, Rua General Polidoro 192 Botafogo, CEP 22280000, Rio de Janeiro, RJ, Brasil. E-mail: medicina.nuclear@procardiaco.com.br.

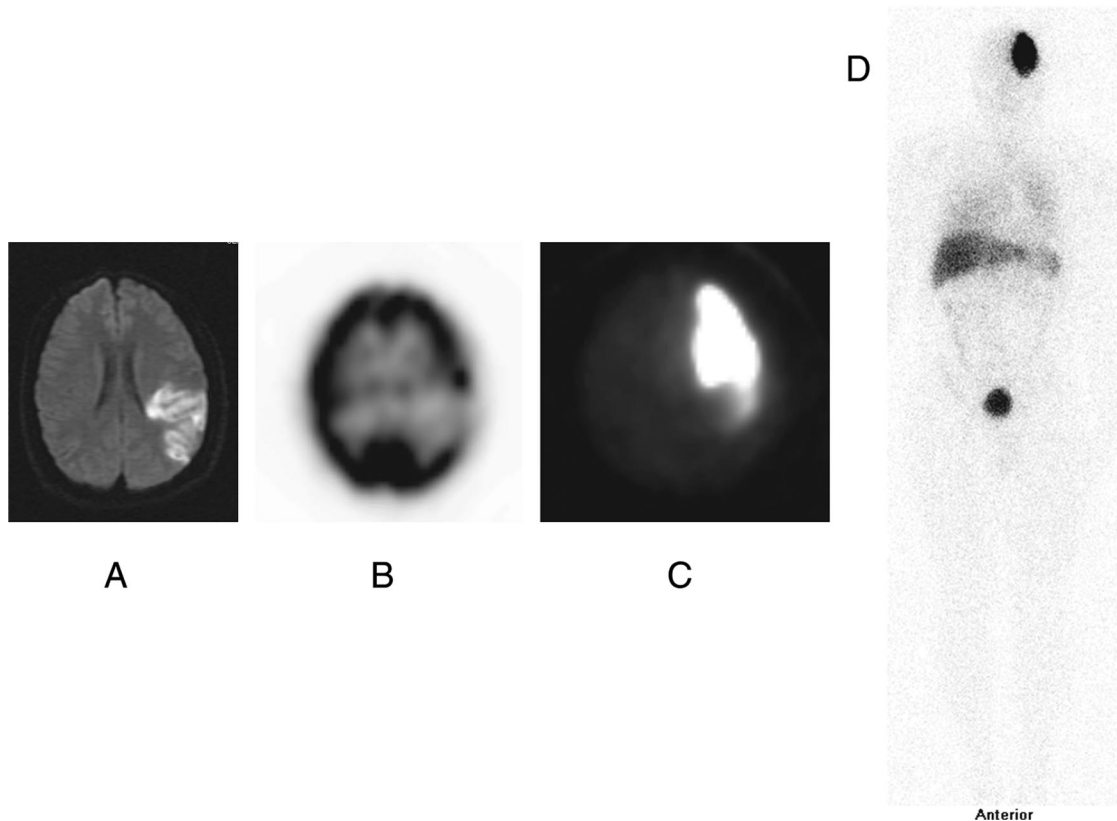
Copyright © 2007 by Lippincott Williams & Wilkins  
 ISSN: 0363-9762/07/3211-0839

hemianopsia. His National Institutes of Health Stroke Scale (NIHSS) score was 5. Magnetic resonance imaging (MRI) showed an acute ischemic infarct in the territory of the posterior branch of left middle cerebral artery (Fig. 1A). SPECT perfusion images with Tc-99m ECD demonstrated hypoperfusion in the left temporal and posterior parietal regions (Fig. 1B). The patient and his wife agreed to participate in a protocol about safety of intra-arterial autologous bone marrow mononuclear cell transplantation for acute ischemic stroke approved by the National Ethical Committee (CONEP 9396). The use of radiolabeled autologous mononuclear bone marrow cell (ABMMN) injection in acute stroke and the concomitant use of nuclear medicine imaging techniques were approved by the ethics committee on October 20, 2004 (amendment number 1, register number 76 in the ethics committee). No additional consent referent to this specific technique (radiolabeled ABMMN imaging) was obtained because the ethics committee considered it not necessary. The first consent included all nuclear medicine techniques pertinent to the case.

Approximately 4 hours before the cell injection procedure, bone marrow (50 mL) was aspirated under local anesthesia from the posterior iliac crest. ABMMN cells were isolated by density gradient on Ficoll-Paque Plus (Amersham Biosciences). Mononuclear cells were exhaustively washed with heparinized

saline containing 5% human serum albumin and filtered through a 100- $\mu$ m nylon mesh to remove cell aggregates. The cells were finally resuspended in saline with 5% human serum albumin for injection. Post hoc characterization of leukocyte differentiation markers by flow cytometry and functional assays was done on another fraction of cells. The clonogenic capacity of hematopoietic progenitors was evaluated by colony-forming assays (granulocyte-macrophage colony-forming unit). Bacterial and fungal cultures of the clinically used cell preparations were performed and proved negative.<sup>6</sup> ABMMN cells were isolated from bone marrow by a standard method and then were incubated under sterile conditions in a 10-mL test tube with 40 to 60 mCi 99mTc-HMPAO for 30 minutes followed by washing with NaCl isotonic solution and resuspension before application to remove excess unbound Tc-99m HMPAO. Radioactivity in the supernatant and cell pellet was measured with a dose calibrator. Labeled cells were infused into the stroke-related artery. A small fraction of the cell suspension was used for cell counting and viability testing with trypan blue dye exclusion assay. Cell viability was shown to be >90%, assuring the quality of the cell suspension.

Nine days after the stroke he received  $3.0 \times 10^7$  ABMMN cells delivered to the left middle cerebral artery via an intra-arterial catheter. Approximately 1% of the ABMMN



**FIGURE 1.** (A) Diffusion MRI showing acute ischemic lesion in the left middle cerebral artery territory. (B) Brain perfusion Tc-99m ECD SPECT showing left temporoparietal hypoperfusion. (C) Tc-99m HMPAO ABMMN cell brain SPECT revealing accumulation of the ABMMN-labeled cells in the left brain hemisphere, more intense in the anterior region. (D) Anterior whole-body scan with Tc-99m HMPAO ABMMN cells revealed left brain, liver, and spleen uptake. There was no lung uptake.

implanted cells were labeled by incubation with 150 MBq of Tc-99m HMPAO.

Brain SPECT images were obtained 8 hours after ABMMN-labeled cell delivery because after the stem cell intra-arterial delivery the patient returned to the intensive care unit for clinical stabilization. The procedure had no adverse effects but even so we preferred to wait to do the imaging technique with total security.

Cerebral arteriography done just before the implantation showed an occlusion in the posterior branch of the left middle cerebral artery (posterior parietal and angular arteries). The perfusion brain images were compared with SPECT views of the brain obtained 8 hours after ABMMN-labeled cell delivery. These revealed intense accumulation of the ABMMN-labeled cells in the ipsilateral hemisphere (Fig. 1C), which were more intense in the anterior division of the middle cerebral artery, probably due to posterior branch occlusion. A whole-body scan was done and showed left brain, liver, and spleen uptake. There was no lung uptake (Fig. 1D). The patient showed good recovery and NIHSS was zero 4 months after the stroke. Imaging was performed on a dual-head gamma camera (E-Cam Duet; Siemens) equipped with parallel-beam collimators. Acquisitions were performed for 30 minutes, using 64 angles through 360 degrees, step-and-shoot mode, and a zoom of 1.23. All acquisitions were done in a 128 × 128 matrix. Iterative reconstruction was performed on an E-soft workstation (Siemens). Gaussian filtering was applied to the data. Whole-body image was obtained at a scanning rate of 8 cm/min.

## DISCUSSION

Advances in the understanding of the biology of stem cells have evoked great interest in cell replacement therapies for stroke. However, the destination of the injected cells and their engraftment remain unclear. One major challenge for the development and refinement of stem cell transplantation is to map spatial distributions in situ. We reported a method for tracking transplanted stem cells in the ischemia-damaged brain by SPECT imaging with labeled ABMMN cells. In our technique 93% of the infused total radioactivity was cell bound and we had similar findings in acute myocardial infarction<sup>4</sup> with the main activity in the related injected area and additionally in the spleen, liver and background activity. The reticuloendothelial system took up most of the stem cells that were not retained in the infarcted organ. This is similar to our previous study,<sup>4</sup> and other studies.<sup>7</sup> We believe that part of background activity is a small fraction of radioactivity that was detached. In a previous report, enhanced glucose metabolic activity after stem cell implantation provided indirect evidence of engraftment in the infarcted area.<sup>8</sup> The described imaging approach is ideally suited for the noninvasive monitoring of cell engraftment, and permitted the observation of the implanted cells with high contrast against the host tissue. Our study demonstrated that Tc-99m HMPAO-labeled stem cell SPECT was feasible to assess stem cell homing and distribution in the initial 8 hours after delivery in acute ischemic stroke. As was demonstrated there was adequate labeling of the cells and cell retention in brain tissue. We

agree that we cannot provide information about the fate of the cells after this time, because we cannot assess their distribution or function after this time.

The distribution of stem cells after intra-arterial injection has not yet been elucidated. To evaluate the effect of stem cell therapy, assessments of stem cell homing, distribution, and differentiation are crucial. Cell labeling using a radioisotope is an established method in clinical nuclear medicine and has minimal toxicity. In-111 indium oxine, Tc-99m HMPAO and F-18 FDG have been accepted as in vivo cell-tracking methods. Tc-99m is advantageous because of its availability, better resolution and lower radiation exposure. We believe that our technique might be used to assess the adequacy of stem cell injection to the target tissue.

Because of the half-life of Tc-99m, delayed image after 24 hours is not feasible for evaluating stem cell distribution. Radiation exposure by Tc-99m HMPAO-labeled stem cell imaging might be another obstacle for routine use of stem cell tracking methods. We limited the radiation dose restricting the labeling to 1% of the injected cells. As high radiation exposure to stem cells may cause functional impairment, the imaging method with a minimal dose to stem cells is necessary. In vivo monitoring of stem cells after grafting is essential because the retention of transplanted cells into the target area may be critical for the success of cell therapy.<sup>9</sup> It has become apparent that a need exists to track stem cells in vivo during clinical trials. Our results showed that Tc-99m HMPAO can be used to label ABMMN cells for in vivo cell visualization, and that brain SPECT imaging with labeled ABMMN cells is a feasible noninvasive method for studying the fate of transplanted cells in vivo. Additionally, our findings suggest the localization of these intra-arterially injected cells.

## REFERENCES

1. Haas S, Weidner N, Winkler J. Adult stem cell therapy in stroke. *Curr Opin Neurol*. 2005;18:59–64.
2. Wei L, Keogh CL, Whitaker VR, et al. Angiogenesis and stem cell transplantation as potential treatments of cerebral ischemic stroke. *Pathophysiology*. 2005;12:47–62.
3. Lishmanov Y, Sazonova V, Chernov T, et al. Tracking of autologous mononuclear bone marrow cells after intracoronary infusion by direct labeling with 99mTc-HMPAO in patients with cardiac disease. *Eur J Nucl Med Mol Imaging*. 2004;31(suppl 2):S321.
4. Mesquita CT, Corrêa PL, Felix RC, et al. Autologous bone marrow mononuclear cells labeled with Tc-99m hexamethylpropylene amine oxime scintigraphy after intracoronary stem cell therapy in acute myocardial infarction. *J Nucl Cardiol*. 2005;12:610–612.
5. Mendonca ML, Freitas GR, Silva SA, et al. Safety of intra-arterial autologous bone marrow mononuclear cell transplantation for acute ischemic stroke. *Ar Qbras Cardiol*. 2006;86:52–55.
6. Perin EC, Dohmann HFR, Borojevic R, et al. Transendocardial, autologous bone marrow cell transplantation for severe, chronic ischemic heart failure. *Circulation*. 2003;107:2294–2302.
7. Kang WJ, Kang HJ, Kim HS, et al. Tissue distribution of 18F-FDG-labeled peripheral hematopoietic stem cells after intracoronary administration in patients with myocardial infarction. *J Nucl Med*. 2006;47:1295–1301.
8. Corrêa PL, Felix R, Mendonça ML. Dual-head coincidence gamma camera FDG-PET before and after autologous bone marrow mononuclear cell implantation in ischaemic stroke. *Eur J Nucl Med Mol Imaging*. 2005;32:999.
9. Hoehn M, Kustermann E, Blunk J, et al. Monitoring of implanted stem cell migration in vivo: a highly resolved in vivo magnetic resonance imaging investigation of experimental stroke in rat. *Proc Natl Acad Sci USA*. 2002;25:16267–16272.