

Brain herniation through an internal subdural membrane: a rare complication seen with chronic subdural hematomas in children

Case report

LESLIE ACAKPO-SATCHIVI, M.D., PH.D., AND THOMAS G. LUERSSEN, M.D.

Section of Pediatric Neurosurgery, Indiana University School of Medicine, James Whitcomb Riley Hospital for Children, Indianapolis, Indiana

✓The authors report an unusual case of cortical herniation into a chronic subdural hematoma (SDH). The patient was successfully treated with good outcome. A 4-month-old boy with a history of macrocrania and very large bilateral chronic SDHs underwent subduroperitoneal shunt treatment shortly after presentation. Eight months later he developed a new-onset seizure disorder, which was localized by electroencephalography to the right frontal region. Neuroimaging demonstrated the development of a focal herniation of the brain through a subdural membrane into the subdural space. The patient underwent a craniotomy to resect the seizure focus and the herniated cortex. The subdural shunt was subsequently replaced. After 2 years of follow-up, the patient remains free of seizures, is on no medication regimen, and is neurologically and developmentally normal. To the authors' knowledge, this is only the fourth report in the medical literature of cortical herniation through a chronic subdural membrane and the first in which successful treatment with a good outcome is described. (DOI: 10.3171/PED-07/12/485)

KEY WORDS • chronic subdural hematoma • complication • cortical herniation • pediatric neurosurgery • subdural shunt

CHRONIC subdural fluid collections in infants and children occur almost exclusively before the age of 2 years, and they appear to happen mostly as a result of trauma.^{5,6} A number of complications of chronic subdural fluid collections and their various therapies have been noted in the literature. These include intracranial hypertension, with possible visual loss, brain atrophy, macrocrania, craniocerebral disproportion, seizure disorder, and developmental delay.^{2,6,7} Large chronic subdural collections are commonly treated by placing a subduroperitoneal shunt.

A very rare, or at least rarely reported, complication of chronic subdural hematoma apparently involves the herniation of brain matter through the internal subdural membrane. This complication was initially termed “internal encephalocele” by the authors who first described it in 1992.⁴ Two subsequent cases were described in 1999 and 2002.^{1,3} None of the children described in these cases was treated, and all experienced poor outcomes. We recently encountered a case of acquired cerebral herniation that responded well to surgical correction. The imaging characteristics sug-

gested that a traumatic pial defect and a growing brain might have played a role in the development of this complication.

Case Report

History and Examination. This 4-month-old boy underwent evaluation for macrocephaly. His head circumference measured 48 cm, which was well above the expected range of normal for his age. He was otherwise reported to be asymptomatic. A CT scan revealed bilateral large hypodense, subdural fluid collections, consistent with chronic SDHs (Fig. 1). A comprehensive search for any other evidence of inflicted injury did not reveal any findings, although there was a history of a long bone fracture that had been treated elsewhere when the patient was 2 months old. An investigation at that time was also undertaken, but no action was taken. During our assessment, it was determined that the child had a mild deficiency of factor VII, but not to a degree that required any active therapy. Shortly after presentation, the patient underwent the uncomplicated insertion of a subduroperitoneal shunt.

Over the ensuing 8 months the shunt functioned well, and

Abbreviations used in this paper: CT = computed tomography; MR = magnetic resonance; SDH = subdural hematoma.

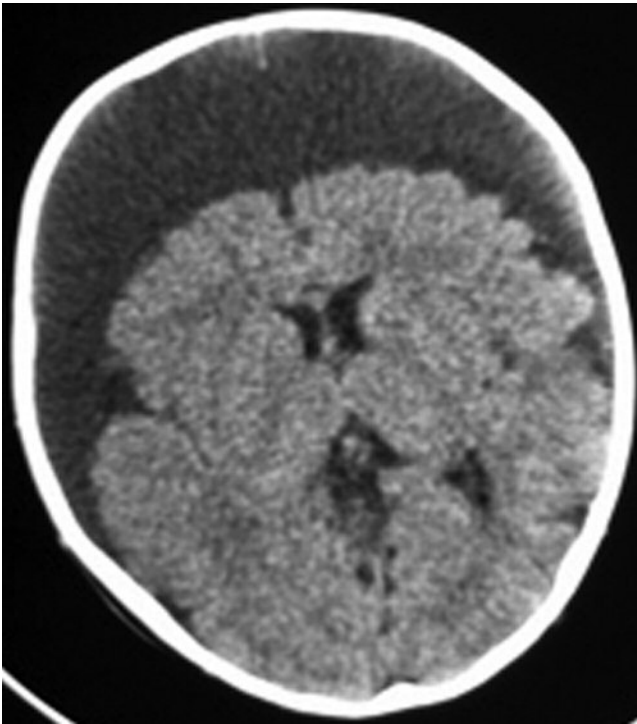


FIG. 1. Noncontrast CT scan of brain at presentation demonstrating large bilateral chronic SDHs.

the accumulation of subdural fluid appeared to be resolving. The patient's head circumference stabilized. He underwent regular follow-up neuroimaging, which demonstrated progressively smaller subdural collections. At 12 months of age, the child experienced a series of tonic-clonic seizures. He was seen at another institution, and anticonvulsants were given. Electroencephalography showed an epileptic focus in the right frontopolar region, strongly suggestive of a structural lesion. At that point he returned to our care and underwent repeated neuroimaging.

A CT scanning study and subsequent MR imaging of the brain demonstrated an apparent area of herniation of cortex into the subdural space along the right frontal polar region. Review of the series of MR images obtained after the placement of the shunt showed that the condition was progressively worsening, and up until the onset of the seizures asymptomatic herniation of cortex into the subdural space was noted (Fig. 2).

Operation. The cerebral herniation was approached through a bifrontal craniotomy. The subdural shunt, which appeared to be functional, was removed. After elevating the bone flap, the dura mater was noted to be intact. The sagittal sinus was isolated between clips, and the dura was opened along the frontal base. The falx cerebri was conspicuously absent. The chronic external subdural membrane was only mildly adherent to the underside of dura. After opening the external subdural membrane and evacuating clear subdural fluid, we could identify the defect in the internal membrane and the cortical herniation erupting through a very constrictive opening in the internal membrane (Fig. 3).

Once the internal subdural membrane was isolated and opened, we worked within a normal-appearing subarachnoid space and were able to completely circumnavigate the

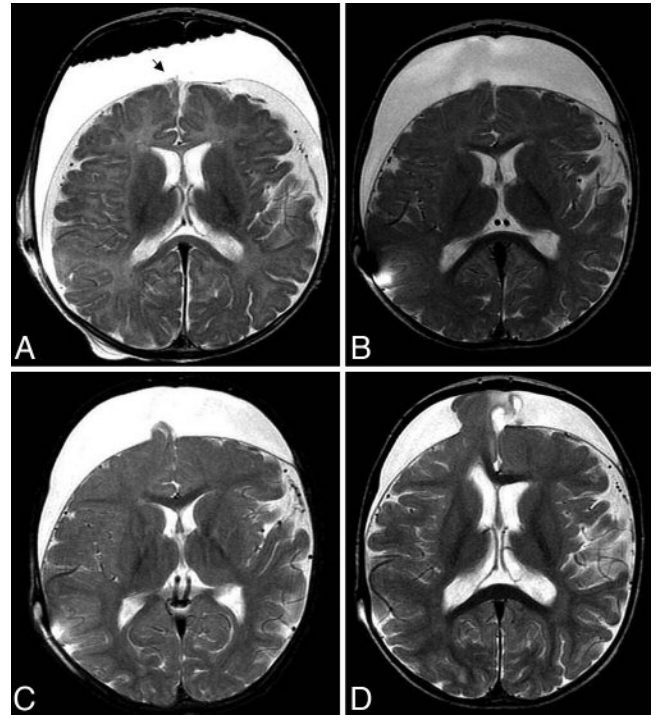


FIG. 2. Axial T2-weighted MR images of the brain at relatively similar planes of section performed at 4 months of age immediately following subduroperitoneal shunt insertion (A); 7 months of age (3 months after shunt placement [B]); 10 months of age (6 months after shunt placement [C]); and after presentation with new onset seizures at 12 months of age (8 months after shunt placement [D]). The area of cortical herniation is visible on the initial study (arrow in A) and clearly worsens over time.

area of brain herniation. It appeared grossly abnormal and chronically ischemic. It was resected, and the remaining subdural membranes were removed as far as the exposure would allow.

Postoperative Course. Several weeks later it became necessary to replace the subdural shunt because of recurrence of what now appeared to be subdural hygromas. The child had no further seizures, electroencephalography showed no epileptiform activity, and the patient was progressively weaned off anticonvulsants. He is now neurologically and developmentally normal. An MR image obtained 2 years after the treatments shows only the residual effects of the tissue loss in the area of the previous cortical herniation (Fig. 4). The subdural shunt has not required any further maintenance, and the subdural fluid collection has resolved.

Discussion

We describe an unusual case of progressive herniation of cerebral cortex into the subdural space in a child who was being treated for large chronic SDHs. Whether this is an unusual associated primary injury, an effect of the chosen therapy, or a combination of these factors is not clear. Treating physicians should be aware of this unusual complication, especially in the context of the development of new symptoms during therapy.

Naidich et al.⁴ initially reported on this condition and

Cortical herniation into subdural space

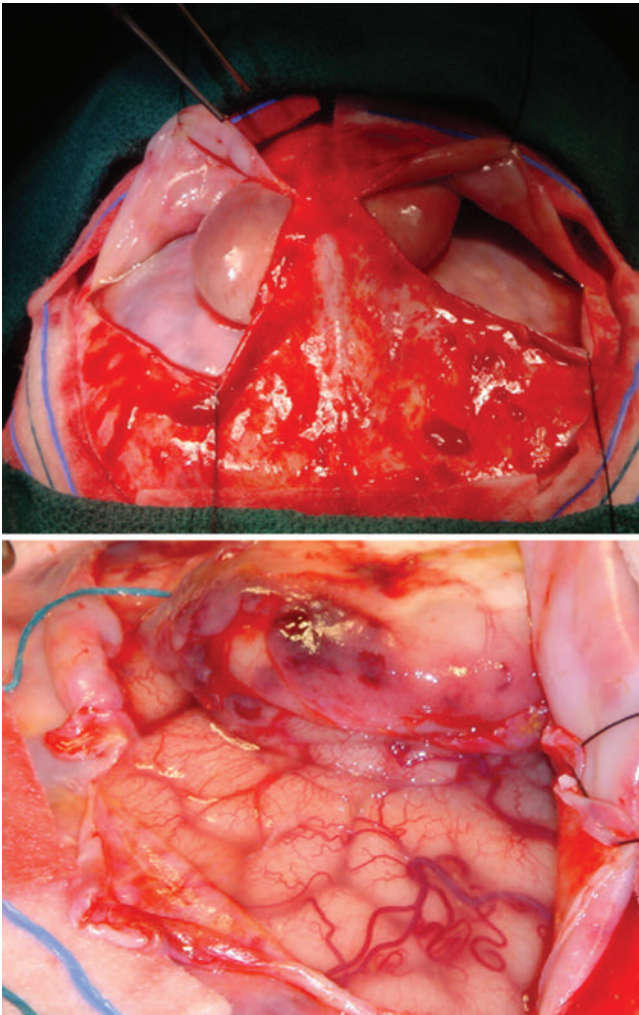


FIG. 3. Intraoperative photographs. *Upper:* The appearance after opening the dura and the outer subdural membrane. *Lower:* The appearance after opening the inner subdural membrane, prior to resecting the herniated cortex.

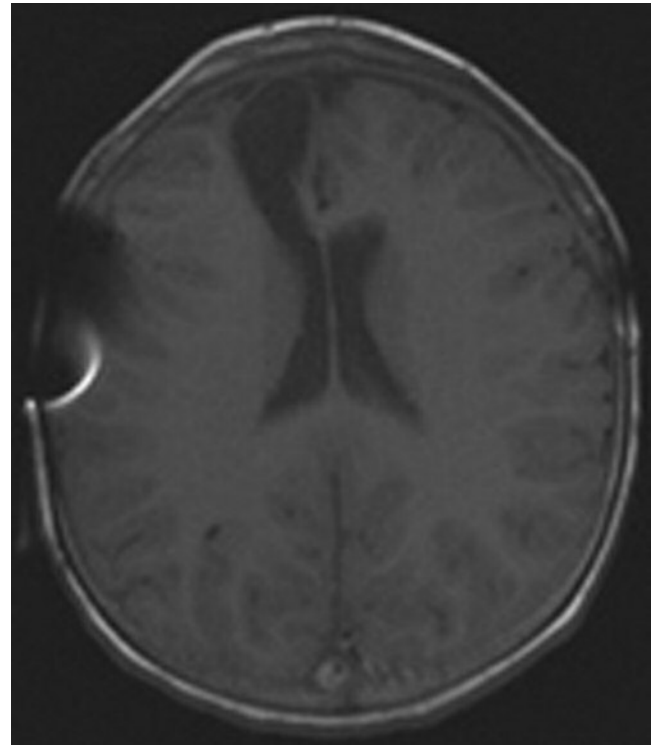


FIG. 4. An MR image obtained 2 years after surgery, demonstrating the residual tissue loss where cortex herniated through the inner membrane and pial defect. The artifact from the subdural shunt is visible, but the extracerebral fluid collections have resolved.

termed it internal cephalocele. They reported on a 1-year-old patient who had undergone ventriculoperitoneal shunt placement for the treatment of hydrocephalus. The patient subsequently developed craniocerebral disproportion with very large bilateral subdural fluid collections and herniation of brain through the internal subdural membrane. The authors surmised that the intracranial anatomy was altered by the trauma of surgery, resulting in a membrane partition and thereby allowing an opportunity for the brain herniation.

Several years later, Ceccherini and Jaspán¹ described a case of a 1-month-old victim of inflicted brain injury who exhibited bilateral SDHs of differing ages. The child was treated initially with needle drainage and ultimately required subduroperitoneal shunt treatment. Apparently the child was profoundly impaired. On follow-up imaging 1 year later, the authors described the findings of severe atrophy, chronic subdural collections, and cerebral herniation through the subdural membrane. No intervention was undertaken because of the patient's poor neurological status. These authors compared the pathophysiology of internal cephalocele

formation to that of growing skull fractures, and they suggested that brain pulsations played a significant role in pushing the cortex through the neomembrane in the same way that the leptomeninges are forced through dural and calvarial defects in patients with growing fractures. This proposal seems logical, especially in view of the finding that we could not find a report suggesting that this particular complication has been reported in the adult population.

Finally, most recently, Motoyama et al.³ described a case of an 11-month-old girl who was the victim of an inflicted injury 7 months previously. She had presented with hemiparesis and macrocrania. Magnetic resonance imaging showed large subdural fluid collections and herniation of the left parietal parenchyma into the subdural cavity. This patient was treated by subduroperitoneal shunt placement. The authors described improvement in the patient's symptoms and imaging improvement in the cerebral herniation, but persistence of the large subdural collections.

The clinical course of our patient differs in several ways from all of the previous reports. First, it is clear in retrospect that there was an irregularity on the frontopolar surface visible on the initial MR image (Fig. 2). Over time this area develops into a frank herniation of cortex. It was not commented on at the time of the studies, and the patient was asymptomatic. It seems likely to us that the cause of the chronic SDHs and this cortical "injury" are related. Perhaps this was the location of the vascular and pial disruption at the time of initial injury.

Second, our patient developed the herniation in the presence of a functioning subdural shunt, unlike the patient de-

scribed by Motoyama et al.³ It is possible that the functional shunt in our patient may have actually accelerated the process of cortical herniation. It is difficult to reconcile this hypothesis with the indication from Motoyama and colleagues that shunt placement appeared to reverse the cortical herniation.

Ultimately, our patient developed symptoms. The shunt appeared to be functional and necessary. Our treatment focused on the presumption that the herniated brain was epileptogenic and should be surgically removed. Although our patient responded well to this therapy, his neurological outcome is primarily related to the overall preservation of his brain by the original injury and the location of the cerebral disruption. Given the findings of Motoyama et al.³ the natural history of this unusual complication is unclear.

In conclusion we would alert physicians caring for children with chronic SDHs to be aware of this unusual complication. Although it is obvious that the development of new symptoms should be a reason for patients to undergo neuroimaging, we would also suggest that the identification of areas of cortical irregularity along the inner surface of subdural collections may be an indication for regular and relatively frequent follow-up imaging.

References

1. Ceccherini AF, Jaspan T: Cerebral herniation through a subdural membrane defect following non-accidental injury. **Clin Radiol** **54**:550–552, 1999
2. Korinth MC, Lippitz B, Mayfrank L, Gilsbach JM: Subdural-atrial and subdural-peritoneal shunting in infants with chronic subdural fluid collections. **J Pediatr Surg** **35**:1339–1343, 2000
3. Motoyama Y, Isaka F, Nabeshima S: Internal intracranial encephalocele reduced by a subdural-peritoneal shunt. Case illustration. **J Neurosurg** **96**:966, 2002
4. Naidich TP, Altman NR, Braffman BH, McLone DG, Zimmerman RA: Cephaloceles and related malformations. **AJNR Am J Neuroradiol** **13**:655–690, 1992
5. Sauter KL: Percutaneous subdural tapping and subdural peritoneal drainage for the treatment of subdural hematoma. **Neurosurg Clin N Am** **11**:519–524, 2000
6. Swift DM, McBride L: Chronic subdural hematoma in children. **Neurosurg Clin N Am** **11**:439–446, 2000
7. Vinchon M, Noulé N, Soto-Ares G, Dhellemes P: Subduroperitoneal drainage for subdural hematomas in infants: results in 244 cases. **J Neurosurg** **95**:249–255, 2001

Manuscript submitted July 27, 2007.

Accepted August 20, 2007.

Current address for Dr. Acakpo-Satchivi: Children's Hospital of Alabama, Birmingham, Alabama.

Current address for Dr. Luerssen: Texas Children's Hospital, Houston, Texas.

Address correspondence to: Thomas G. Luerssen, M.D., Pediatric Neurosurgery Service, Texas Children's Hospital, Clinical Care Center, 6621 Fannin Street, MC CC 1230.01, Houston, Texas 77098. email: tgluerss@texaschildrenshospital.org.