

# Treatment of juvenile stroke using Yamamoto New Scalp Acupuncture (YNSA) – a case report

Toshikatsu Yamamoto, Thomas Schockert, Babak Boroojerdi

Toshikatsu Yamamoto  
director  
Yamamoto Hospital  
Nichinan, Japan

Thomas Schockert,  
specialist in general  
medicine, acupuncture  
and naturopathy  
Nideggen, Germany

Babak Boroojerdi  
neurologist  
University Hospital  
Aachen, Germany

Correspondence:  
Thomas Schockert

thomas-schockert  
@gmx.net

## Abstract

In Germany, stroke affects approximately 300 children each year. Treatment options for stroke patients, particularly for children, are limited. A case is described of an 18 month old girl with hemiparesis, who showed a considerable degree of recovery over the course of 21 months while receiving Yamamoto New Scalp Acupuncture using soft laser. This may represent a new option for the therapy of such patients.

## Keywords

YNSA, juvenile stroke, soft laser.

## Description of the case

The patient, a three year old girl, suffered from a haemorrhagic stroke 18 days after an uneventful birth, followed by generalised seizures. She was the first child of her parents and there was no relevant medical history in the family. The diagnosis of left sided spastic hemiparesis, facial paresis and seizures was made.

When the patient was discharged from hospital care, the parents were told that the child would be disabled for the rest of her life. They were told that there was no known treatment and there was no chance of natural recovery from stroke. For this reason, the parents decided to seek integrative medicine, and were offered Yamamoto New Scalp Acupuncture (YNSA).

On clinical examination there was a left sided facial paresis and spastic hemiparesis, together with delay in mental and language capacities.

Imaging investigations (cerebral CT and MRI scans and angiography) performed three weeks after birth showed infarcted areas in the right parietal lobe and a small right sided subdural hygroma (collection of cerebrospinal fluid). Several focal lesions could be detected on the MRI scan without any relation to arterial territories.

## Treatment with YNSA therapy

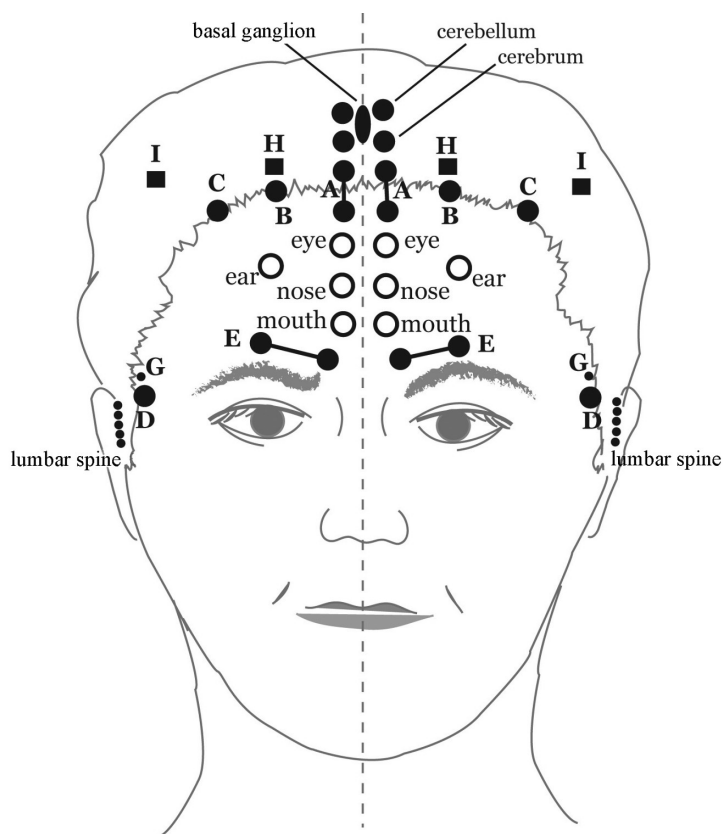
YNSA was performed using a 4mW Softlaser – low power laser (Bio Laser privat M1 530101, CE 0482;

Servoprax GmbH D-46485 Wesel). YNSA is generally used for treatment of pain and motor impairments. Pain is usually treated ipsilaterally and paresis is treated contralaterally.<sup>5</sup>

In order to find out which sites need to be treated, standard abdominal or neck points are usually palpated and the patient gives the treating physician feedback about which points are tender. In this case, such feedback was not possible so the following standard acupuncture points were treated: ‘basis point B’ for shoulder; point C for the upper extremity; point D for the lower extremity (Figure 1), all on the right. Also, the ‘basal ganglia’ and ‘cerebrum’ points were treated. Because of the difficulties with the language and intellectual development, the ‘aphasia’ and ‘mouth’ points were treated on the right side. The ‘aphasia’ point is located in front of the ear between the Y points ‘spleen’ and ‘stomach’.

The ‘aphasia’ point is usually treated in combination with the ‘mouth’ point to treat dysphasia. Treatment of ‘brain’ points is thought to enhance the effects of the ‘basis’ points and the ‘brain’ point is used for neurological disorders. In case of paresis, the ‘brain’ points are treated on the contralateral side. These points were treated in each session three times for 10 seconds.

Treatment duration was 21 months. The treatment was started in January 2004, 18 months after the stroke, and finished in September 2005. During this time, 45 treatments were performed.



## YNSA Basic-Points, Sensory-Points, Brain-Points

- A-Point: cervical spine, divided 1-7 from above
- B-Point: shoulder, trapezius
- C-Point: shoulder joint, upper arm, elbow, lower arm, hands/fingers
- D-Point: lower body/lumbar spine, sacrum, coccyx, lower extremities
- E-Point: chest/thoracic spine, 1-12 from above
- F-Point: sciatic nerve, only in the Yang position
- G-Point: knee
- H-Point: extra lumbar point
- I - Point: extra lumbar and sciatic point

*Figure 1 This figure shows the YNSA basic points, as well as the brain points. The YNSA points were treated three times for 10 seconds in each session.*

Before YNSA the patient could only turn from supine to prone position and vice versa. After four YNSA sessions an increase in the mobility of the left arm was observed. After 10 sessions it was possible for the girl to move of all fours, and she started to walk with the help of her mother.

After 23 sessions, she could stand on her own, could crawl, had power in her left hand and could open and close the left fist. She has had no further epileptic seizures since the start of the YNSA, and the left facial paresis has recovered completely. In addition to YNSA, she has been treated with physical therapy, but no medication has been used. In view

of the apparent clinical recovery, the investigations were not repeated.

### Discussion

Each year, about six million patients suffer from stroke worldwide. In Germany, there are approximately 300 children who have a stroke each year. The therapeutic choices for patients with stroke, especially for children, are limited.<sup>3,4</sup> Physiotherapy and language therapy are used routinely in these patients but are not very effective. YNSA offers here a possible adjuvant therapy to enhance and complement the other therapeutic options without

limiting or replacing them. This therapy has a particularly low rate of adverse events and can be used across a wide range of ages. Its effectiveness has been suggested for pain and stroke related paresis in adults.<sup>1</sup> This treatment can start in acute care hospitals or on stroke units and can continue in rehabilitation centres, or at home, by primary care physicians. Laser acupuncture has been shown to be effective and safe.<sup>2</sup> However, trials of acupuncture in paediatric populations suffering from stroke have not yet been conducted.

### Conclusion

YNSA with soft laser could be a safe and efficacious alternative therapy of stroke in the paediatric population. Larger studies are needed to test this hypothesis.

### Reference list

1. Borojerd B, Yamamoto T, Schumpe G, Schockert T. Treatment of stroke-related motor impairment by Yamamoto New Scalp Acupuncture (YNSA): an open, prospective, topometrically controlled study. *Medical Acupuncture* 2005;17(1): 24-8.
2. Pötinen PJ, Pothmann R: *Laser in der Akupunktur, Grundlagen, Indikationen und Techniken für die Akupunktur-Schwerpunktpraxis*, Stuttgart: Hippokrates; 1998.
3. Rosenbloom, L. Management of stroke in childhood. *BMJ* 2005;330(7501):1161-2.
4. Steinlin M, Pfister I, Pavlovic J, Everts R, Boltshauser E, Capone Mori A, et al, The Swiss Societies of Pediatric Neurology and Neonatology: The first three years of the Swiss Neuropaediatric Stroke Registry (SNPSR): A population based study of incidence, symptoms and risk factors. *Neuropediatrics* 2005;36(2):90-7.
5. Yamamoto T, Yamamoto H, Yamamoto MM. *Yamamoto Neue Schädel Akupunktur YNSA*. Kötzing: Verlag für ganzheitliche Medizin; 2005.



# Treatment of juvenile stroke using Yamamoto new scalp acupuncture (YNSA) – a case report

Toshikatsu Yamamoto, Thomas Schockert and Babak Boroojerdi

*Acupunct Med* 2007 25: 200-202  
doi: 10.1136/aim.25.4.200

---

Updated information and services can be found at:  
<http://aim.bmj.com/content/25/4/200>

---

## Email alerting service

*These include:*

Receive free email alerts when new articles cite this article. Sign up in the box at the top right corner of the online article.

---

## Notes

---

To request permissions go to:  
<http://group.bmj.com/group/rights-licensing/permissions>

To order reprints go to:  
<http://journals.bmj.com/cgi/reprintform>

To subscribe to BMJ go to:  
<http://group.bmj.com/subscribe/>