

This case indicates that watershed infarction is a potential complication of acute hypereosinophilia. Local thrombus formation is possible; however, microthromboembolic cause must be considered, given the known predilection of small emboli for watershed regions.^{3,7} Clinicians should be aware of such complications of hyperviscous states.

From the Department of Pediatrics, Division of Neurology, Children's Hospital of Eastern Ontario, Ottawa, Canada (H.J.M., A.D.); and Department of Pediatrics, Division of Hematology-Oncology, Children's Hospital of Eastern Ontario, Ottawa, ON Canada (D.L.J.).

Disclosure: The authors report no conflicts of interest.

Received September 11, 2006. Accepted in final form April 6, 2007.

Address correspondence and reprint requests to Dr. A. Doja, Children's Hospital of Eastern Ontario, Division of Neurology, 401 Smyth Road, Ottawa, Ontario, Canada, K1H 8L1; adoja@cheo.on.ca

H. Tanaka, MD
M. Arai, MD
T. Kadowaki, MD
H. Takekawa, MD
N. Kokubun, MD
K. Hirata, MD

PHANTOM ARM AND LEG AFTER PONTINE HEMORRHAGE

The phantom limb appears not only after limb amputation¹ but also after brain damage (known as supernumerary phantom limb [SPL]).² A previous review¹ on phantom limb following limb amputation proposed the remapping hypothesis of topographic reorganization of somatosensory cortex in which the referred sensation from the neighboring receptive field to phantoms is one of at least five possible sources for phantom sensation. On the other hand, the current theories of SPL emphasize the dissociation between established sensorimotor limb representation and marked changes in afferent and efferent signals in brain–limb communication.^{3,4}

There is little information about SPL in patients with brainstem damage,⁵ which has somewhat different characteristics from phantom sensations following supratentorial cerebral lesions, as well as from phantoms following limb amputation. Here we address the contribution of the brainstem to SPL.

Case reports. A 47-year-old woman (Case 1) and a 55-year-old man (Case 2) developed acute pontine hemorrhage (figure, A [a, b] and B [a, b]). They survived a locked-in period with complete paralysis except for vertical eye movements. The neurologic examination including sensory system was limited due to poor communication. One month after the onset, once they started showing some functional recovery, SPL was recognized. Neurologic examination of both patients after recovery revealed left hemiplegia and hemianesthe-

Copyright © 2008 by AAN Enterprises, Inc.

1. Moore PA, Harley JB, Fauci AS. Neurologic dysfunction in the idiopathic hypereosinophilic syndrome. *Ann Int Med* 1985;102:109–114.
2. Chusid MJ, Dale DC, West BC, Wolff SM. The hypereosinophilic syndrome: analysis of fourteen cases with review of the literature. *Medicine* 1975;54:1–27.
3. Torvic A. The pathogenesis of watershed infarcts in the brain. *Stroke* 1984;15:221–223.
4. Schaar CG, Brouwer OF, Wondergem JHM. Watershed infarction after near drowning in a two year old child. *Clin Neurol Neurosurg* 1991;93:159–161.
5. Yazdi R, Cote C. Watershed infarct in a case of polycythemia vera. *Clin Nucl Med* 1986;11:665–666.
6. Ishii T, Koide O, Hosoda Y, Takahashi R. Hypereosinophilic multiple thrombosis. *Angiology* 1977;28:361–375.
7. Pollanen MS, Deck JH. The mechanism of embolic watershed infarction: experimental studies. *Can J Neurol Sci* 1990;17:395–398.

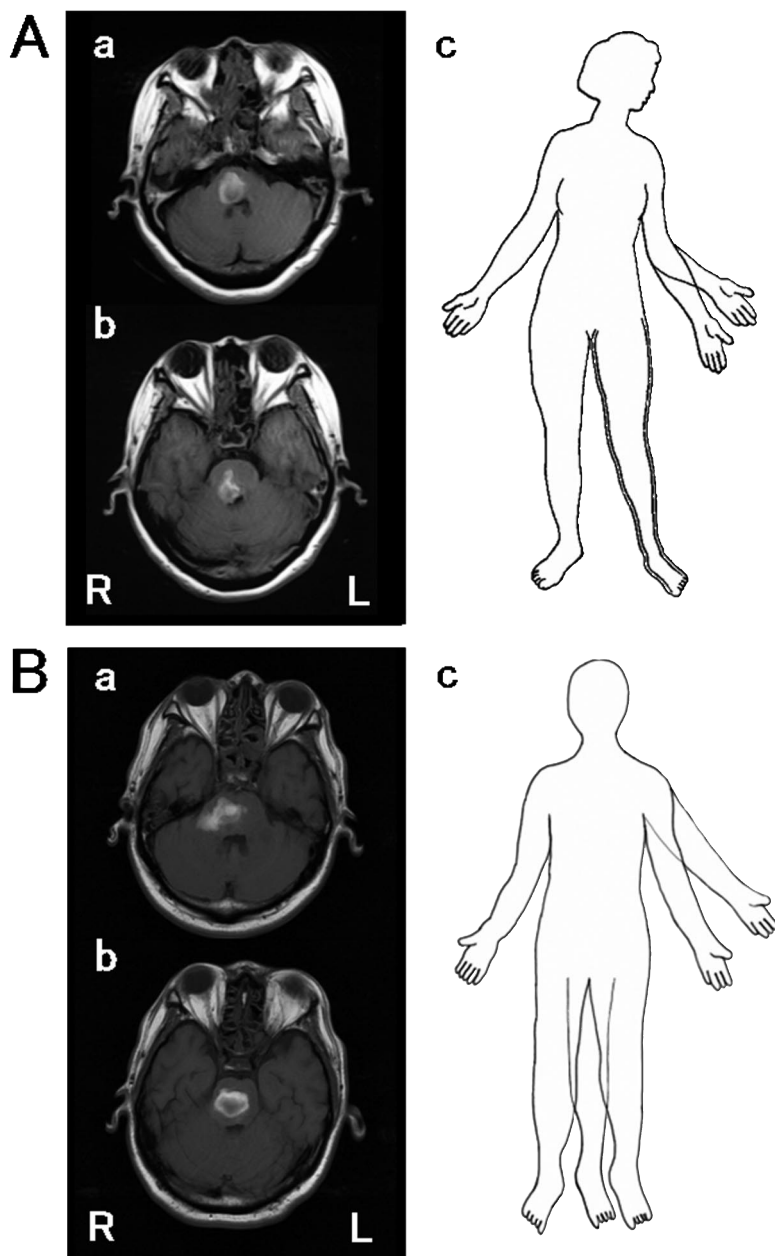
sia. Cognition was intact, without left neglect or anosognosia. Both patients acknowledged the existence of extra limbs, as described in detail here.

Case 1. The arm located on the left along the side of the true arm diverging from the elbow was formed perfectly with a palm-up hand and five fingers, shorter than the true arm (figure, A [c]). The patient could move it voluntarily, though she described occasional loss of control and feeling strangulated by the phantom arm around the neck resembling anarchic limb⁶ although there was no antagonistic action in the right arm like alien limb. She regained motor control again without rule. Unpleasant burning or freezing sensation was experienced occasionally in the third arm, which was not caused by any noticeable factor, but matched similar sensations she experienced in the true left arm prior to hemorrhage. She also perceived a motionless third leg medial to the true left leg (figure, A [c]). The third arm and leg persisted for 6 months without telescoping perception, with no remarkable changes in left hemiplegia or sensory loss.

Case 2. The arm was located on the left along the patient's true arm, of equal length and morphology to the true arm, diverging from the shoulder with a palm-up hand (figure, B [c]). He remembered the existence of the third arm since the locked-in state. Although he could move it, the voluntary control was lost sometimes with the occurrence of a squeezing pain that was not triggered by any noticeable event, and regained motor control again without rule. The pain was similar to a sensation felt in the true left arm prior to hemorrhage. The third arm disappeared immediately whenever he touched the true left arm with the right hand. He also perceived a third leg on the right inner side of the true left leg, which was of similar length and shape to the left leg (figure, B [c]). He could control the movement of the third leg. The third arm and leg gradually disappeared without telescoping perception within 1 week during the recovery of left hemiplegia.

We studied the localization of light touch sensation to check the remapping of receptive fields for the arm,¹ but neither patient reported referred sensation especially from the face both ipsilateral and contralateral to the third arm. We

Figure Axial T1-weighted images



(a, b) Axial T1-weighted images (repetition time: 150 msec [A: Case 1], 593 msec [B: Case 2], echo time: 15 msec [A], 15 msec [B], obtained 43 [A] and 22 [B] days after the onset of stroke). Note the relatively right lateralized hematoma in the anteromedial to dorsolateral portion from middle to upper pons in both cases. (c) Illustration of the configuration of supernumerary upper and lower phantom limbs reported by Case 1 [A] and Case 2 [B]. See text for further details.

did not test the remapping of the third leg; however, the patients did not report any phantom sensations when they were bed bathed.

Discussion. Our cases do not fit the remapping hypothesis because total hemianesthesia should

not elicit a referred sensation from the ipsilateral neighboring receptive field (face) to SPL. According to a report of anosognosia for hemiplegia after pontine infarction,⁷ the pons is suggested as an integral part of a complex system subserving body perception and that pontine lesions cause functional deactivation of frontal and parietal areas through the limbic system and the thalamus. Our cases showed sensory deafferentation with pontine transection of pyramidal tracts, probably triggering the phantom limb image. The mechanism of early disappearance of SPL in Case 2 could be related to earlier motor recovery.

Although there are no reports of SPL in locked-in patients, Case 2 suggests the possible existence of such phenomenon. One should be aware of this in locked-in patients, especially because they cannot provide details of SPL and it may produce distress.

From the Department of Neurology (H. Tanaka, T.K., H. Takekawa, N.K., K.H.), Dokkyo Medical University, Tochigi; and the Department of Neurology (M.A.), Tokyo Medical University, Kasumigaura Hospital, Ibaraki, Japan.

Disclosure: The authors report no conflicts of interest.

Received August 2, 2006. Accepted in final form May 10, 2007.

Address correspondence and reprint requests to Dr. Hideaki Tanaka, Department of Neurology, Dokkyo Medical University, Kitakobayashi 880, Mibu, Tochigi 321-0293, Japan; hide@dokkyomed.ac.jp

Copyright © 2008 by AAN Enterprises, Inc.

ACKNOWLEDGMENT

The authors thank M. Saito for technical support.

REFERENCES

1. Ramachandran VS, Hirstein W. The perception of phantom limbs. The D.O. Hebb lecture. *Brain* 1998; 121:1603–1630.
2. Brugger P. Supernumerary phantoms: a comment on Grossi, et al's (2002) spare thoughts on spare limbs. *Percept Mot Skills* 2003;97:3–10.
3. Bakheit AM, Roundhill S. Supernumerary phantom limb after stroke. *Postgrad Med J* 2005;81:e2.
4. Melzack R. Labat lecture. Phantom limbs. *Reg Anesth* 1989;14:208–211.
5. Frederiks JAM. Phantom limb and phantom limb pain. *Handbook of clinical neurology*. Vol 1. Clinical neurology. Amsterdam: Elsevier, 1985; 395–404.
6. Marchetti C, Della Sala, S. Disentangling the alien and anarchic hand. *Cogn Neuropsychiatry* 1998;3:191–207.
7. Evyapan D, Kumral E. Pontine anosognosia for hemiplegia. *Neurology* 1999;53:647–649.

Neurology[®]

PHANTOM ARM AND LEG AFTER PONTINE HEMORRHAGE

H. Tanaka, M. Arai, T. Kadowaki, et al.

Neurology 2008;70;82-83

DOI 10.1212/01.wnl.0000265394.80360.b5

This information is current as of December 31, 2007

Updated Information & Services	including high resolution figures, can be found at: http://www.neurology.org/content/70/1/82.full.html
References	This article cites 6 articles, 3 of which you can access for free at: http://www.neurology.org/content/70/1/82.full.html##ref-list-1
Citations	This article has been cited by 1 HighWire-hosted articles: http://www.neurology.org/content/70/1/82.full.html##otherarticles
Subspecialty Collections	This article, along with others on similar topics, appears in the following collection(s): Cerebral venous thrombosis http://www.neurology.org/cgi/collection/cerebral_venous_thrombosis Developmental disorders http://www.neurology.org/cgi/collection/developmental_disorders MRI http://www.neurology.org/cgi/collection/mri
Permissions & Licensing	Information about reproducing this article in parts (figures, tables) or in its entirety can be found online at: http://www.neurology.org/misc/about.xhtml#permissions
Reprints	Information about ordering reprints can be found online: http://www.neurology.org/misc/addir.xhtml#reprintsus

Neurology® is the official journal of the American Academy of Neurology. Published continuously since 1951, it is now a weekly with 48 issues per year. Copyright . All rights reserved. Print ISSN: 0028-3878. Online ISSN: 1526-632X.

