

Original Article

Distribution of cerebello-olivary degeneration in idiopathic late cortical cerebellar atrophy: Clinicopathological study of four autopsy cases

Satoru Ota,¹ Kuniaki Tsuchiya,² Midori Anno,¹ Kazuhiro Niizato³ and Haruhiko Akiyama⁴

Departments of ¹Neurology, ²Laboratory Medicine and Pathology and ³Psychiatry, Tokyo Metropolitan Matsuzawa Hospital, and ⁴Department of Neuropathology, Tokyo Institute of Psychiatry, Tokyo, Japan

Late cortical cerebellar atrophy (LCCA) is a neurodegenerative disease which presents with slowly progressive cerebellar ataxia as a prominent symptom and is characterized neuropathologically by a limited main lesion to the cerebellar cortex and inferior olivary nucleus. To elucidate the features of lesions in the cerebellar cortex and inferior olivary nucleus, four autopsy cases suffering from idiopathic LCCA without other cortical cerebellar atrophies, such as alcoholic cerebellar degeneration, phenytoin intoxication, or hereditary cerebellar atrophy including spinocerebellar ataxia type 6, were examined. All affected patients had identical distinct features of cerebellar cortical lesions. In all four cases, the most obvious pathological finding throughout the cerebellum was loss of Purkinje cells, but the rarefaction of granular cell layers was observed only where loss of Purkinje cells was very severe, and thinning of the molecular layer was seen only where the rarefaction of granular cell layers was moderate to severe. Two patients presented with vermis dominant cerebellar cortical lesions, but the other two patients showed hemispheric dominant pathological changes. Neuronal loss of the inferior olivary nucleus was observed in the three autopsy cases. Two of the three cases had a prominent lesion in the dorsal part of the inferior olive and the cerebellar cortical lesion disclosed the vermis dominance, but the other patient, showing prominent neuronal loss in the ventral olivary nucleus, had a cerebellar hemisphere dominant lesion. The patient without neuronal loss in the inferior olivary nucleus had suffered from a shorter period of disease than the others and the rarefaction of granular cell

layers and narrowing of the molecular layer of the cerebellar cortex were mild. Therefore, it is obvious that there are two types of cerebellar cortex lesions in idiopathic LCCA; one is vermis dominant and the other is cerebellar hemispheric dominant. The lesion of the inferior olivary nucleus occurs as a secondary degeneration after rarefaction of the granular cell layer and thinning of the molecular layer of the cerebellar cortex progresses. Furthermore, the distribution of the degeneration in the inferior olivary nucleus depends on the distribution of the cerebellar cortex lesions.

Key words: granular cell, idiopathic late cortical cerebellar atrophy, inferior olivary nucleus, molecular layer, Purkinje cell.

INTRODUCTION

Late cortical cerebellar atrophy (LCCA) is a non-hereditary spinocerebellar degeneration and the first autopsy case of LCCA was reported by Archambault in 1918.¹ Marie *et al.* established foundation of the concept for LCCA by investigating four patients in 1922.² Since then, LCCA has been considered as a disease entity that develops cerebellar cortical lesions mainly in the cerebellar vermis. In 1975, Mancall regarded LCCA as a symptomatic disease and classified it into six categories.³ However, some patients with LCCA of unknown cause have been reported.^{4–6} There are not many autopsy cases of LCCA and only eight cases have been reported in Japan.^{4–9} In four of these cases, the distributions of the lesion were cerebellar hemispheric dominance^{5–8} and they did not necessarily correspond to the distribution suggested by Marie *et al.*⁶ Furthermore, there is a possibility that some patients reported as idiopathic LCCA could be spinocerebellar ataxia type 6 (SCA6).¹⁰ Therefore, a collective view on the distribution of idiopathic LCCA has not been established

Correspondence: Satoru Ota, MD, Department of Neurology, Tokyo Metropolitan Matsuzawa Hospital, 2-1-1, Kamikitazawa, Setagaya-ku, Tokyo 156-0057, Japan. Email: s-ohata@matsuzawa-hp.metro.tokyo.jp
Received 7 February 2007; revised 13 June 2007 and accepted 16 June 2007.

yet. Archambault regarded the pathological lesion of the inferior olivary nucleus as a secondary change,¹ but this also remains uncertain. In this study, the distribution and features of the cerebellar cortex lesion and degeneration of the inferior olivary nucleus were investigated in four cases in which SCA6 was denied by genetic screening.

MATERIALS AND METHODS

Four patients who did not have family histories relating to cerebellar disorders, previous histories of excessive alcohol consumption, anticonvulsant medications or thyroid disorder, were involved in this study. Their prominent symptom was slowly progressive cerebellar ataxia and the most conspicuous lesion was neuropathologically confined to the cerebellar cortex and inferior olivary nucleus. Neuropathological examination revealed no inclusions such as glial cytoplasmic inclusion in all four cases. Genetic tests were performed with approval from the patients or their guardians, and the patients proved negative for SCA6. They were clinically diagnosed as having idiopathic LCCA from these findings. Their clinical courses of disease are as follows.

Case 1

Schizophrenic disorder began at about the age of 26 years and the patient had received multiple neuroleptics including haloperidol and butyrophenone since he was 31 years old. At 32 years, the frequency of falls caused by gait disorder, the exact onset of which was not determined, had increased and he was admitted to our hospital. On admission, cerebellar limb ataxia, severe ataxic gait and dysarthria were observed, while motility function of the upper extremities was relatively better preserved. Gait disorder developed and he had difficulty in walking unaided at age 33. He was confined to his bed for a long time from the age of 38 and died of respiratory failure from pneumonia at age 42.

Case 2

A 57-year-old man developed dysarthria and sometimes had falls following a 3-year history of gait disturbance. At 59 years, tremor of the head and upper extremities appeared and dysgraphia became prominent. He had been able to walk by himself until the age of 77. However, he had to be hospitalized because of increased falls from the age of about 78 years. On admission, cerebellar limb ataxia, horizontal fixation nystagmus and coarse tremor of the upper extremities and head were observed. It was no longer possible for him to walk at the age of 79 and he died of pneumonia aged 80.

Case 3

This patient was reported by Tsuchiya *et al.* in 1994.⁶ His neurological symptoms began with gait disturbance at the age of 74 and progressed gradually. At 76 years of age, dysarthria, cerebellar limb ataxia and ataxic gait were observed and it was necessary for him to be assisted while walking. He had suffered hypoglycemic attacks due to diabetic medicine since he was 78. He died of pneumonia at age 81.

Case 4

This patient experienced stagger when he went down stairs as the first subjective symptom at the age of 55 and it became difficult for him to button up his clothes due to tremulous hands. Slow speech and gait disorder progressed gradually. At the age of 64, he had subdural hemorrhage and subarachnoid hematoma from trauma, and became irritable. He started behaving violently toward his wife and was admitted to hospital at age 65 years. He was confined to bed and developed dysphagia caused by psychotropic agents at the hospital. He died of pneumonia at 66 years.

Neuropathological examination

The lesions of the cerebellar cortices were assessed by HE-stained specimen. Each degree of Purkinje cell loss, rarefaction of granular cell layer and narrowing of the molecular layer was determined semiquantitatively using sagittal sections through the vermis, the pars intermedia of the hemisphere, the hemisphere through the dentate nucleus or the lateral part of the hemisphere. The following standard was used for the assessment. The severity of Purkinje cell loss was as follows: +, approximately greater than 50% of Purkinje cells were spared; ++, a few cells per cerebellar folia were observed; +++, Purkinje cells disappeared completely. The levels of granular cell loss were: +, mild; ++, moderate; +++, severe. The levels of narrowing of the molecular layer were: +, slight narrowing; ++, prominent narrowing.

The common features of the cerebellar cortex lesions in all patients studied were as follows: (i) the most severe pathological change throughout the cerebellum was Purkinje cell loss; (ii) in some parts granular cells and the molecular layer were preserved although Purkinje cells disappeared completely; (iii) granular cell loss was observed only where Purkinje cell loss was severe and narrowing of the molecular layer was seen only where granular cell loss was moderate to severe; and (iv) the cerebellar cortical lesions tended to be more striking in the crests than in the depths of the folia. Particularly, there were quite a few cerebellar folia which had a big gap in the levels of granular cell loss between the crest and the depth.

Table 1 Degree of the cerebellar cortical lesions

	Purkinje cells	Granular cell layers	Molecular layers
Grade 1	+~+++	-	-
Grade 2	+++	+	-
Grade 3	+++	++	+~+++
Grade 4	+++	+++	++

Purkinje cells: + minimal or slight neuronal loss, ++ prominent neuronal loss, +++ absent. Granular cell layers: - normal, + slight rarefaction, ++ moderate rarefaction, +++ prominent rarefaction. Molecular layers: - normal, + slight narrowing, ++ prominent narrowing.

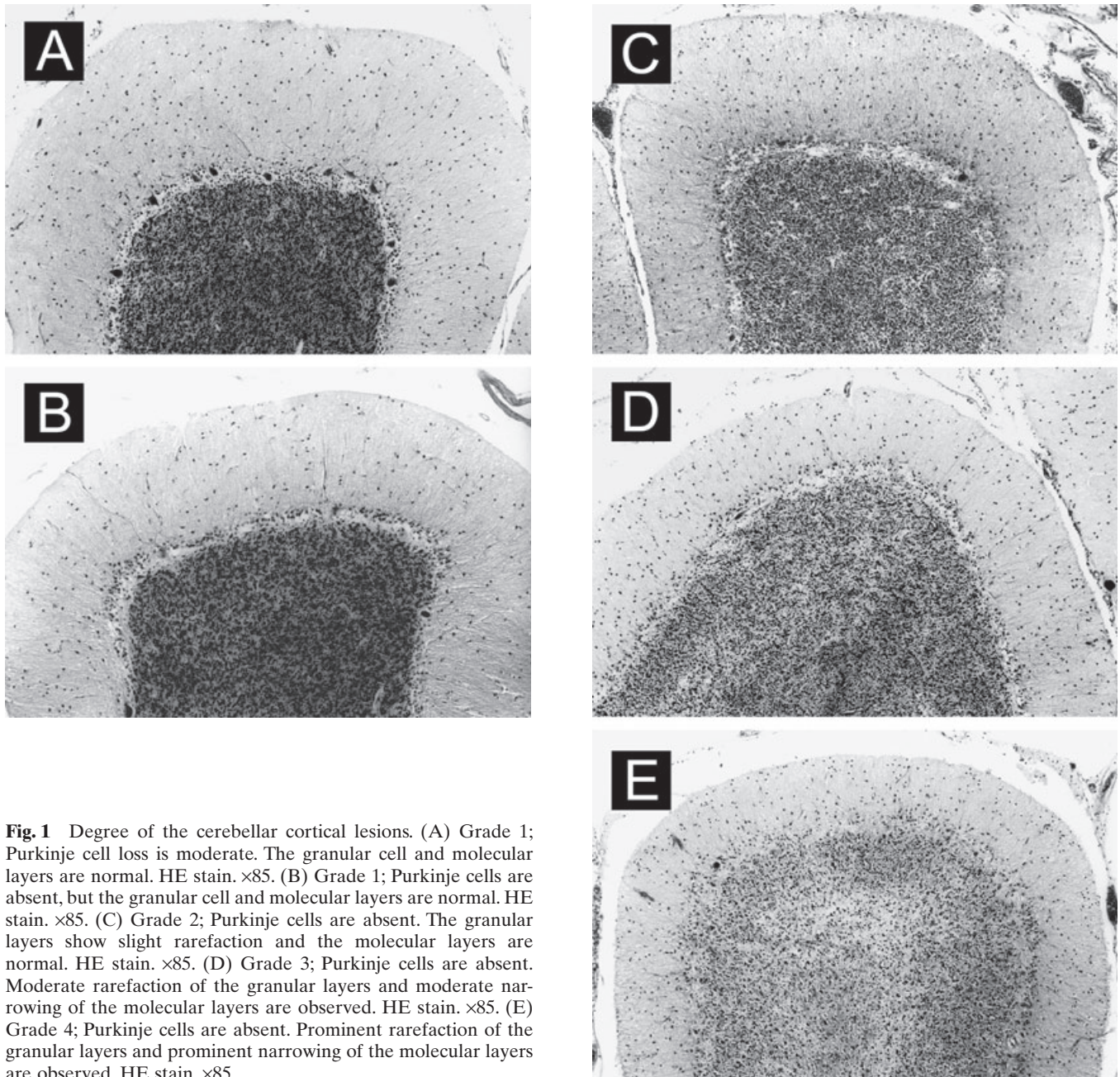


Fig. 1 Degree of the cerebellar cortical lesions. (A) Grade 1; Purkinje cell loss is moderate. The granular cell and molecular layers are normal. HE stain. $\times 85$. (B) Grade 1; Purkinje cells are absent, but the granular cell and molecular layers are normal. HE stain. $\times 85$. (C) Grade 2; Purkinje cells are absent. The granular layers show slight rarefaction and the molecular layers are normal. HE stain. $\times 85$. (D) Grade 3; Purkinje cells are absent. Moderate rarefaction of the granular layers and moderate narrowing of the molecular layers are observed. HE stain. $\times 85$. (E) Grade 4; Purkinje cells are absent. Prominent rarefaction of the granular layers and prominent narrowing of the molecular layers are observed. HE stain. $\times 85$.

Table 2 Comparison with the most extensive cerebellar cortical lesion in each sagittal sections

	Case 1	Case 2	Case 3	Case 4
Cerebellar vermis				
Culmen	G 3–4 (G3 > G4)	G 3–4 (G4 > G3)	G 1–2 (G1 > G2)	G 1–2 (G1 = G2)
Cerebellar hemisphere				
Pars intermedia	N.E.	G 2–4	G 1–3	NE
AQL		(G4 > G3 > G2)	(G2 > G1 = G3)	
Dentate nucleus				
PQL	G 2–4 (G2 > G3 = G4)	G 2–4 (G3 > G4 > G2)	G 1–3 (G2 > G1 = G3)	G 1–3 (G3 > G1 = G2)
Lateral part				
SSL	G 1–2 (G1 = G2)	G 2–4 (G3 > G2 = G4)	G 2–3 (G2 > G3)	G 2–3 (G3 > G2)

AQL, anterior quadrangular lobule; NE, not examined; PQL, posterior quadrangular lobule; SSL, superior semilunar lobule. G, Grade; G1–2, cerebellar lesion is composed of Grade 1 and 2; G1–3, cerebellar lesion is composed of Grade 1, 2, and 3; G2–3, cerebellar lesion is composed of Grade 2 and 3; G2–4, cerebellar lesion is composed of Grade 2, 3, and 4; G3–4, cerebellar lesion is composed of Grade 3 and 4; G3 > G4, the portion of Grade 3 is larger than that of Grade 4; G4 > G3, the portion of Grade 4 is larger than that of Grade 3; G1 > G2, the portion of Grade 1 is larger than that of Grade 2; G1 = G2, cerebellar lesion is composed of half Grade 1 and half Grade 2; G4 > G3 > G2, the portion of Grade 4 is larger than that of Grade 3, furthermore the portion of Grade 3 is larger than that of Grade 2; G2 > G1 = G3, cerebellar lesion is mainly composed of Grade 2, but the small portion is composed of Grade 1 and 3 equally; G2 > G3 = G4, cerebellar lesion is mainly composed of Grade 2, but the small portion is composed of Grade 3 and 4 equally; G3 > G4 > G2, the portion of Grade 3 is larger than that of Grade 4, furthermore the portion of Grade 4 is larger than that of Grade 2; G3 > G1 = G2, cerebellar lesion is mainly composed of Grade 3, but the small portion is composed of Grade 1 and 2 equally; G3 > G2 = G4, cerebellar lesion is mainly composed of Grade 3, but the small portion is composed of Grade 1 and 2 equally; G3 > G2, the portion of Grade 3 is larger than that of Grade 2.

We classified the lesions of the cerebellar cortex into four grades (Table 1, Fig. 1A,B (Grade 1), C (Grade 2), D (Grade 3), E (Grade 4)) based on our pathological features mentioned above (i–iv) and investigated the distribution of lesions on idiopathic LCCA based on the degree of the crest of cerebellar folia degeneration using four sagittal sections.

RESULTS

It has been reported that the neuropathology of idiopathic LCCA shows cerebellar cortical degeneration where the pathological change is more marked in surface cerebellar folia than in deeper folia and is more pronounced in the crests of the folia than the depths of the folia.² These were observed commonly in our four patients assessed in this study. In addition, further commonly observed features among these four cases were as follows. The vermis lesion was more severe in the anterior parts of the horizontal fissure (particularly the culmen) than posterior parts or the lower face of the cerebellum. The section through the pars intermedia of the cerebellar hemisphere showed more severe lesions in anterior parts of the primary fissure, especially in the quadrangular lobule, than in posterior parts or the lower face of the cerebellum. The section through the dentate nucleus revealed that the front portion of the primary fissure had more severe lesions, particularly in the quadrangular lobule, compared to the posterior region or lower face of the cerebellum. In the lateral part of the cerebellar hemi-

sphere, the lesion in the anterior portion of the horizontal fissure (superior semilunar lobule) was as severe as or worse than the lower face of the cerebellum. Thus each section generally showed that the lesion of the upper face of the cerebellum was more severe than that of the lower face of the cerebellum. However, there were relatively severe lesions in the pyramis vermis and inferior semilunar lobule for all cases. Therefore, it is not the case that the lesion of the lower face of the cerebellum is always mild.

Table 2 shows the lobules where the most severe degenerations common to four patients were observed in four sagittal sections and the level of the lesions, respectively. For cases 1 and 2, the most severe part of the lesion in the vermis was the culmen, which was Grades 3–4. The dominant levels of degeneration of case 1 (G3 > G4) and case 2 (G4 > G3) were Grades 3 and 4, respectively (Table 2). In the lesion of the cerebellar hemisphere, the level of case 1 was Grades 1–4, mainly Grade 2, and that of case 2 was Grades 2–4, mainly Grade 3. It became milder toward the lateral part of the cerebellar hemisphere in both cases. For cases 3 and 4, the lesions of the culmen in the vermis were Grade 1–2. On the other hand, those of the cerebellar hemisphere were Grades 1–3, and in cases 3 (pars intermedia and dentate nucleus, G2 > G1 = G3; lateral part, G2 > G3) and 4 (dentate nucleus, G3 > G1 = G2; lateral part, G3 > G2) were Grades 2 and 3, respectively (Table 2). In these cases, the degeneration became more severe toward the lateral part of the cerebellar hemisphere (Table 2).

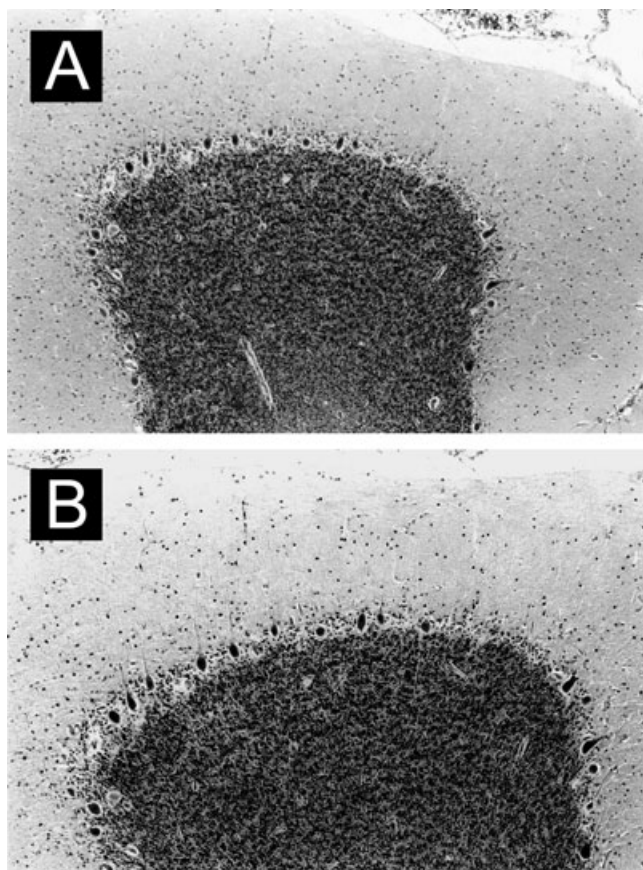


Fig. 2 Cerebellar tonsilla. Purkinje cells are well preserved and the granular and molecular layers are normal (A; case 2, B; case 3). HE stain. $\times 85$.

The pyramis for the lower face of the vermis and the inferior semilunar lobule for the lower face of the cerebellar hemisphere had the same or more severe lesions compared with other lobules. The lesion distribution indicated a similar tendency to that of the upper face of the cerebellum. For all cases, the lesions of the uvula in the vermis and the tonsil in the cerebellar hemisphere were minimal (Fig. 2A,B). There was no band-like structure around residual Purkinje cells, which is observed in chromosome 16-linked autosomal dominant inherited cerebellar cortical degeneration.¹¹

The inferior olivary nucleus was normal in only case 3 (Fig. 3) and the others showed distinct neuronal loss. For cases 1 and 2, the dorsomedial part of the inferior olive, including accessory olivary nuclei, showed more serious lesions (Figs 4,5A–C). However, the pathological findings for case 4 showed that accessory olivary nuclei were relatively preserved and the ventral principal olivary nucleus had severe lesions (Fig. 6A–C). The clinicopathological findings are summarized in Table 3.

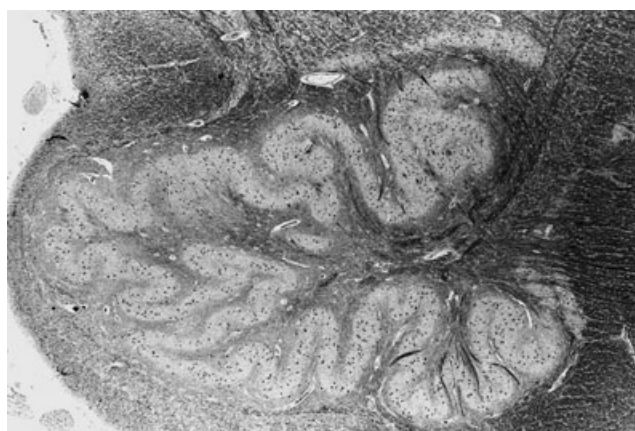


Fig. 3 Neuronal density is normal in the inferior olivary complex of case 3. HE stain. $\times 18$.

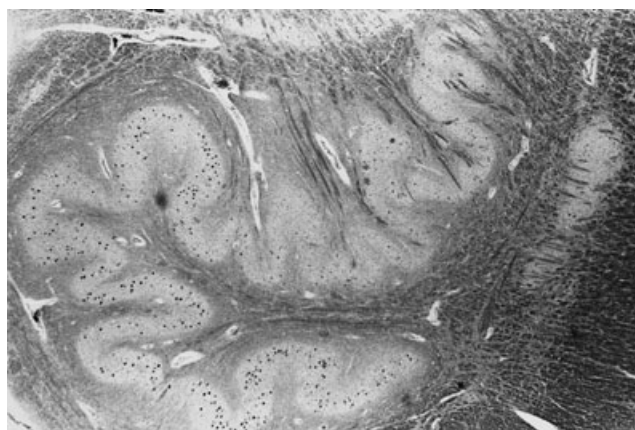


Fig. 4 Inferior olivary nucleus of case 1. Neuronal loss in the dorsomedial portion of the principal olivary nucleus, and in the dorsal and medial accessory olivary nucleus are observed. The neurons in the dorsolateral and ventral part of the principal olivary nucleus are almost normal in number. HE stain. $\times 24$.

DISCUSSION

The four cases that we investigated here were negative for SCA6 by genetic screening and there was also less possibility of chromosome 16q-linked autosomal dominant inherited cerebellar cortical degeneration because no band-like structure around residual Purkinje cells¹¹ was observed. Among four cases, case 1 was unique in that he underwent treatment for schizophrenia, but there was no history that he developed a neuroleptic malignant syndrome. Moreover, severe degeneration of the cerebellar white matter accompanied by macrophages and cerebellar dentate nucleus, which are consistent with the neuropathological findings of neuroleptic malignant syndrome, were not recognized in case 1. This neuropathological finding differs from those described in neuroleptic malignant syndrome.¹² A diagnosis of idiopathic LCCA would be appropriate in this study

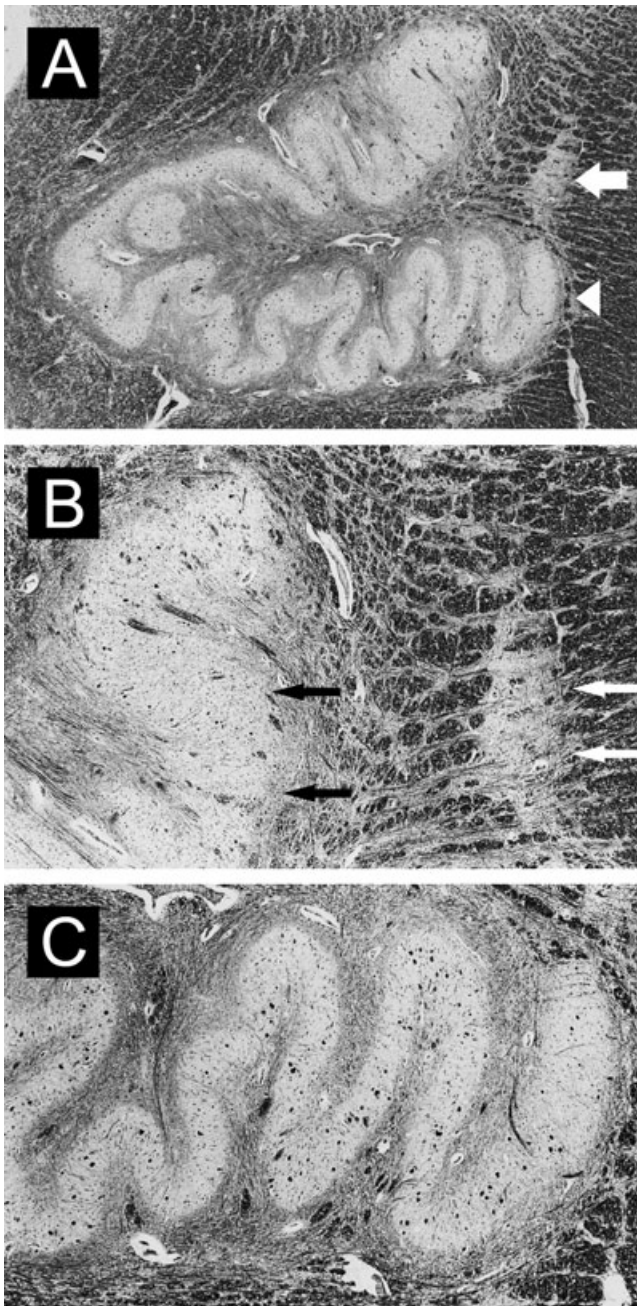


Fig. 5 Inferior olivary nucleus of case 2 (B; enlargement of the arrowed area in A. C; enlargement of the arrow-head area in A). Inferior olivary complex showing obvious neuronal loss (A; HE stain. $\times 21$), predominantly in the dorsomedial portion of the principal olivary nucleus (B; black arrow, HE stain. $\times 54$) and the accessory olivary nucleus (B; white arrow, HE stain. $\times 54$), compared with the ventral portion of the principal olivary nucleus (C; HE stain. $\times 54$).

although further classification may be possible in the future. Concerning distributions of the cerebellar cortical lesion of cases 1 and 2, the vermis lesion was dominant in both the upper and lower faces of the cerebellum, while degeneration of the cerebellar hemisphere was more conspicuous in

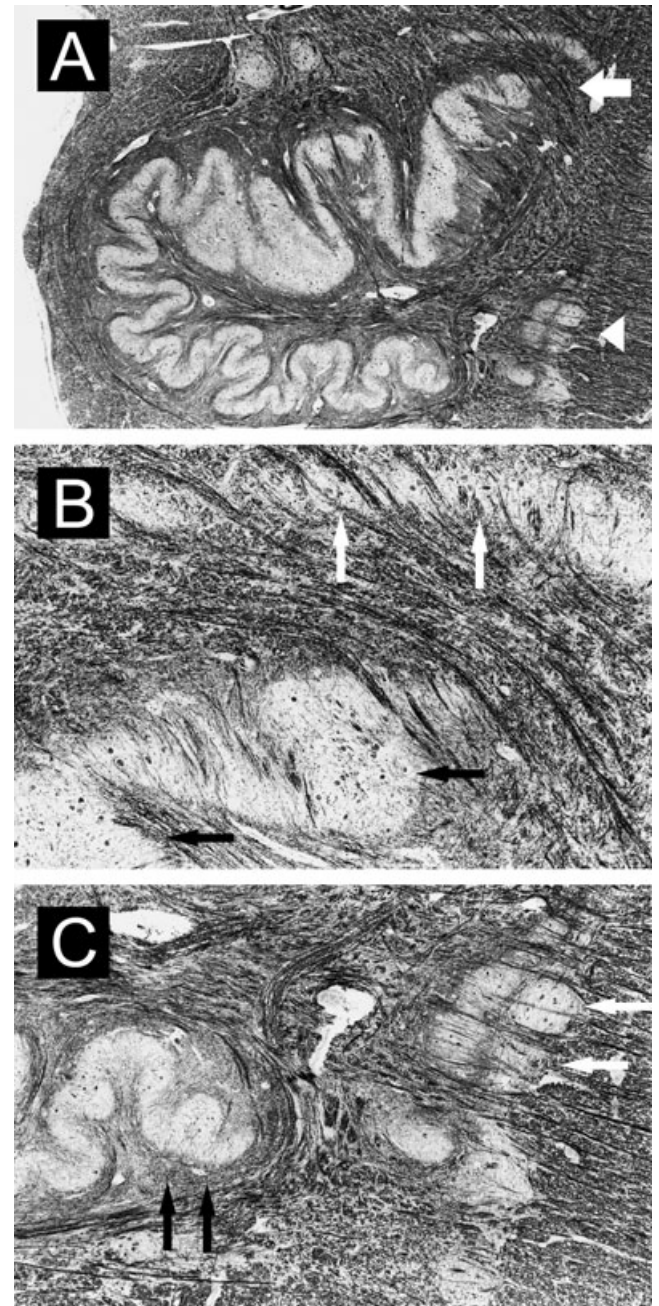


Fig. 6 Inferior olivary nucleus of case 4 (B; enlargement of the arrowed area in A. C; enlargement of the arrow-head area in A). Inferior olivary complex showing evident neuronal loss (A; HE stain. $\times 18$), particularly in the ventral portion of the principal olivary nucleus (C; black arrow, HE stain. $\times 36$), compared with the dorsomedial portion of the principal olivary nucleus (B; black arrow, HE stain. $\times 85$) and the accessory olivary nucleus (B, C; white arrow).

cases 3 and 4 (Table 2). Our findings indicate that there are two types of cerebellar cortical lesion in idiopathic LCCA the same as SCA6,¹³⁻¹⁶ one is vermis dominant and the other is hemispheric dominant, although only a small number of cases were examined in this study. Although the same result

Table 3 Summary of clinicopathological findings

	Case 1	Case 2	Case 3	Case 4
Age at onset (years)	unknown	54	74	55
Age at death (years)	42	80	82	66
Disease duration (years)	more than 10	26	8	11
Cerebellar cortical lesions				
Purkinje cell layers	Severe	Severe	Severe	Severe
Granular cell layers	Moderate	Severe	Slight	Moderate
Molecular layers	Moderate	Severe	Slight	Moderate
Distribution	V > H	V > H	V < H	V < H
Inferior olivary nucleus				
Distribution	Do > Ve	Do > Ve	normal	Do < Ve

Do, dorsal portion; H, hemisphere; V, vermis; Ve, ventral portion.

is reported in SCA6,^{13–16} there have been no reports in which cerebellar cortical lesions in idiopathic LCCA, without genetic diseases such as SCA6, were investigated in detail based on a particular histopathological standard. Therefore, this is the first report to objectively show the diversity of the cerebellar cortical lesion in idiopathic LCCA. According to the neuropathological features of these four cases, it seems that the cerebellar cortical lesion progresses from Purkinje cell loss to narrowing of the molecular layer through granular cell loss. However, it was difficult to distinguish clinically the diversity of distributions of the cerebellar cortical lesion, because the patients' idiopathic LCCA had already progressed to a certain level; Purkinje cell loss, in particular, may already have occurred diffusely by the time they consult a medical specialist. Thus the differentiation has to be made through their medical history alone. Generally, gait disorder as the prominent symptom of idiopathic LCCA cannot be relied on for differential diagnosis of having a vermis dominant lesion and hemisphere dominant lesion, because it is difficult to determine by only clinical history whether gait disorder is caused by ataxia in the lower extremities or truncal ataxia. However, when movement disorder in the upper extremities occurs early, like in our case 4, the cerebellar cortical lesion may be more severe in the hemisphere than in vermis.^{7,8} Therefore, the time of appearance of symptoms in the upper extremities seems to be very important in clinical differentiation of the lesion distribution pattern in the cerebellar cortex.

The relationship between the cerebellar cortical lesion and the lesion of the inferior olivary nucleus was remarkable in the four cases in this study. For cases 1 and 2, which were vermis dominant in the cerebellar cortical lesion, neuronal loss was severe in the dorsomedial part of the inferior olive including the accessory olivary nuclei. On the other hand, for case 4, which was hemispheric dominant in the cerebellar cortical lesion, the ventral part of the inferior olive had severe neuronal loss. This relationship of lesion distribution between the cerebellar cortex and the inferior olive had already been reported in previous cases of LCCA^{5,7,8} and SCA6,^{13,15} and correlates with olivocerebellar

tract fibers.¹⁷ It suggests that there is some relationship between the cerebellar cortical lesion and lesion of the inferior olive. Furthermore, in case 2 with lesions of Grade 3 or more throughout the cerebellar cortical lesion, the neuronal loss in the inferior olive was more conspicuous. Case 1 showed obvious lesions of Grade 3 or more in the cerebellar vermis and significant neuronal loss in accessory olivary nuclei and the dorsomedial part of the principal olivary nucleus. In contrast, in case 3, which did not show distinct neuronal loss in the inferior olivary nucleus, the duration of illness was shorter than in other cases, the granular cell loss and narrowing of the molecular layer was mild and there were few lesions belonging to Grade 3 or more. These findings suggest that the lesion of the inferior olivary nucleus is related to the level of cerebellar cortical lesion, especially changes of the granular cell and molecular layer and to the period of suffering from the disease as well as SCA6.¹⁸ As mentioned above, our study disclosed that cerebello-olivary degeneration of idiopathic LCCA has a striking resemblance to that of SCA6.^{13–16} Thus, it seemed to be difficult to discriminate idiopathic LCCA from SCA6 pathologically.

In conclusion, the distribution pattern of the cerebellar cortical lesion in idiopathic LCCA is diverse and it would appear that idiopathic LCCA starts from degeneration of the Purkinje cell and progresses to granular cell loss and narrowing of the molecular layer in the cerebellar cortex. The neuronal loss in the inferior olivary nucleus occurs as a secondary phenomenon in patients after the degeneration of granular cells and the molecular layer becomes moderate or severe. Furthermore, the distribution of neuronal loss in the inferior olivary nucleus depends on that of the cerebellar cortical lesions.

ACKNOWLEDGMENTS

The authors are grateful to Dr K. Ishikawa and Dr H. Mizusawa from the Departments of Neurology and Neurological Science, Graduate School, Tokyo Medical and Dental University, Tokyo, for gene examination.

REFERENCES

1. Archambault LS. Parenchymatous atrophy of the cerebellum. *J Nerv Ment Dis* 1918; **48**: 273–312.
2. Marie P, Foix CH, Alajouanine TH. De l'atrophie cerebelleuse tardive a predominance corticale. *Rev Neurol (Paris)* 1922; **29**: 849–885, 1082–1111.
3. Mancall EL. Late (acquired) cortical cerebellar atrophy. In: Vinken PJ, Bruyn GW, eds. *Handbook of Clinical Neurology*, Vol. 21. Amsterdam: North-Holland, 1975; 477–508.
4. Iwabuchi K, Yagishita S. An autopsied case of idiopathic late cortical cerebellar atrophy – Comparison with other cortical cerebellar atrophy (in Japanese with English abstract). *Rinsho Shinkeigaku* 1990; **30**: 1190–1196.
5. Yoshioka A, Arizono N, Tsujimoto Y, Ukita G, Ashihara T. An autopsy case of late cortical cerebellar atrophy associated with degeneration of the optic nerve and spinal cord (in Japanese with English abstract). *Pathol Clin Med* 1983; **1**: 773–779.
6. Tsuchiya K, Ozawa E, Saito F, Irie H, Mizutani T. Neuropathology of late cortical cerebellar atrophy in Japan: distribution of cerebellar change on an autopsy case and review of Japanese cases. *Eur Neurol* 1994; **34**: 253–262.
7. Fukuda K, Sakamoto R, Nemoto S, Kondo S, Maeda S. An autopsied case of the diffuse primary cerebellar cortical atrophy of Purkinje cell type (in Japanese with English abstract). *Rinsho Shinkeigaku* 1963; **3**: 214–218.
8. Mannen T, Tsubaki T, Nakamura H, Kameyama M. Three cases of the cerebellar atrophy (in Japanese with English abstract). *Rinsho Shinkeigaku* 1966; **6**: 111–119.
9. Kameyama M. Cerebellar degeneration- Two autopsied cases (in Japanese with English abstract). *Nippon Rinsho* 1970; **28**: 540–545.
10. Abele M, Burk K, Schols L *et al.* The aetiology of sporadic adult-onset ataxia. *Brain* 2002; **125**: 961–968.
11. Owada K, Ishikawa K, Toru S *et al.* A clinical, genetic, and neuropathologic study in a family with 16q-linked ADCA type III. *Neurology* 2005; **65**: 629–632.
12. Lee S, Merriam A, Kim T-S, Liebling M, Dickson DW, Moore GRW. Cerebellar degeneration in neuroleptic malignant syndrome: neuropathologic findings and review of the literature concerning heat-related nervous system injury. *J Neurol Neurosurg Psychiatry* 1989; **52**: 387–391.
13. Ishikawa K, Watanabe M, Yoshizawa K *et al.* Clinical, neuropathological, and molecular study in two families with spinocerebellar ataxia type 6 (SCA6). *J Neurol Neurosurg Psychiatry* 1999; **67**: 86–89.
14. Tashiro H, Suzuki SO, Hitotsumatsu T, Iwaki T. An autopsy case of spinocerebellar ataxia type 6 with mental symptoms of schizophrenia. *Clin Neuropathol* 1999; **18**: 198–204.
15. Gomez CM, Thompson RM, Gammack JT *et al.* Spinocerebellar ataxia type 6: Gaze-evoked and vertical nystagmus, Purkinje cell degeneration, and variable age of onset. *Ann Neurol* 1997; **42**: 933–950.
16. Sasaki H, Kojima H, Yabe I *et al.* Neuropathological and molecular studies of spinocerebellar ataxia 6 (SCA6). *Acta Neuropathol* 1998; **95**: 199–204.
17. Holmes G, Stewart TG. On the connection of the inferior olives with the cerebellum in man. *Brain* 1908; **31**: 125–137.
18. Tsuchiya K, Oda T, Yoshida M *et al.* Degeneration of the inferior olive in spinocerebellar ataxia 6 may depend on disease duration: Report of two autopsy cases and statistical analysis of autopsy cases reported to date. *Neuropathology* 2005; **25**: 125–135.