

Letters to the Editor Related to New Topics

Reversible Chorea in Association with Graves' Disease and Moyamoya Syndrome

Hyperthyroidism and moyamoya syndrome (MMS) are rare causes of chorea.¹ Here, we report a patient who had chorea associated with both conditions.

A 19-year-old woman from Ivory Coast was admitted because of movement disorder. There was no family history of neurological diseases. The patient had been diagnosed with Graves' disease at age 18 and had since showed poor compliance with carbimazole therapy. Upon admission, free thyroxine level was more than 100 pmol/L (range 12–23), thyroid stimulating hormone was undetectable (less than 0.001 mUI/L, range 0.3–4.4), and thyroid stimulating antibodies were positive: 21.1 UI/L. About 2 weeks before admission, she had progressively developed movement disorder, balance impairment, and dysarthria. On examination, the patient had a diffuse goiter and typical signs of thyrotoxicosis, including warm, moist skin, and tachycardia. She had mild and diffuse choreic movements, predominating in the facial area. Movements involved symmetrically both upper limbs, mainly in sustained posture. The patient had mild dysarthria and tandem walk was impaired. Mild slowing of alternating movements of both hands was present. Neurological examination was otherwise normal. Routine blood count, electrolytes, urea, creatinine, liver function panel, were all normal. Autoantibody screen was negative for anticardiolipids, lupus anticoagulant, Antibeta2GPI, antinuclear antibody, and anti dsDNA antibody. Brain magnetic resonance imaging (MRI) showed high signal intensity lesions on FLAIR and T2 sequences in the left anterior putamen and the head of the left caudate nucleus (Fig. 1). MR angiography showed severe stenosis of the extremity of the internal carotid arteries, at the origin of both middle cerebral arteries, as well as of the left anterior cerebral artery. Four-vessel cerebral angiography showed bilateral severe stenosis of the supraclinoid portion of the internal carotid arteries with MMS (Fig 2.). Treatment with carbimazole (20 mg/day) and levothyroxine (synthetic T4) 50 µg/day was resumed, in association with propranolol. Clinical signs of thyrotoxicosis and neurological symptoms subsided within a few weeks. Three months later, the patient had normal neurological examination and her thyroid tests results were normal. Because of poor observance, two relapses occurred in the following year, consisting of the reappearance of clinical signs of hyperthyroidism and chorea. Thyroidectomy was finally performed and the patient has since remained free of symptoms.

The association of hyperthyroidism and chorea has been reported in several patients.^{2–6} A causal relationship is likely, as

in some cases, chorea ceased when hyperthyroidism was corrected, and eventually reappeared as hyperthyroidism developed again.³ Although most cases involve Grave's disease, a few reports of chorea due to iatrogenic thyrotoxicosis have been published.⁷ The pathophysiology of hyperthyroidism-related chorea is poorly understood, which is not surprising in view of the wide range of metabolic pathways affected by thyroid hormones. Chorea is associated with complex dysfunction within the basal ganglia system. Hyperthyroidism could modify basal ganglia function through neurotransmitter alteration and (or) gene dysregulation. It has been suggested that thyroid hormones could functionally affect the dopaminergic system within the basal ganglia, possibly through an increased sensitivity of the dopaminergic receptors.³ However, thyroid hormones also play an important role in regulating central noradrenergic, serotonergic, and cholinergic systems, and complex interactions may occur.^{8,9} Furthermore, thyroid hormones also control gene expression in the nervous central system. Among thyroid hormones target genes, the *Rhes* (Ras homolog enriched in striatum) gene, which encodes a small GTP-binding protein, is of particular interest, as it is predominantly expressed in the striatum.¹⁰ Thyroid hormones also modify the expression of the transcriptional coactivator PGC-1, a protein which regulates metabolic pathways and biological processes in brain (and other tissues), especially in the striatum.¹¹ However, whether modified gene expression is involved in hyperthyroidism induced chorea remains speculative.

In the observation we report, the patient had two other potential causes of chorea, i.e., ischemic focal lesions of the basal ganglia and MMS. Focal lesions involving the caudate nucleus and (or) the putamen may be associated with chorea.¹² However, in this case, chorea is contralateral to the lesion and is not likely to have a relapsing-remitting course, as what was observed in our patient. MMS has also been associated with chorea.¹³ In this condition, related basal ganglia hypoperfusion could play a part in the genesis of choreic movement.^{14,15} Interestingly, the association of MMS and Grave's disease is probably not fortuitous, as several patients with this association have been previously reported. It has been hypothesized that both conditions may share a common autoimmune mechanism.¹⁵ In most of these cases, cerebrovascular accidents occurred when patients were thyrotoxic, suggesting that thyroid hormones could have facilitate these accidents, possibly through hemodynamic changes and (or) sympathetic nervous system-mediated vasculopathy.¹⁵

In the present case, the rapid improvement of the chorea after correction of the hyperthyroidism demonstrates that high levels of thyroid hormones were the main causative factor. However, we cannot rule out the possibility that MMS was a predisposing factor, although not sufficient by itself to trigger the chorea.

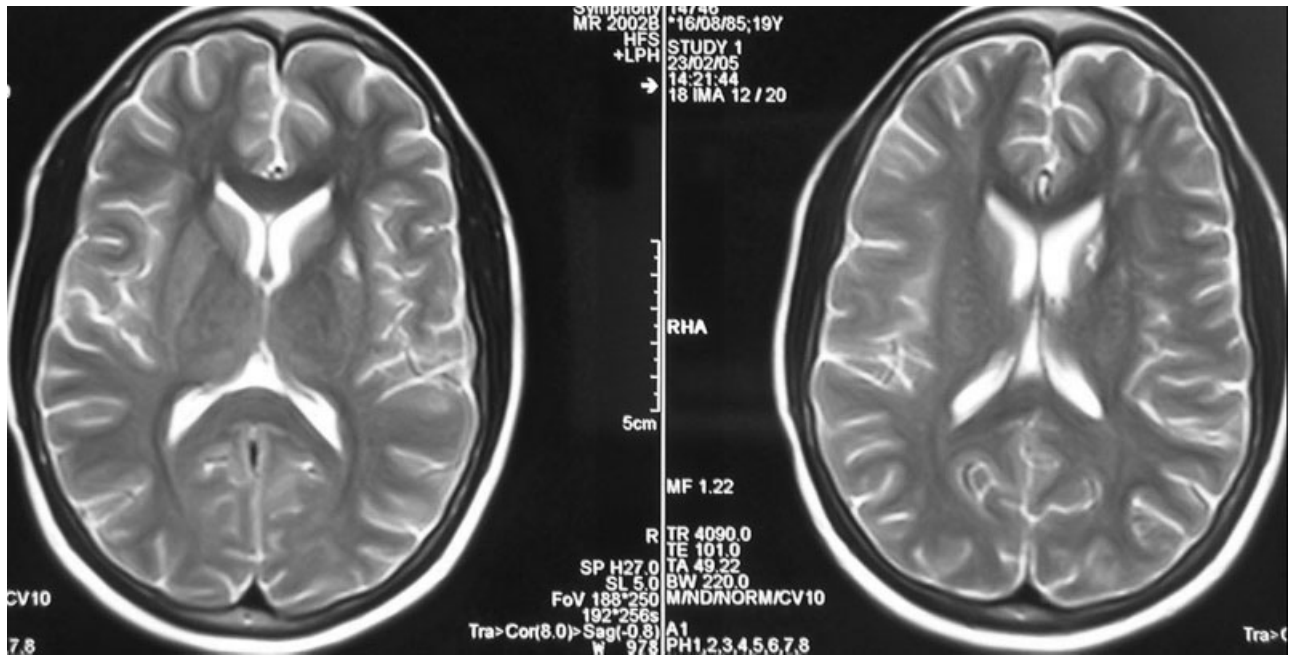


FIG. 1. Cerebral Axial T2 weighted MRI. Hyperintense lesion in the left caudate and lenticular nucleus.

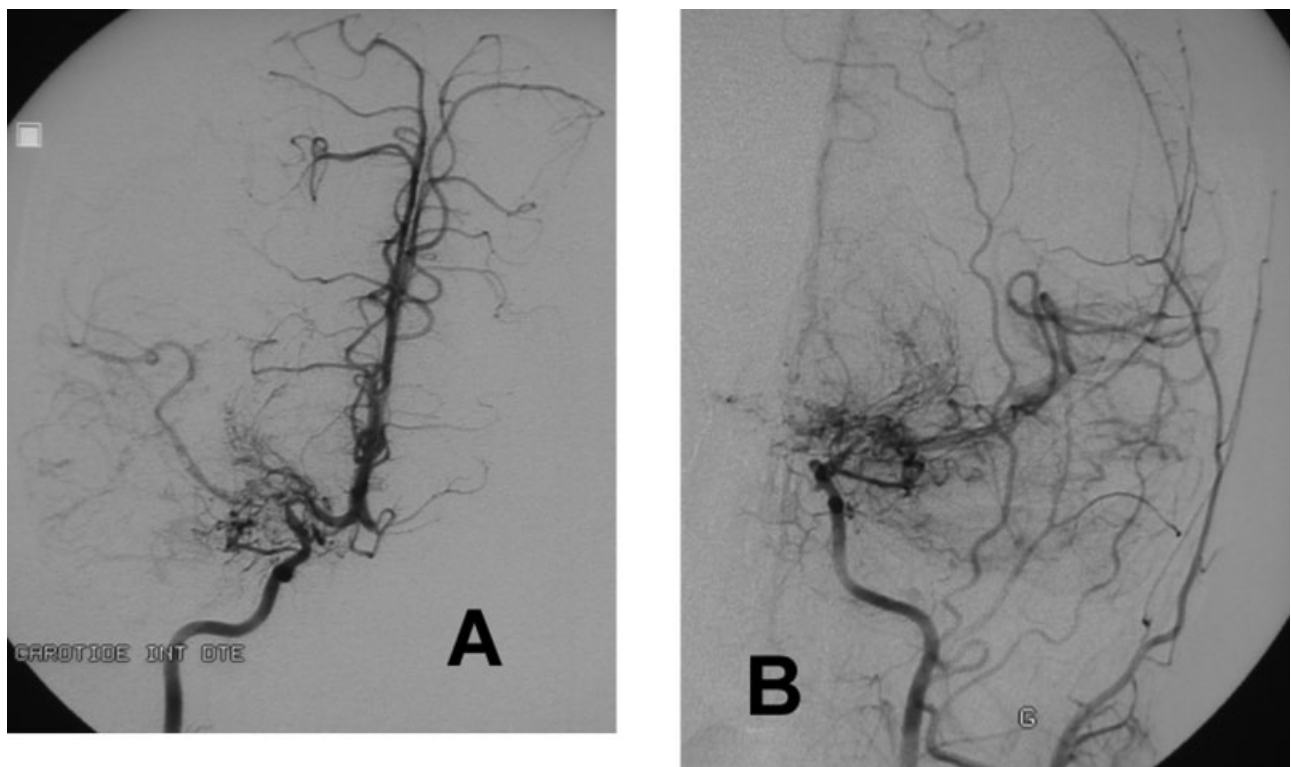


FIG. 2. Conventional right (A) and left (B) internal carotid artery angiogram. Frontal view. Extremely severe bilateral stenoses of the internal carotid bifurcation and M1 segments. Development of an important collateral circulation from the lenticulostriate arteries.

Acknowledgments: We thank Drs Z. Kahal and B. Mouchet for referring the patient, and Dr L. Freeman for writing assistance.

Béatrice Garcin, MD
*Department of Neurology
 AP-HP, Henri Mondor Hospital
 Créteil, France*

Taina Louissaint, MD
*Department of Internal Medicine
 AP-HP, Henri Mondor Hospital
 Créteil, France*

Hassan Hosseini, MD, PhD
*Department of Neurology
 AP-HP, Henri Mondor Hospital
 Créteil, France*

Raphaël Blanc, MD
*Department of Neuroradiology
 AP-HP, Henri Mondor Hospital
 Créteil, France*

Gilles Fénelon, MD, PhD*
*Department of Neurology
 AP-HP, Henri Mondor Hospital
 Créteil, France*

*E-mail: gilles.fenelon@hmn.aphp.fr

References

- Cardoso F, Seppi K, Mair KJ, et al. Seminar on choreas. *Lancet Neurol* 2006;5:589-602.
- Nagaoka T, Matsushita S, Nagai Y, Kobayashi K. A woman who trembled, then had chorea. *Lancet* 1998;351:1326.
- Ristić AJ, Svetel M, Dragašević N, et al. Bilateral chorea-ballism associated with hyperthyroidism. *Mov Disord* 2004;19:982-983.
- Heoffron W, Eaton RP. Thyrotoxicosis presenting as choreoathetosis. *Ann Intern Med* 1970;73:425-428.
- Fidler SM, O'Rourke RA, Buchsbaum HW. Choreoathetosis as a manifestation of thyrotoxicosis. *Neurology* 1971;21:55-57.
- Pozzan GB, Battistella PA, Rigon F, et al. Hyperthyroid-induced chorea in an adolescent girl. *Brain Dev* 1992;14:126-127.
- Isaacs JD, Rakshi J, Baker R, Brooks DJ, Warrens AN. Chorea associated with thyroxine replacement therapy. *Mov Disord* 2005;20:1656-1670.
- Bauer M, Heinz A, Whybrow PC. Thyroid hormones, serotonin and mood: of synergy and significance in the adult brain. *Mol Psychiatry* 2002;7:140-156.
- Smith JW, Evans AT, Costall B, Smythe JW. Thyroid hormones, brain function and cognition: a brief review. *Neurosci Biobehav Rev* 2002;26:45-60.
- Spano D, Branchi I, Rosica A, et al. Rhes is involved in striatal function. *Mol Cell Biol* 2004;24:5788-5796.
- Lin J, Handschin C, Spiegelman BM. Metabolic control through the PGC-1 family of transcription coactivators. *Cell Metab* 2005;1:361-370.
- Bhatia KP, Marsden CD. The behavioral and motor consequences of focal lesions of the basal ganglia in man. *Brain* 1994;117:859-876.
- Gonzalez-Alegre PG, Ammache Z, Davis PH, Rodnitzky RL. Moyamoya-induced paroxysmal dyskinesia. *Mov Disord* 2003;18:1051-1056.
- Hong YH, Ahn TB, Oh CW, et al. Hemichorea as an initial manifestation of moyamoya disease: reversible striatal hypoperfusion demonstrated on single photon emission computed tomography. *Mov Disord* 2002;17:1380-1383.
- Nakamura K, Yanaka K, Ihara S, Nose T. Multiple intracranial arterial stenoses around the circle of Willis in association with Graves' disease: report of two cases. *Neurosurgery* 2003;53:1210-1215.

Atypical Stereotypies and Vocal Tics in Rett Syndrome: An Illustrative Case

Video



Hand stereotypies are the signature sign of Rett syndrome (RTT) and their presence plays a key role in diagnosis.¹ We have found that hand movements, which may involve the hands together or apart, are very standardized in individual girls. We also found additional stereotypies (including vocal ones) that changed over time, not previously reported in RTT and we hypothesized the existence of tics in this disorder.¹

Most studies stress that stereotyped hand movements coincide with or follow the disappearance of purposeful prehension in RTT; however, more recently, different studies reported stereotypies as coinciding with or preceding the loss of purposeful hand movements in this disorder.¹⁻³ Thus we believe that the particularly compulsive stereotypies in patients with RTT are likely to contribute to loss or reduction of hand use.

We present the case of a girl with RTT with a very atypical presentation that illustrates the complexity of movement disorders and psychiatric symptoms that can be present in RTT and their probable interference in function.

In a center for autistic children a child psychiatrist noticed that one 6-year-old girl stood out from the majority of the other children in that she had intense eye contact.

This girl was the second child of an unrelated and healthy couple and her perinatal history was normal. Family history was unremarkable for tics, obsessive-compulsive symptoms, and neurologic or psychiatric problems. When she was born her occipital frontal circumference (OFC) was below the 5th percentile but increased progressively to 50 percentile by 6 months of age. She achieved head control at 3 months, grasped an object at 4 months, and had intentional prehension at 5 months. She walked unsupported and uttered her first words at 13 months. She never crawled.

She had a high pitched voice and echolalia. She spoke complex frequently coprolalic phrases and her vocabulary was notable for unusual words. She had some phobias and repetitive compulsive behaviors such as switching lights on and off and opening and closing drawers. She never acquired sphincter control.

At 4 years old she met DSM-IV⁴ diagnostic criteria for autistic disorder and developmental quotient (QD) evaluation

This article includes supplementary video clips, available online at <http://www.interscience.wiley.com/jpages/0885-3185/suppmat>.

Published online 16 January 2008 in Wiley InterScience (www.interscience.wiley.com). DOI: 10.1002/mds.21939