

Sporadic Multiple Cerebral Cavernomatosis

Report of a Case and Review of Literature

Arzu Coban, MD,* Candan Gurses, MD,* Bilge Bilgic, MD,† Serra Sencer, MD,‡ Aykut Karasu, MD,§
Nurses Bebek, MD,* Betul Baykan, MD,* Kemal T. Hepgul, MD,§ and Aysen Gokyigit, MD*

Objective: Cerebral cavernous malformations (CCM) are vascular malformations causing seizures and cerebral hemorrhages. They occur in sporadic and familial forms. Familial cases are associated with a high frequency of multiple lesions, which are less frequently associated with sporadic cases.

Case Report: We report a 46-year-old woman presenting with epilepsy with multiple cerebral cavernomatosis on MRI. Because she had had a previous liver transplantation operation, and received immunosuppressants, she was not advised to have a brain operation. However, she had to be operated as a result of a bleeding in one of her cerebral cavernomas. The histologic diagnosis was cavernoma. She has been seizure free after the operation with levetiracetam therapy for the last 17 months. She had no positive family history for both epilepsy and cavernomatosis.

Conclusion: When multiple cerebral cavernomatosis are identified in a patient, a detailed neurologic family history should be sought despite the possibility of its being a sporadic case. Our main intention is to present a patient who is surgically controversial and to point out the importance of genetic heredity.

Key Words: cavernoma, sporadic multiple malformation, liver transplantation, seizure, levetiracetam

(*The Neurologist* 2008;14: 46–49)

The typical appearance of cavernomas is heterogeneous "popcorn-like" lesions of different sizes with a mixed signal intensity core and a peripheral rim of hypointense signal intensity reflecting a zone of hemosiderin.

There are 4 major cerebral vascular malformations: cavernous angioma (cavernoma), parenchymal arteriovenous malformation, venous angioma, and capillary telangiectasia.¹ Cerebral cavernous malformations (CCM) are non-neoplastic congenital anomalies that present in a variety of clinical patterns, ranging from asymptomatic to fatal intracranial hemorrhage.² The prevalence of cavernomas has been estimated as 0.5% to 0.7% in the population.^{3,4} They are characterized by abnormally enlarged capillary cavities without intervening normal brain parenchyma or muscular tissue.^{5,6} Magnetic resonance imaging (MRI) is more sensitive than computed tomography (CT) for the detection of cavernomas.^{7,8} The typical appearance of cavernomas is heterogeneous "popcorn-like" lesions of different sizes with a mixed signal intensity core and a peripheral rim of hypointense signal intensity reflecting a zone of hemosiderin.^{7,8} A supratentorial location of lesions has been reported to be more frequent than an infratentorial location.^{9–13} In this report, we present a patient who had a history of liver transplantation with multiple cerebral cavernomatosis presenting with disturbances of consciousness and generalized seizures.

CASE REPORT

A 46-year-old woman presenting with vertigo, nausea, vomiting, and disturbances of consciousness due to a seizure attack at home was admitted to the Emergency Department of Neurology. After a seizure attack at home, she had a second generalized tonic-clonic seizure 3 hours after admission. Her CT scan showed hyperdense lesions in the right temporal, right parietal, and left frontal lobes (Fig. 1). These findings indicated that there was a hemorrhage with minimal mass effect. In the following week, while she was still in the hospital, she had her third seizure. After the seizure, her neurologic examination was unremarkable except for a postictal short period of confusion. She had a history of hepatitis B virus (HBV) infection 10 years ago. Liver transplantation was performed 2 years ago. Her brother had hepatic cirrhosis and her sister was a HBV transporter. She has used Cyclosporine 175 mg/d, Lamivudine 300 mg/d, Acyclovir 2400 mg/d, Acetylsalicylic acid 80 mg/d, and Omeprazole 40 mg/d. Physical examination revealed mild hepatomegaly and splenomegaly. Routine blood findings included a low platelet count (93,000/mm³), hemoglobin (9.7 gr/dL), hematocrit (28.6%), and leukocyte count (2800/mm³). The results of other laboratory tests (BUN, creatinine, AST, ALT, ALP, lipid profile, electrolytes, PT, PTT, and INR) and electroencephalography (EEG) examination were unremarkable. Her brain MRI, done a few days later, revealed subacute to chronic

From the Departments of *Neurology; †Pathology; ‡Radiology; and §Neurosurgery, Istanbul School of Medicine, University of Istanbul, Millet Cad, Çapa, TR-34390, Istanbul, Turkey.

Part of this study was presented as a poster presentation in V National Congress of Epilepsy (June 2006, Bursa, Turkey).

Reprints: Dr. Arzu Coban, Merdivenköy Mah. Nazenin Sok. Kadribey Ap. No. 23/9, Kadiköy, Istanbul 34732, Turkey. E-mail: arzucoban2002@yahoo.com.

Copyright © 2008 by Lippincott Williams & Wilkins

ISSN: 1074-7931/08/1401-0046

DOI: 10.1097/NRL.0b013e31813e343f

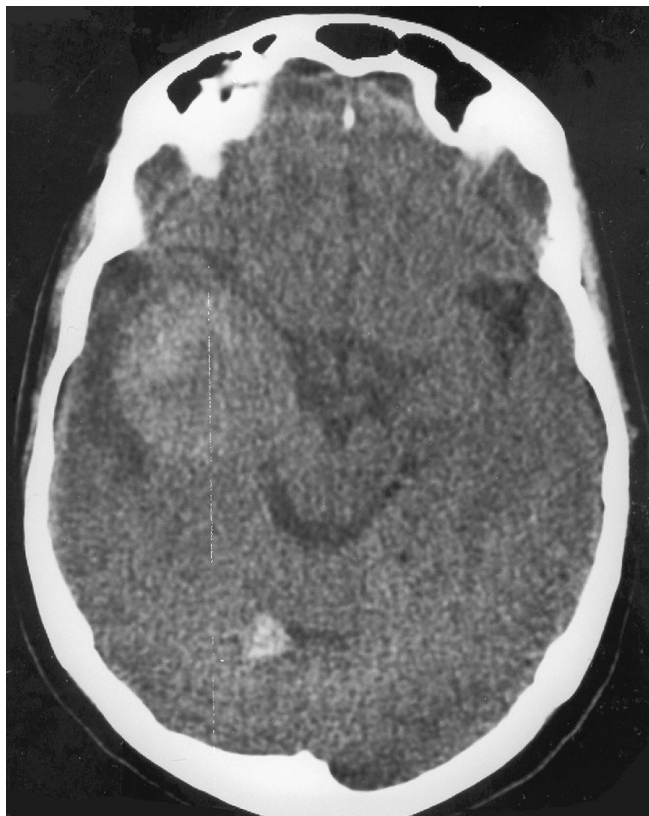

FIGURE 1. Diagnostic images of patient. Cranial CT show hyperdense lesions in the right temporal, right parietal, and left frontal lobar areas.

hemorrhagic lobar hyperintense-hypointense mixed lesions on T2 and FLAIR-weighted images and hyperintense lesions on T1-weighted images in the right temporal (2.3 cm in diameter), right parietal (1.6 cm in diameter), and left frontal (1.2 cm in diameter) areas, which were not contrast-enhancing. The right temporal region is surrounded by edema (Figs. 2–4). Intracranial MR angiography was normal. Thus cerebral cavernomatosis was considered in the differential diagnosis. The patient was treated with levetiracetam 1000 mg/d and seizures were controlled. She was discharged from hospital because surgeons were conservative about operating on her finding it risky due to her previous history of liver transplantation. Moreover, because the result her neurologic examination was normal and hemorrhagic lesion was limited, surgery was not thought to be crucial.

Nine months after the initial presentation, she presented with nausea and headache. Her MRI showed recurrence of hemorrhage, extension of the lesion size, and severe edema in the right temporal lesion, for which the patient was operated urgently. Surgical excision via a right temporal craniotomy for the entire right temporal lesion was undertaken. Histopathological examination revealed thick-walled, hyalinized vascular channels. Some had occluded lumens. Surrounding brain parenchyma showed reactive astrogliosis. Hemosiderin deposition was also evident adjacent to large vessels (Fig. 5). The histopathological diagnosis was cavernoma. Now she has been seizure-free for 17 months.

DISCUSSION

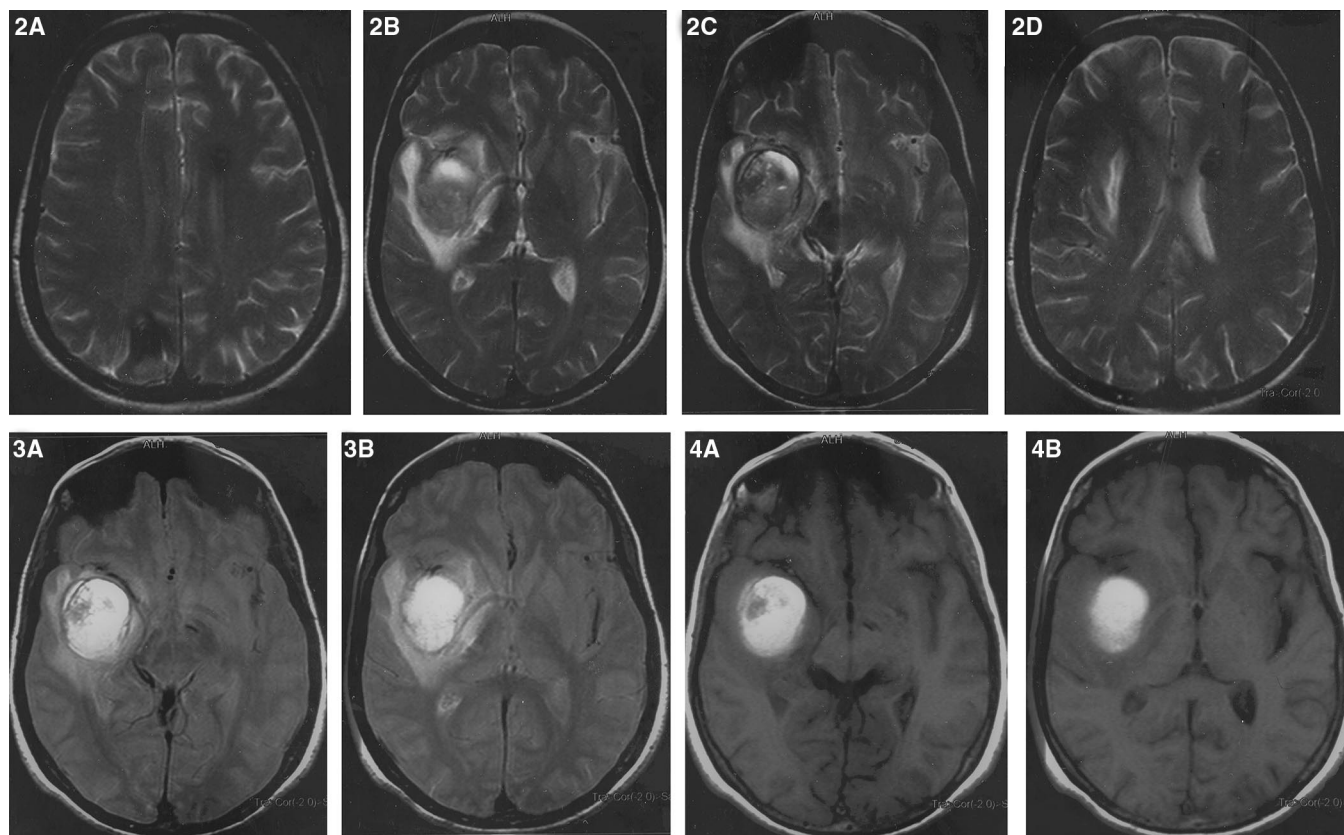
The most frequent symptoms of cavernomas are epileptic seizures, hemorrhage, focal neurologic deficits, and headaches.^{7,8,14,15} However, many patients are entirely asymptomatic.^{16–20} Clinical presentation usually occurs between the third and fifth decades, but the first symptoms may appear at any age.^{4,8} We report a patient with multiple cerebral lesions. She had 3 seizures. Cerebral cavernomatosis and hemorrhagic neoplasms were taken into consideration in the differential diagnosis. MRI delineated discrete lesions, typical of cavernous angiomas, with a mixed hyperintense, reticulated, central core surrounded by a hypointense rim.

Diagnosis is based on typical findings on MRI in combination with angiography presenting a normal vascular anatomy. This patient with multiple cerebral cavernomatosis was considered for surgery and it was decided that she would not be operated unless it was urgent because she had had a liver transplantation and was using immunosuppressants. Levetiracetam was administered because of its pharmacokinetic profile that includes minimal protein binding, lack of hepatic metabolism, and no interaction with other drugs.²¹ Her seizures discontinued with levetiracetam. However, she had to be operated upon the recurrence of bleeding and extension of severe edema in one of her cavernomas.

In a recent study, the authors reported the favorable neurologic and seizure outcomes after surgical resection of patients with supratentorial cerebral cavernous malformations and epileptic seizures.

The surgical treatment of cerebral cavernomas remains to be controversial.¹² Most surgeons would agree on surgery in symptomatic patients with a readily accessible and isolated lesion that has produced repetitive or progressive symptoms.^{12,22} A conservative approach is best adopted when there is a clinically silent lesion in an eloquent area or there are stable neurologic deficits.¹² However, surgery for supratentorial CCM in noneloquent locations is safe and curative.²³ In a recent study, the authors reported the favorable neurologic and seizure outcomes after surgical resection of patients with supratentorial CCM and epileptic seizures.²⁴ Eventually, the optimal management of cavernous malformations should be determined on a case-by-case basis and, when indicated to be favorable, surgery provides good outcome. Unlike our patient's initial hemorrhage, which was limited, the second hemorrhage was extensive and lethal, thus, she was operated despite its risks.

The reported overt annualized bleeding rate is slightly less than 1% in patients with cavernoma although repeated, often occult, hemorrhagic episodes are common.³ Her age being close to the upper limit for the most frequent bleeding from cavernomas, ie, the fifth decade of life, the annualized bleeding rate



FIGURES 2–4. Diagnostic images of patient. Cranial T2 (2A, 2B, 2C, 2D) and FLAIR (3A, 3B) and T1 (4A, 4B)-weighted images show multiple lesions of mixed signal with subacute and chronic hemorrhagic content in the right temporal (2.3 cm in diameter), right parietal (1.6 cm in diameter), and left frontal (1.2 cm in diameter) regions. The right temporal region is surrounded with edema.

being less than 1%, and her using immunosuppressants led us refrain from the operation of her other cavernomas.

Cavernomas occur in sporadic and familial forms.^{14,25} The familial form is characterized by multiple lesions and autosomal dominant transmission. However, in sporadic form, patients usually have a single lesion.²⁵ In some patients with no positive family history, multiple lesions (usually 2 or 3) can be found sporadically.^{26–28} Our patient's parents were deceased and she had 5 (3 men, 2 women) siblings and 3 children (1 boy, 2 girls). Her siblings and her son did not agree to an investigation. Therefore only 2 family members (26-year-old and 20-year-old daughters) were scanned by MRI and were found to be normal. Hence, in our case, a family history of multiple cavernomas, epilepsy and focal neurologic deficits were not detected. It was concluded that our case was most probably sporadic.

Mutations in Krit 1, a gene located at the cerebral cavernous malformations 1 locus on chromosome 7q21, account for the majority of familial cavernoma cases.

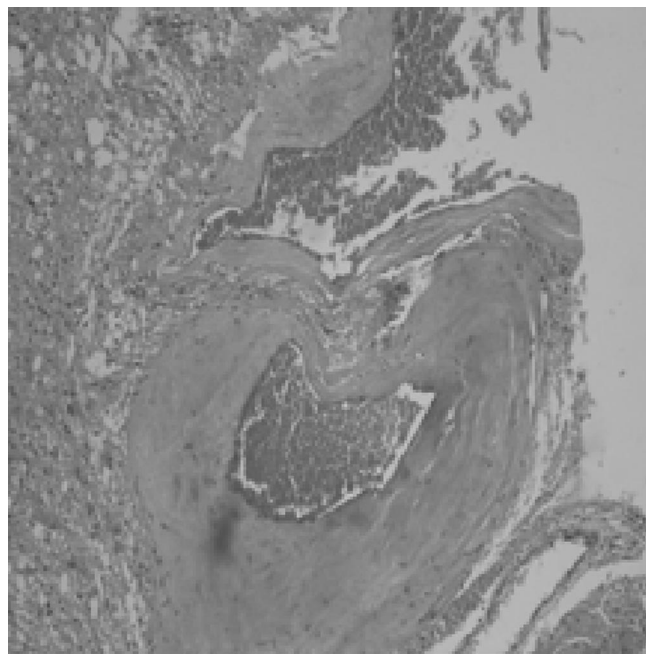


FIGURE 5. Histopathologic appearance of lesion. Figure shows reactive gliosis of the surrounding pathologic vessel with thick-hyalinized walls. (Hematoxylin-eosin stain).

In the genetic investigations on the CCM gene 3 different gene regions were observed.²⁹ Three CCM loci were previously mapped on 7q (CCM1), 7p (CCM2), and 3q (CCM3).^{29–31} Mutations in Krit 1, a gene located at the CCM1 locus on chromosome 7q21, account for the majority of familial cavernoma cases.³² These mutations are seldom a cause of sporadic cases.^{33,34} Recently, Verlaan et al screened for the CCM1 gene in 35 sporadic cases with either single or multiple cavernomas.²⁷ They detected that 29% of the cases with multiple CCM have a CCM1 mutation, whereas cases with only 1 malformation have none.²⁷ Sporadic cases with multiple malformations warrant the same approach as individuals who have a familial history of CCM.²⁷

Genetic confirmation of our patient and family members has not been completed yet. There are no recent results. However, we believe that early identification of symptomatic and asymptomatic family members may prevent life-threatening complications. When multiple cerebral cavernomatosis are identified in a patient, a detailed neurologic family history should be sought despite the possibility of the patient being a sporadic case. In conclusion, our main intention is to present a patient who is surgically controversial and to point out the importance of genetic heredity.

REFERENCES

- Roland RL, Mark WB, Mark LB, et al. Brain capillary telangiectasia. MR Imaging appearance and clinicohistopathologic findings. *Neuroradiology*. 1997;205:797–805.
- Wagner BJ, Richardson KJ, Moran AM, et al. Intracranial vascular malformations. *Semin Ultrasound CT MR*. 1995;16:253–268.
- Robinson JR, Awad IA, Little JR. Natural history of the cavernous angioma. *J Neurosurg*. 1991;75:709–714.
- Del Curling O Jr, Kelly DL Jr, Elster AD, et al. An analysis of the natural history of cavernous angiomas. *J Neurosurg*. 1991;75:702–708.
- Tagle P, Huete I, Mendez J, et al. Intracranial cavernous angioma: presentation and management. *J Neurosurg*. 1986;64:720–723.
- Simard JM, Garcia-Bengochea F, Ballinger WE Jr, et al. Cavernous angioma: a review of 126 collected and 12 new clinical cases. *Neurosurgery*. 1986;18:162–172.
- Rigamonti D, Drayer BP, Johnson PC, et al. The MRI appearance of cavernous malformations (angiomas). *J Neurosurg*. 1987;67:518–524.
- Zabramski JM, Wascher TM, Spetzler RF, et al. The natural history of familial cavernous malformations: results of an ongoing study. *J Neurosurg*. 1994;80:422–432.
- Giombrini S, Morello G. Cavernous angiomas of the brain. Account of fourteen personal cases and review of the literature. *Acta Neurochir (Wien)*. 1978;40:61–82.
- Voigt K, Yasargil MG. Cerebral cavernous hemangiomas or cavernomas. Incidence, pathology, localization, diagnosis, clinical features and treatment. Review of the literature and report of an unusual case. *Neurochirurgia (Stuttg)*. 1976;19:59–68.
- Sunada I, Nakabayashi H, Tsuchida K, et al. A case of familial cerebral cavernous angioma and review of Japanese cases. *No Shinkei Geka*. 2001;29:359–365.
- Stacey RJ, Findlay GFG, Foy PM, et al. Cavernomas in the central nervous system and the relevance of multiple intracranial lesions in the familial form of this disease. *J Neurol Neurosurg Psychiatry*. 1999;66:117.
- Bruneteau L, Labauge P, Tournier-Lasserre E, et al. Familial form of intracranial cavernous angioma: MR imaging findings in 51 families. *Radiology*. 2000;214:209–216.
- Rigamonti D, Hadley MN, Drayer BP, et al. Cerebral cavernous malformations. Incidence and familial occurrence. *N Engl J Med*. 1988;319:343–347.
- Kattapong VJ, Hart BL, Davis LE. Familial cerebral cavernous angiomas: clinical and radiologic studies. *Neurology*. 1995;45:492–497.
- Hayman LA, Evans RA, Ferrell RE, et al. Familial cavernous angiomas: natural history and genetic study over a 5-year period. *Am J Med Genet*. 1982;11:147–160.
- Mason I, Aase JM, Orrison WW, et al. Familial cavernous angiomas of the brain in an Hispanic family. *Neurology*. 1988;38:324–326.
- Gunel M, Awad IA, Finberg K, et al. Genetic heterogeneity of inherited cerebral cavernous malformation. *Neurosurgery*. 1996;38:1265–1271.
- Polymeropoulos MH, Hurko O, Hsu F, et al. Linkage of the locus for cerebral cavernous hemangiomas to human chromosome 7q in four families of Mexican-American descent. *Neurology*. 1997;48:752–757.
- Kuhn J, Knitelius HO, Bewermeyer H. Multiple cerebral cavernous malformations: typical pattern on MR imaging and appearance of a new lesion in the follow-up MRI. *Rontgenpraxis*. 2004;55:200–202.
- Arroyo S, Crawford P. Safety profile of Levetiracetam. *Epileptic Disord*. 2003;5:57–63.
- Perez-Lopez C, Isla-Guerrero A, Gomez-Sierra A, et al. [Management of multiple cerebral cavernomatosis]. *Rev Neurol*. 2002;35:407–414.
- D'Angelo VA, De Bonis C, Amoroso R, et al. Supratentorial cerebral cavernous malformations: clinical, surgical, and genetic involvement. *Neurosurg Focus*. 2006;21:e9.
- Baumann CR, Acciarri N, Bertalanffy H, et al. Seizure outcome after resection of supratentorial cavernous malformations: a study of 168 patients. *Epilepsia*. 2007;48:559–563.
- Rutka JT, Brant-Zawadzki M, Wilson CB, et al. Familial cavernous malformations. Diagnostic potential of magnetic resonance imaging. *Surg Neurol*. 1988;29:467–474.
- Horowitz M, Kondziolka D. Multiple familial cavernous malformations evaluated over three generations with MR. *AJNR*. 1995;16:1353–1355.
- Verlaan DJ, Laurent SB, Sure U, et al. CCM1 mutation screen of sporadic cases with cerebral cavernous malformations. *Neurology*. 2004;62:1213–1215.
- Labauge P, Brunereau L, Coubes P, et al. Appearance of new lesions in two nonfamilial cerebral cavernoma patients. *Eur Neurol*. 2001;45:83–88.
- Squitieri F, Maglione V, Buzzi MG, et al. Cavernous angiomas of the nervous system in Italy: clinical and genetic study. *Neurol Sci*. 2000;21:129–134.
- Dubovsky J, Zabramski JM, Kurth J, et al. A gene responsible for cavernous malformations of the brain maps to chromosome 7q. *Hum Mol Genet*. 1995;4:453–458.
- Cave-Riant F, Denier C, Labauge P, et al. Spectrum and expression analysis of KRIT1 mutations in 121 consecutive and unrelated patients with Cerebral Cavernous Malformations. *Eur J Hum Genet*. 2002;10:733–740.
- Verlaan DJ, Davenport WJ, Stefan H, et al. Cerebral cavernous malformations: mutations in Krit1. *Neurology*. 2002;58:853–857.
- Reich P, Winkler J, Straube A, et al. Molecular genetic investigations in the CCM1 gene in sporadic cerebral cavernomas. *Neurology*. 2003;60:1135–1138.
- Laurans MS, DiLuna ML, Shin D, et al. Mutational analysis of 206 families with cavernous malformations. *J Neurosurg*. 2003;99:38–43.