

Case Reports

Ischemic Stroke and Excellent Recovery After Administration of Intravenous Tissue Plasminogen Activator

Sejal V. Jain, MD and
Lawrence D. Morton, MD

Intravenous tissue plasminogen activator has become a mainstream treatment for ischemic hyperacute stroke in the adult population. Its safety and efficacy remain undetermined in the pediatric population. We present a teenager who was hospitalized with left-sided paralysis, and with decreased sensations on the left side. Head computed tomography indicated hyperdensity in the middle cerebral artery region, which confirmed the diagnosis of acute ischemic stroke. Her score on the National Institutes of Health stroke scale was 11. She received intravenous tissue plasminogen activator without any complications. At a follow-up visit 5 months after the stroke, the patient manifested mild apraxia in her left hand and mild expressive amusia. This case underscores the need for emergency head imaging in the pediatric population to establish a diagnosis. The excellent recovery in our patient indicates the need to establish thrombolytic treatment as an option for acute stroke in pediatric populations. It also suggests that tissue plasminogen activator can be used safely and effectively, even in pediatric populations. However, further studies are needed to establish the adequate dosage and adverse-effect profile in pediatric populations. © 2008 by Elsevier Inc. All rights reserved.

Jain SV, Morton LD. Ischemic stroke and excellent recovery after administration of intravenous tissue plasminogen activator. *Pediatr Neurol* 2008;38:126-129.

Introduction

Acute ischemic stroke is an emergently diagnosed and treated condition in the adult population. The Food and Drug Administration of the United States has approved tissue plasminogen activator as a treatment for acute ischemic stroke in patients aged ≥ 18 years presenting within 3 hours of the onset of signs of stroke. There are no data available regarding tissue plasminogen activator for pediatric stroke. We present a teenage girl who presented with an acute stroke and was given intravenous tissue plasminogen activator, based on criteria used for the adult population [1].

Case Report

A 15-year-old, right-handed, white female presented to the emergency room at Virginia Commonwealth University Health System with a sudden onset of left-sided paralysis, left-sided facial weakness, and decreased sensations in her left arms and leg. Before the onset of symptoms, the patient had been running track for 45 minutes, experienced dizziness, and fell to the ground. She was then observed to have left-sided weakness. The patient was brought to the emergency room via ambulance within 1 hour of the onset of her signs. Her medical history was negative for migraine, seizures, or trauma. Her family history was positive for factor V Leiden mutation in a grandfather, but there was no history of young-onset stroke. Her social history was negative for smoking, and the use of drugs or oral contraceptive pills. She was not taking any medications.

The patient's vital signs included a temperature of 36.7 C axillary, a blood pressure of 128/72, pulse at 124/min, and a respiratory rate of 22/min. On general examination, the patient was anxious, but a mental-state examination produced otherwise normal results. No murmurs or bruits were recognized. She had weakness of the lower face on her left side, including weakness of the orbicularis oculi. Her left arm and leg were completely flaccid. She had trace movements in her left foot. Babinski was positive on the left side. Sensory loss was noticed in left arm and leg. Her score on the National Institutes of Health stroke scale was 11. A computed tomography scan of her head revealed a hyperdense right middle cerebral artery in the distal branch (Fig 1). No hemorrhage or hypodensity was seen on computed tomography. Her prothrombin time, activated partial thromboplastin time, and international normalized ratio were normal. A decision was made to administer intravenous tissue plasminogen activator. Her parents were informed of the risks and

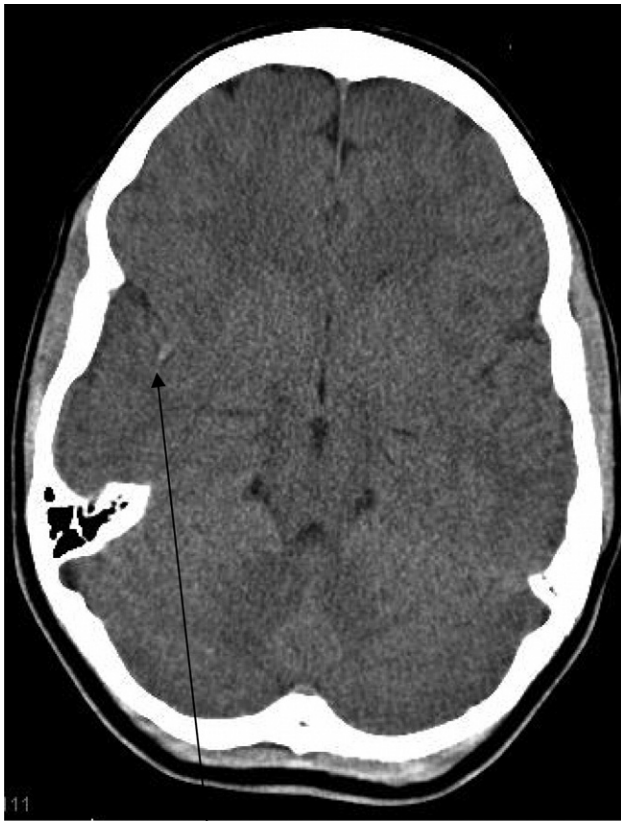


Figure 1. Computed tomography of the head demonstrates hyperdensity in the right middle cerebral artery region (arrow).

benefits based on adult studies, and they consented to the treatment. The patient was given intravenous tissue plasminogen activator at 0.9 mg/kg (5.56 mg as bolus, and 51.14 mg over the course of 1 hour) within 3 hours of the onset of signs. After administration of the tissue plasminogen activator, she experienced seizures. She had clonic activity of the left shoulder and torso with the first seizure, and clonic activity of the shoulder, arm, and face on the left side with the second seizure. These were thought to be caused by reperfusion and changes in metabolism after administration of the tissue plasminogen activator. A loading dose of fosphenytoin was given. The patient was admitted to our Neuroscience Intensive Care Unit, and was monitored as suggested by adult stroke guidelines.

Laboratory studies, including cholesterol, erythrocyte sedimentation rate, homocysteine, lipoprotein a, lupus anticoagulant, anti-cardiolipin antibodies, factor V Leiden, prothrombin mutations, proteins C and S, antithrombin activity, a factor VIII assay, and vitamin B12 produced normal results. Antinuclear antibody was positive, with a ratio of 1:320 in an atypical speckled pattern. Anti-SSA antibody, anti-Smith antibody, and anti-double-stranded DNA antibody were also at normal levels. Transthoracic echocardiogram with bubble study, showed a patent foramen ovale and an atrial septal aneurysm. Coumadin was initiated, and surgical repair was performed about 2 months after the stroke.

Her hypoesthesia and leg weakness improved rapidly after administration of tissue plasminogen activator. Her facial and left-hand weakness gradually but significantly improved. On formal speech testing, she was found to have amusia. Neuropsychologic testing, administered 3 months after the event, suggested excellent cognitive skills.

Magnetic resonance imaging was performed about 3 hours after the administration of tissue plasminogen activator, and it confirmed ischemia involving the right posterior frontal and temporal region, consistent with obstruction of the right distal middle cerebral artery (Fig 2). The magnetic resonance imaging also ruled out hemorrhage, which could

have been a potential cause of her seizures after the administration of tissue plasminogen activator. A magnetic resonance angiogram revealed a reestablished flow through the middle cerebral artery (Fig 3). A repeated head computed tomography scan 24 hours after the administration of tissue plasminogen activator did not indicate a hemorrhage. A cerebral angiogram performed 5 days later confirmed good flow through the right middle cerebral artery.

During a follow-up visit about 5 months after the event, the only apparent abnormality was mild apraxia in her left hand and mild expressive amusia. Her score on the modified Rankin scale was 1.

Discussion

In pediatric patients, the incidence of stroke involves about 2-13 per 100,000, when neonatal strokes are excluded [2,3]. Common etiologies of childhood stroke include sickle-cell disease, cardiac diseases, Moya Moya disease, prothrombotic disorders, post-varicella vasculopathy, anti-phospholipid antibodies, extracranial arterial dissections, and metabolic and mitochondrial disorders [4-6]. Cardiac diseases account for about 25-27% of cases of stroke. These include congenital anomalies such as patent foramen ovale, and cardiac procedures and conditions leading to a right-to-left shunt [2,3,5,6]. Our patient was thought to have an embolic stroke because of cardiac defects. Data regarding patent foramen ovale and paradoxical embolization as a cause of cryptogenic ischemic stroke in young patients remain controversial. One study suggested that atrial septal abnormalities, including patent foramen ovale, increase atrial vulnerability, which increases the chances of arrhythmia [7]. Recurrent paradoxical events in a patient with a patent foramen ovale are an indication for closure of the patent foramen ovale. Studies related to the closure of a patent foramen ovale suggested a good success rate in the prevention of further occurrences of embolization [8].

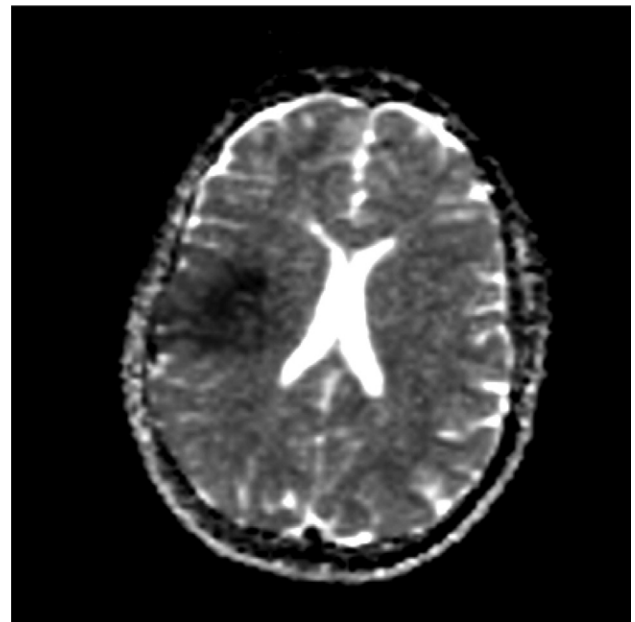


Figure 2. Apparent diffusion coefficient image confirms ischemia in the territory of the right distal middle cerebral artery.

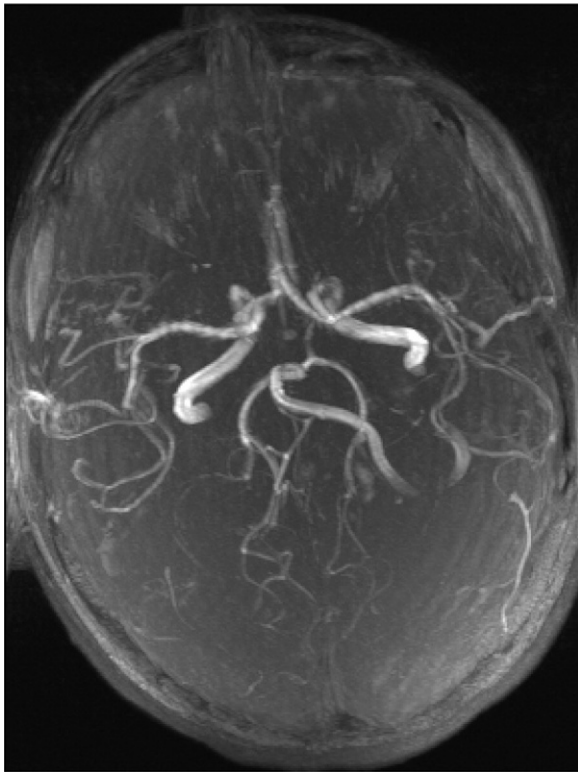


Figure 3. Magnetic resonance angiogram demonstrates flow through right middle cerebral artery after administration of tissue plasminogen activator.

Conditions such as seizure, migraine, altered mental state, and vision changes may mimic a stroke [9,10]. These conditions are more common in childhood compared with stroke, and a differential diagnosis is not immediately possible clinically. For the treatment of acute stroke, there is a very narrow time window. Thus it is important to diagnose it as soon as possible. A nonenhanced computed tomography scan helps to exclude a hemorrhage, but may not diagnose a hyperacute stroke. The patient presented here received her treatment based on hyperdense signs on a computed tomography scan, which may not be present in all patients with stroke. Magnetic resonance imaging with diffusion-weighted images, and computed tomography perfusion and computed tomography angiography, were found to be sensitive in diagnosing a hyperacute stroke [11]. Such a study should be performed in pediatric patients with signs suggestive of a stroke or its mimics. It is also important for these services to be available immediately, to diagnose and treat stroke within a 3-hour window from the onset of signs.

There is significant morbidity associated with childhood stroke. A review by Jordan [2] suggested that in children with acute ischemic stroke, 47% had moderate to severe motor deficits, 25% had recurrent seizures, and 19-44% had behavioral issues. The mean intelligence quotient was also lower in children with stroke [2], and 25-30% had recurrent stroke [2,12]. The mortality rate was reported to be 7-28% [5]. All these data suggest the need for the treatment and secondary prophylaxis of childhood stroke.

Tissue plasminogen activator has become the standard of care for adult patients with stroke. This treatment was found to reduce morbidity by 30% [13]. However, there is little information about adequate doses and safety for its use in pediatric populations. Data from Janjua et al. suggest that children who received thrombolytic therapy had higher rates of in-hospital mortality and longer hospital stays [14]. Another review suggested that major bleeding occurred in 11% and intracranial hemorrhage in 1-2% of children who received thrombolytic therapy [4]. A review by Carpenter et al. identified a total of 44 cases where intravenous or intra-arterial tissue plasminogen activator was used, but detailed only three patients who had received intravenous tissue plasminogen activator and who experienced an improvement of signs [15]. Our patient had not only excellent motor recovery, but also an excellent cognitive profile after her stroke. Thus this case is strongly suggestive of the benefits of tissue plasminogen activator in children with a hyperacute stroke. Another interesting aspect of this case was an association with seizure. The patient was initially thought to have undergone a seizure when she fell, and her weakness was thought to be due to Todd's paresis. A computed tomography scan of her head was suggestive of an occluded right middle cerebral artery, which led to the timely administration of tissue plasminogen activator. This once again strongly suggests the need for timely imaging studies, and particularly magnetic resonance imaging with diffusion-weighted imaging. There are no controlled studies for the use of tissue plasminogen activator in children. Studies are needed to establish dosage, safety, and efficacy for tissue plasminogen activator in pediatric populations.

References

- [1] **Quality Standards Subcommittee of the American Academy of Neurology.** Practice advisory: Thrombolytic therapy for acute ischemic stroke—Summary statement. Report of the Quality Standards Subcommittee of the American Academy of Neurology. *Neurology* 1996;47:835-9.
- [2] **Jordan LC.** Stroke in childhood. *Neurologist* 2006;12:94-102.
- [3] **Matta AP, Galvao KR, Oliveira BS.** Cerebrovascular disorders in childhood: Etiology, clinical presentation, and neuroimaging findings in a case series study. *Arq Neuropsiquiatr* 2006;64:181-5.
- [4] **Kirton AG, DeVeber G.** Therapeutic approaches and advances in pediatric stroke. *Neuro Rx* 2006;3:133-42.
- [5] **Lynch JK, Hirtz DG, DeVeber G, Nelson KB.** Report of the National Institute of Neurological Disorders and Stroke Workshop on Perinatal and Childhood Stroke. *Pediatrics* 2002;109:116-23.
- [6] **Lynch JK, Pavlakis S, DeVeber G.** Treatment and prevention of cerebrovascular disorders in children. *Curr Treat Options Neurol* 2005; 7:469-80.
- [7] **Berthet K, Lavergne T, Cohen A, et al.** Significant association of atrial vulnerability with atrial septal abnormalities in young patients with ischemic stroke of unknown cause. *Stroke* 2000;31:398-403.
- [8] **Horton SC, Bunch TJ.** Patent foramen ovale and stroke. *Mayo Clin Proc* 2004;79:79-88.
- [9] **Calder K, Kokorowski P, Tran T, Henderson S.** Emergency department presentation of pediatric stroke. *Pediatr Emerg Care* 2003; 19:320-8.

[10] **Shellhaas** RA, Smith SE, O'Tool E, Licht DJ, Ichord RN. Mimics of childhood stroke: Characteristics of a prospective cohort. *Pediatrics* 2006;118:704-9.

[11] **Hunter** JV. New radiographic techniques to evaluate cerebrovascular disorders in children. *Semin Pediatr Neurol* 2000;7:261-77.

[12] **DeVeber** G. In pursuit of evidence-based treatments for paediatric stroke: The UK and Chest guidelines. *Lancet Neurol* 2005;4:432-6.

[13] **National Institute of Neurological Disorders and Stroke rt-PA Stroke Study Group**. Tissue plasminogen activator for acute ischemic stroke. *N Engl J Med* 1995;333:1581-7.

[14] **Janjua** N, Nasar A, Lynch JK, Qureshi AI. Thrombolysis for ischemic stroke in children. Data from the nationwide inpatient sample. *Stroke* 2007;6:1850-4.

[15] **Carpenter** J, Tsuchida T, Lynch JK. Treatment of arterial ischemic stroke in children. *Expert Rev Neurother* 2007;7:383-92.