

Case report

## Aspirin-associated intracerebral hemorrhage in a patient with CADASIL

Jung-Hwan Oh, Jung Seok Lee, Sa-Yoon Kang,  
Ji-Hoon Kang, Jay Chol Choi\*

*Department of Neurology, Cheju National University School of Medicine, Jeju, Republic of Korea*

Received 25 July 2007; received in revised form 3 December 2007; accepted 4 December 2007

### Abstract

Cerebral autosomal dominant arteriopathy with subcortical infarcts and leukoencephalopathy (CADASIL) is a hereditary disease characterized by ischemic stroke, cognitive impairment, migraine and neuropsychological deficit. Although intracerebral hemorrhage (ICH) has been described in patients with CADASIL, the cause of such ICH is still unknown. We present a 39-year-old man with CADASIL who had two years history of untreated hypertension. In this patient, acute ICH developed only two weeks after the initiation of aspirin. Brain images demonstrated a 3 cm × 3 cm hyperacute ICH in the left temporal lobe at the site of previous old hemorrhage. The presence of cerebral microbleed and use of antithrombotics may be associated with development of ICH in patients with CADASIL.

© 2007 Elsevier B.V. All rights reserved.

*Keywords:* CADASIL; Intracerebral hemorrhage; Aspirin; Hypertension

### 1. Introduction

Cerebral autosomal dominant arteriopathy with subcortical infarcts and leukoencephalopathy (CADASIL) is a hereditary disease of the cerebral small blood vessels, and it is caused by mutations in the *Notch 3* gene [1]. The main clinical manifestations are recurrent ischemic stroke, migraine, and progressive cognitive impairment. Cerebral microbleeds (CMBs) were found in 31–69% of the patients with CADASIL [2,3] and recently we have reported that as much as 25% of patients with CADASIL had intracerebral hemorrhages (ICHs) [4]. However, the exact mechanisms by which ICHs occurred in patients with CADASIL are unknown currently. Here we report a patient with CADASIL who developed ICH soon after receiving antiplatelet agent.

### 2. Case report

A 39-year-old right-handed Korean man came into the hospital because of sudden dysarthria and right hemiparesis. At that time, multiple acute cerebral infarctions were found on the left internal capsule and basal ganglia (Fig. 1A and B). The brain magnetic resonance image (MRI) also revealed multiple white matter hyperintensity lesions, eight cerebral microbleeds, and an old hemorrhage approximately 2 cm × 2.5 cm in size on the left temporal lobe (Fig. 1C–F). There was no significant stenosis or malformation of major cerebral arteries and neck vessels on magnetic resonance angiography. He had two years history of hypertension without any treatment. The patient denied history of head trauma. He was a current smoker and had a history of drinking less than two cups of alcohol everyday for more than 10 years. His family history disclosed that both his grandfather and father died of stroke. He had no history of drug abuse. There were no hematological abnormalities on complete blood count and coagulation tests. He was found to have a heterozygote R544C mutation at exon 11 of *Notch 3* gene. He began to take aspirin 300 mg daily. Twelve days after initial admission, he visited

\* Corresponding author at: Department of Neurology, Cheju National University Hospital, 154 Samdo 2-dong, Jeju-si, Jeju-do 690-716, Republic of Korea. Tel.: +82 64 750 1131; fax: +82 64 754 1109.

E-mail address: iguazzu@hanmail.net (J.C. Choi).

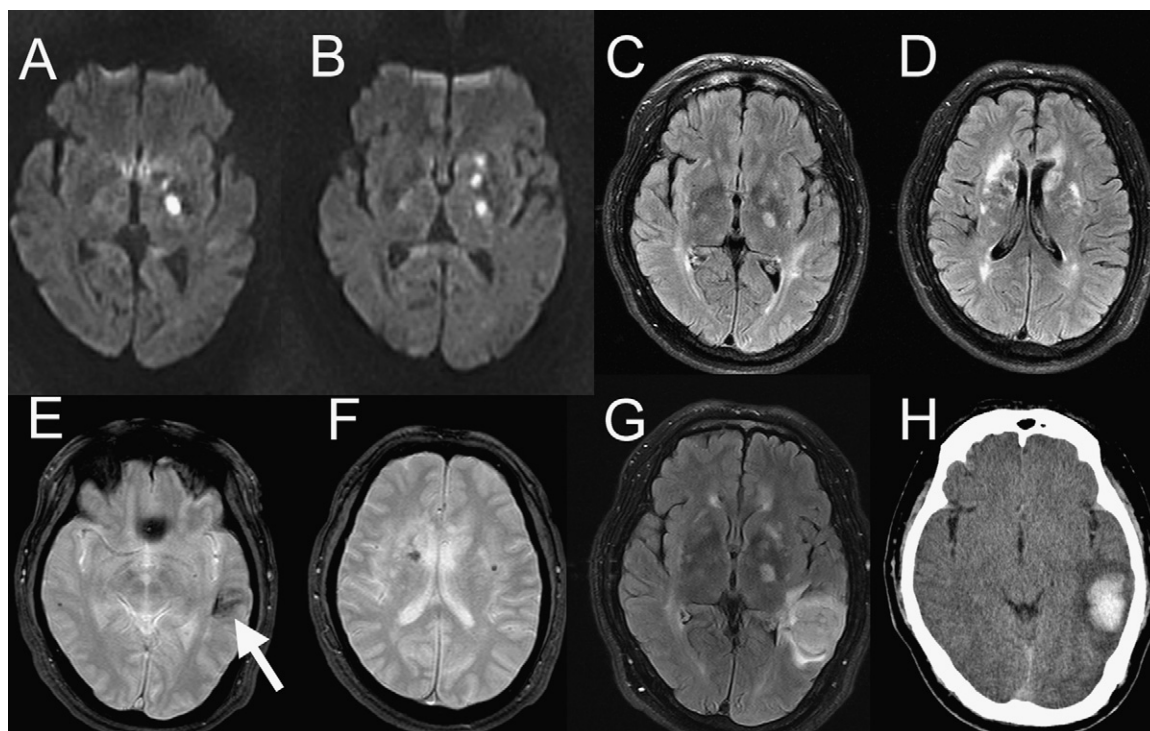


Fig. 1. Initial diffusion-weighted images (A and B) show multiple small lesions on the left internal capsule and basal ganglia. There are multiple white matter high signal intensity lesions on initial FLAIR images (C and D). Gradient echo images (E and F) demonstrate several microbleeds and an old hemorrhage on the left temporal lobe (arrow). FLAIR (G) image at second admission shows newly developed hyperacute hematoma on the left temporal lobe. Follow up CT (H) done five days later shows no significant change of the size of hematoma.

again due to abrupt speech difficulty. Initial blood pressure was 140/90 mmHg and neurological examination at that time showed newly developed sensory aphasia. Right hemiparetic condition had partially resolved, when compared to the initial admission state. Brain MRI demonstrated a 3 cm × 3.5 cm hyperacute ICH in left temporal lobe superior to the previous old hemorrhage (Fig. 1G). Follow up CT done five days later showed no significant change of hematoma size (Fig. 1H). The patient showed gradual recovery without the evacuation of hematoma.

### 3. Discussion

Although this patient had a history of hypertension, it may not be the only cause for the ICH because the patient did not show elevated blood pressure at onset of ICH and hemorrhage was located in the lobar area. Intracerebral hemorrhage has been described only sporadically for patients with CADASIL. However, recently we have reported that nearly a quarter of patients with CADASIL had ICHs and the presence of CMBs was also closely related with ICHs in the report [4]. According to the report, no correlation was observed between specific genotype and predisposition to ICH. The pathologic changes found on cerebral small vessels of the patients with CADASIL include thickening of the vessel wall, dilatation of the Virchow–Robin spaces, hyalinosis of the lamina media,

and accumulation of granular osmiophilic material (GOM) adjacent to the basement membrane. Most of those findings except accumulation of GOM were also present on hypertensive cerebral arteriopathy which is known to be the most common cause of ICH [5].

In this patient, ICH developed less than two weeks after the initiation of antiplatelet therapy and therefore use of aspirin may have triggered the development of ICH. Aspirin has been widely used to prevent myocardial infarction and ischemic stroke and it is associated with increased risk of hemorrhagic stroke [6]. In present report, we prescribed 300 mg of aspirin to the patient according to the revised guidelines on the treatment of acute ischemic stroke [7]. However, the dose of aspirin may be an important factor of developing ICH. A case-control study showed that low dose aspirin use was not associated with increased risk of ICH, whereas moderate to high doses ( $\geq 200$  mg) yielded in odd ratio of 3.05 [8]. Wong et al. reported that the lobar hemorrhages were more common in aspirin-associated ICHs than non-aspirin users and they also found that the presence of CMBs were associated with development of ICHs in subsequent study [9,10].

However, there are also reports of patients with CADASIL who developed ICH while they were not receiving antiplatelet agents [11,12]. Because the patient in our study had a history of hypertension and CADASIL-related vascular damage, we could not conclude that his ICH developed solely by the use of aspirin. High dose aspirin may only trigger the development

ICH in the patient who already had hypertensive and CADASIL-related arteriopathy. Therefore, ICHs in patients with CADASIL may result from combinations of several factors such as concurrent hypertension, presence of CMBs, and use of antiplatelet agents. Future studies are warranted to investigate the exact mechanisms underlying development of ICH in patients with CADASIL.

#### 4. Conclusion

Although intracerebral hemorrhage has been described in patients with CADASIL, the cause of such ICH is still unknown. In this patient, ICH developed less than two weeks after the initiation of antiplatelet therapy and therefore use of aspirin may trigger the development of ICH. ICHs in patients with CADASIL may result from combinations of several factors such as concurrent hypertension, CADASIL-associated arteriopathy, and use of antiplatelet agents.

#### Conflicts of interest

The authors report no conflicts of interest.

#### References

- [1] Joutel A, Corpechot C, Ducros A, Vahedi K, Chabriat H, Mouton P, et al. Notch3 mutations in CADASIL, a hereditary adult-onset condition causing stroke and dementia. *Nature* 1996;383:707–10.
- [2] Dichgans M, Holtmannspotter M, Herzog J, Peters N, Bergmann M, Yousry TA. Cerebral microbleeds in CADASIL: a gradient-echo magnetic resonance imaging and autopsy study. *Stroke* 2002;33:67–71.
- [3] Lesnik Oberstein SA, van den Boom R, van Buchem MA, van Houwelingen HC, Bakker E, Vollebregt E, et al. Cerebral microbleeds in CADASIL. *Neurology* 2001;57:1066–70.
- [4] Choi JC, Kang SY, Kang JH, Park JK. Intracerebral hemorrhages in CADASIL. *Neurology* 2006;67:2042–4.
- [5] Ruchoux MM, Maurage CA. CADASIL: Cerebral autosomal dominant arteriopathy with subcortical infarcts and leukoencephalopathy. *J Neuropathol Exp Neurol* 1997;56:947–64.
- [6] He J, Whelton PK, Vu B, Klag MJ. Aspirin and risk of hemorrhagic stroke: a meta-analysis of randomized controlled trials. *JAMA* 1998;280:1930–5.
- [7] Adams Jr HP, del Zoppo G, Alberts MJ, Bhatt DL, Brass L, Furlan A, et al. Guidelines for the early management of adults with ischemic stroke: a guideline from the American Heart Association/American Stroke Association Stroke Council, Clinical Cardiology Council, Cardiovascular Radiology and Intervention Council, and the Atherosclerotic Peripheral Vascular Disease and Quality of Care Outcomes in Research Interdisciplinary Working Groups: The American Academy of Neurology affirms the value of this guideline as an educational tool for neurologists. *Circulation* 2007;115:e478–534.
- [8] Thrift AG, McNeil JJ, Forbes A, Donnan GA. Risk of primary intracerebral haemorrhage associated with aspirin and non-steroidal anti-inflammatory drugs: case-control study. *BMJ* 1999;318:759–64.
- [9] Wong KS, Chan YL, Liu JY, Gao S, Lam WW. Asymptomatic microbleeds as a risk factor for aspirin-associated intracerebral hemorrhages. *Neurology* 2003;60:511–3.
- [10] Wong KS, Mok V, Lam WW, Kay R, Tang A, Chan YL, et al. Aspirin-associated intracerebral hemorrhage: Clinical and radiologic features. *Neurology* 2000;54:2298–301.
- [11] Ragooschke-Schumm A, Axer H, Witte OW, Isenmann S, Fitzek C, Dichgans M, et al. Intracerebral haemorrhage in CADASIL. *J Neurol Neurosurg Psychiatry* 2005;76:1606–7.
- [12] Maclean AV, Woods R, Alderson LM, Salloway SP, Correia S, Cortez S, et al. Spontaneous lobar haemorrhage in CADASIL. *J Neurol Neurosurg Psychiatry* 2005;76:456–7.