

CASE REPORT

Hemichorea associated with gabapentin therapy with hypoperfusion in contralateral basal ganglion – a case of a paraplegic patient with neuropathic pain

M.-H. Lai* MD, T.-Y. Wang† MD, C.-C. Chang* MD, K.-C. Tsai* MD, PhD and S.-T. Chang* MD, MS, PhD

Departments of *Physical Medicine and Rehabilitation and †Psychiatry, Tri-Service General Hospital, National Defense Medical Center, Taipei, Taiwan

SUMMARY

Functional imaging in patients with movement disorders has suggested abnormalities of regional cerebral blood flow (rCBF). We describe a patient with thoracic cord lesion with subsequent severe neuropathic pain. Right hemichorea developed and was related to adjunctive therapy with gabapentin. The patient's hemichorea decreased gradually after cessation of gabapentin. The study of rCBF revealed hypoperfusion in the contralateral basal ganglia compared with the previous study of rCBF. Our patient is the first patient with neuropathic pain, treated with gabapentin who developed hemichorea, in the absence of brain lesions. Imaging studies of rCBF showed a perfusion defect in the contralateral basal ganglion.

Keywords: gabapentin, hemichorea, neuropathic pain

INTRODUCTION

Severe neuropathic pain with musculoskeletal pain often follows spinal cord injury (SCI) (1). In an extensive discussion of the treatment of neuropathic pain with gabapentin as a first-line drug in spinal cord injury, side effects of the drug, such as nausea, vomiting, weakness, oedema, vertigo,

Received 19 May 2007, Accepted 9 October 2007

Correspondence: Dr Shin-Tsu Chang, Department of Physical Medicine and Rehabilitation, Tri-Service General Hospital, School of Medicine, National Defense Medical Center, #325, Section 2, Cheng-Gung Road, Taipei 114, Taiwan. Tel: +886 2 879 23311; fax: +886 945 605 523; e-mail: stchang@ms87.url.com.tw

sedation, headache and itching, were considered minor and easily tolerated (2). However, there has been little discussion on hemichorea caused by gabapentin. Here, we report an adult patient with spinal cord injury with neuropathic pain, who developed hemichorea after taking gabapentin. The hemichorea gradually disappeared after cessation of gabapentin, and regional cerebral blood flow (rCBF) imaging using single photon emission computed tomography (SPECT) showed a perfusion defect in the contralateral basal ganglion.

CASE REPORT

A relatively healthy 41-year-old man with no history of trauma or recent exertion presented with paraplegia, hypoesthesia below the T-6 dermatome and abnormality in sphincter tone with normal serum profiles. Magnetic resonance (MR) imaging of the thoracolumbar spine showed an extradural fusiform mass located in the epidural dorsal space between T6 and T8 vertebral body levels with obvious compression and displacement of the spinal cord (Fig. 1). Administration of high-dose steroid injection has been performed followed by an emergency surgery with decompressive laminectomy. Pathology report revealed haemangioma.

Two weeks after operation, he presented hyperalgesia and allodynia below L-3 dermatome without any pathologic findings. His visual analogue scale (VAS) score was 9. The second MR imaging of thoracolumbar spine was negative. The rCBF of SPECT was performed under impression of complex regional pain syndrome, and revealed hypoperfusion of left temporo-parietal region and occipital region, but normal in the bilateral basal

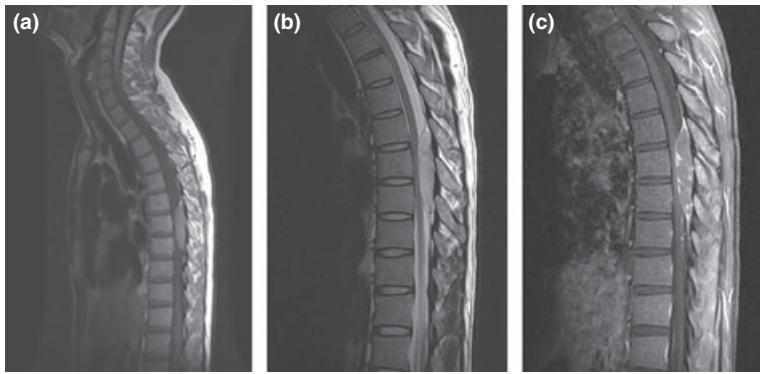

Fig. 1. Magnetic resonance imaging of thoracic spine performed 9 h after onset of symptoms. (a) Sagittal T1-weighted image. (b) Sagittal T2-weighted image. (c) Sagittal T1-weighted image with contrast. Note an extradural fusiform mass, $1.6 \times 1.3 \times 5.9$ cm, causing spinal cord compression.

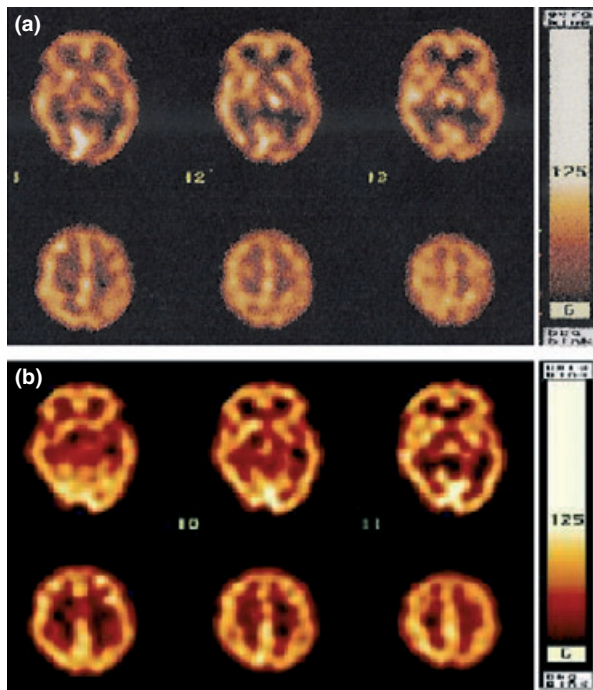


Fig. 2. Single photon emission computed tomography of brain perfusion performed (a) 2 weeks after operation showing normal perfusion of bilateral basal ganglia; (b) 7 weeks after operation. Note the hypoperfusion of left basal ganglia, especially left caudate contralateral to his right hemichorea side.

ganglia and thalami (Fig. 2a). Combination of non-steroid anti inflammatory drug (NSAID), acetaminophen and intermittent morphine injection, initially prescribed for his neuropathic pain, was ineffective. Four weeks after operation, we added imipramine up to 150 mg per day for his neuropathic pain and depressed mood. His VAS score was reduced from 9 to 4. However, intractable neuropathic pain flared up and impeded the rehabilitation therapy even 6 weeks after opera-

tion. Therefore, we added gabapentin from 600 to 1200 mg per day in 3 days.

To our surprise, he presented with involuntary movement in right lower extremity 4 days after the initiation of treatment with gabapentin 1200 mg per day. His involuntary movement progressed upward from lower right extremity to the trunks and right upper extremity. The movement disorder of his right limbs was similar to uncontrolled dancing and disappeared during sleep, and hemichorea was confirmed. The movement pattern of hemichorea was continuous, unconscious, slow and twisting especially when he rotated his trunk. His motor strength was 5/5 in both upper extremities and 3/5 in both lower extremities. Hyperalgesia, allodynia and hyperesthesia were detected below approximately T12 level. Hyperactive reflex with right ankle clonus was obvious and Barbinski's signs were present. Serum profiles were within normal limits. MR imaging of the brain was negative. Owing to the high possibility of drug effect, we discontinued gabapentin and increased the dose of imipramine and morphine. The frequency of the hemichorea decreased within 2 days and disappeared within 1 week. We performed rCBF of SPECT again, which revealed that although the perfusion of bilateral thalami and cerebellum was normal, hypoperfusion of left temporal region and left basal ganglia, especially of the left caudate was observed (Fig. 2b). We suggested that our patient considered taking gabapentin again to clarify the cause of his hemichorea, but he refused. Then, he kept on his rehabilitation therapy at our rehabilitation centre. Five months after operation, his American Spinal Injury Association (ASIA) motor score was 80, pin prick score was 96, and light touch score was 91 with anal sensation and voluntary contraction and his

ASIA impairment scale improved from B to D. The VAS score improved from 4 to 3. Intermittent catheterization remained thrice per day because of his neurogenic bladder. Muscle power over his lower limbs improved from 2/5 to 4/5 and he was able to walk with a walker for some distance.

DISCUSSION

Neuropathic pain is a chronic and severe pain, which responds poorly to analgesics and impedes rehabilitation therapy. The diagnosis of neuropathic pain is based on clinical symptoms and physical examination (3). In the early stage of spinal cord lesion, the pain is usually musculoskeletal or neuropathic in character (4). After excluding the possibility of musculoskeletal lesion, our case presented with severe neuropathic pain in the early stage of spinal cord lesion. His neuropathic pain responded well to imipramine and his VAS scale improved from 9 to 4. His neuropathic pain, however, persistently bothered him and interfered with rehabilitation therapy. Hence, we added gabapentin, 5 weeks after operation.

After taking a prescription for gabapentin of up to 1200 mg per day, he presented with hemichorea of the right limbs. The hemichorea was characterized by progressive jerky, marionette-like movements with moderate dystonia in his right limbs. To date, there is very limited study of movement disorders caused by gabapentin. Ascoape *et al.* (5) described 13 patients with myoclonus, who had refractory epilepsy under gabapentin treatment. Movement disorder in the 13 patients faded away several days after the cessation of gabapentin (5). Our case did not have a past history of movement disorder, epilepsy, consciousness disturbance or other brain lesions. Hemichorea, associated with gabapentin treatment of neuropathic pain is very different to movement disorder in epilepsy, also treated with gabapentin. There is no literature to support an association between treatment with acetaminophen and NSAID, and movement disorder. Imipramine, a tricyclic antidepressant, may cause reversible myoclonus in some patients with brain lesions. Myoclonus disappears after cessation of imipramine and persists if use is continued (6, 7). Hemichorea in our case faded away after cessation of gabapentin with continuing use of imipramine. Besides, there is no research evidence for a drug

interaction between imipramine and gabapentin. After excluding these other possibilities, we assume that hemichorea in our case was caused by gabapentin.

In studying the relationship between movement disorder and brain perfusion, researchers have shown through brain perfusion studies, that the most common cause of choreoathetosis is an ischemic lesion at the basal ganglia, especially hypoperfusion of the caudate nuclei in the contralateral side to the hemichoreic part of the body (8–10). There is a correlation between movement disorder and brain perfusion, and brain perfusion with SPECT is important in the differential diagnosis of movement disorders (8–12). Brain lesions, infectious disease, autoimmune disease and hereditary disease were found in most of the subjects with chorea. There is only one report on the relationship between drug-induced movement disorder and brain perfusion. A study showed a correlation between phenytoin-induced choreoathetosis and brain perfusion in three cases with severe myoclonic epilepsy. The report of SPECT revealed that decreased perfusion in the basal ganglia, contralateral to the unilateral choreoathetosis. However, all the three patients had severe myoclonic epilepsy in infancy (12). Hemichorea in our patient with spinal cord injury is likely to be due to gabapentin for three reasons: First, gabapentin binds to many transmembrane sites within the central nervous system (CNS) embracing the $\alpha_2\delta$ -subunit of the voltage-gated calcium channel which is found throughout the CNS, including the basal ganglia, and reduces the release of monoamine and dopamine. The imbalance of dopaminergic and cholinergic transmission at the basal ganglia may result in movement disorders (13). Second, basal ganglia-thalamocortical loops have four distinct parallel circuits (skeletal motor, oculomotor, prefrontal and limbic) (14). The patient's spinal cord lesion, neuropathic pain, as well as hypoperfusion of left tempoparietal region may influence the basal ganglia-thalamocortical loops, and the skeletal motor function of the basal ganglia. Third, our patient had no brain lesion or other systemic disease. To the best of our knowledge, this case is the first case of gabapentin-induced hemichorea shown to be correlated with hypoperfusion of the basal ganglion, especially of the caudate nucleus contralateral to the hemichorea.

REFERENCE

1. Ditunno JF, Jr. Formal CS (1994) Chronic spinal cord injury. *New England Journal of Medicine*, **330**, 550–556.
2. Levendoglu F, Ogun CO, Ozerbil O, Ogun TC, Ugurlu H (2004) Gabapentin is a first line drug for the treatment of neuropathic pain in spinal cord injury. *Spine*, **29**, 743–751.
3. Siddall PJ, Taylor DA, McClelland JM, Rutkowski SB, Cousins MJ (1999) Pain report and the relationship of pain to physical factors in the first 6 months following spinal cord injury. *Pain*, **81**, 187–197.
4. Li MH, Holtas S, Larsson EM (1992) MR imaging of spinal lymphoma. *Acta Radiologica*, **33**, 338–342.
5. Asconape J, Diedrich A, DellaBadia J (2000) Myoclonus associated with the use of gabapentin. *Epilepsia*, **41**, 479–481.
6. Garvey MJ, Tollefson GD (1987) Occurrence of myoclonus in patients treated with cyclic antidepressants. *Archives of General Psychiatry*, **44**, 269–272.
7. Forstl H, Pohlmann-Eden B (1990) Amplitudes of somatosensory evoked potentials reflect cortical hyperexcitability in antidepressant-induced myoclonus. *Neurology*, **40**, 924–926.
8. Joo EY, Hong SB, Tae WS *et al.* (2005) Perfusion abnormality of the caudate nucleus in patients with paroxysmal kinesigenic choreoathetosis. *European Journal of Nuclear Medicine and Molecular Imaging*, **32**, 1205–1209.
9. Feigin A, Leenders KL, Moeller JR *et al.* (2001) Metabolic network abnormalities in early Huntington's disease: an [(18)F]FDG PET study. *Journal of Nuclear Medicine*, **42**, 1591–1595.
10. Oh SH, Lee KY, Im JH, Lee MS (2002) Chorea associated with non-ketotic hyperglycemia and hyperintensity basal ganglia lesion on T1-weighted brain MRI study: a meta-analysis of 53 cases including four present cases. *Journal of the Neurological Sciences*, **200**, 57–62.
11. Bhatia KP, Marsden CD (1994) The behavioural and motor consequences of focal lesions of the basal ganglia in man. *Brain*, **117**(Pt 4), 859–876.
12. Saito Y, Oguni H, Awaya Y, Hayashi K, Osawa M (2001) Phenytoin-induced choreoathetosis in patients with severe myoclonic epilepsy in infancy. *Neuropediatrics*, **32**, 231–235.
13. Baillie JK, Power I (2006) The mechanism of action of gabapentin in neuropathic pain. *Current Opinion in Investigational Drugs*, **7**, 33–39.
14. Alexander GE, Crutcher MD (1990) Functional architecture of basal ganglia circuits: neural substrates of parallel processing. *Trends in Neurosciences*, **13**, 266–271.