

especially in symptomatic or large mobile tumors [4, 7–12, 19]. Its pedicle makes removal of CPF usually easy. Selected patients, as in our case, may need valve replacement [9–11, 15]. Oral anticoagulation is recommended only for patients who are not surgical candidates or for those whose tumor is asymptomatic and non-mobile [4, 8, 10]. However, no randomized controlled data are available on treatment efficacy. To our knowledge, there is no literature report of a symptomatic patient who has not presented any recurrent ischemic event after long-term oral anticoagulation [4–6, 9–11, 16, 17, 20, 23, 24].

In conclusion, CPF is a potentially treatable cause of embolic ‘stroke in the young’ [15]. Surgery excision is curative and should be the first choice. For those patients who are waiting for surgery or are not surgical candidates, oral anticoagulation therapy may be an alternative treatment. Indeed, the tumor may act as a nidus for thrombus formation rather than embolize its fragments. On the other hand, randomized controlled studies are needed to evaluate the efficacy of treatment choices.

Acknowledgement

We are grateful to the Support Center for Scientific Publications of Santa Casa de São Paulo – Faculty of Medical Sciences for the editorial assistance.

References

- Shiraishi J, Tagawa M, Yamada T, Sawada T, Tatsumi T, Azuma A, Shimada Y, Yaku H, Kitamura N, Nakagawa M: Papillary fibroelastoma of the aortic valve: evaluation with transesophageal echocardiography and magnetic resonance imaging. *Jpn Heart J* 2003;44:799–803.
- Basso C, Bottio T, Valente M, Bonato R, Casarotto D, Thiene G: Primary cardiac valve tumours. *Heart* 2003;89:1259–1260.
- Abu Nassar SG, Parker JC Jr: Incidental papillary endocardial tumor: its potential significance. *Arch Pathol* 1971;92:370–376.
- Kanarek SE, Wright P, Liu J, Boglioli LR, Bajwa AS, Hall M, Kort S: Multiple fibroelastomas: a case report and review of the literature. *J Am Soc Echocardiogr* 2003;16:373–376.
- Kasarskis EJ, O'Connor W, Earle G: Embolic stroke from cardiac papillary fibroelastomas. *Stroke* 1988;19:1171–1173.
- Giannesini C, Kubis N, N'Guyen A, Wassef M, Mikol J, Woimant F: Cardiac papillary fibroelastoma: a rare cause of ischemic stroke in the young. *Cerebrovasc Dis* 1999;9:45–49.
- Sarjeant JM, Butany J, Cusimano RJ: Cancer of the heart: epidemiology and management of primary tumors and metastases. *Am J Cardiovasc Drugs* 2003;3:407–421.
- Gowda RM, Khan IA, Nair CK, Mehta NJ, Vasavada BC, Sacchi TJ: Cardiac papillary fibroelastoma: a comprehensive analysis of 725 cases. *Am Heart J* 2003;146:404–410.
- Nawaz MZ, Lander AR, Schussler JM, Grayburn PA, Hamman BL, Roberts WC: Tumor excision versus valve replacement for papillary fibroelastoma involving the mitral valve. *Am J Cardiol* 2006;97:759–764.
- Brown RD Jr, Khandheria BK, Edwards WD: Cardiac papillary fibroelastoma: a treatable cause of transient ischemic attack and ischemic stroke detected by transesophageal echocardiography. *Mayo Clin Proc* 1995;70:863–868.
- Baba Y, Tsuboi Y, Sakiyama K, Nakajima M, Fjino Y, Meschia JF, Yamada T: Cardiac papillary fibroelastoma as a cause of recurrent ischemic strokes: the diagnostic value of serial transesophageal echocardiography. *Cerebrovasc Dis* 2002;14:256–259.
- Sun JP, Asher CR, Yang XS, Cheng GG, Scalia GM, Massed AG, Griffin BP, Ratliff NB, Stewart WJ, Thomas JD: Clinical and echocardiographic characteristics of papillary fibroelastomas: a retrospective and prospective study in 162 patients. *Circulation* 2001;22:2687–2693.
- Reynen K: Frequency of primary tumors of the heart. *Am J Cardiol* 1996;77:107.
- McAllistar HA Jr, Fenoglio JJ Jr: Tumors of the cardiovascular system; in Firingier HI (ed): *Atlas of Tumor Pathology*, 2nd ser. Washington, Armed Forces Institute of Pathology, 1978, fasc 15, vol 1–3, pp 20–25.
- Saw W, Nicholls S, Trim G, Thomson D, Hughes C, Mitchell S, Leitch J: Papillary fibroelastoma, a rare but potentially treatable cause of embolic stroke: report of three cases. *Heart Lung Circ* 2001;10:105–107.
- Ryan PE Jr, Obeid AI, Parker FB Jr: Primary cardiac valve tumors. *J Heart Valve Dis* 1995;4:222–226.
- Madhu Sankar N, Odayan MK, Morris M, Paterson H, Hanna WM: Cardiac valvular papillary fibroelastoma; report of 2 cases. *Tex Heart Inst J* 1999;26:298–299.
- Gallo R, Kumar N, Prabhakar G, Awada A, Maalouf Y, Duran CM: Papillary fibroelastoma of mitral valve chorda. *Ann Thorac Surg* 1993;55:1576–1577.
- Alessi A, Gomes de Carvalho R, Bertolin Precoma D, Fontoura D, Oliveira LR, Zanis Neto J, Zapparoli M: Fibroelastoma of the mitral valve as a cause of transient ischemic stroke. *Arq Bras Cardiol* 2001;77:77–84.
- Conte FJ, Katz AS: Images in cardiovascular medicine: fibroelastoma and embolic stroke. *Circulation* 1998;97:1648.
- Roberts WC: Papillary fibroelastoma of the heart. *Am J Cardiol* 1997;80:973–975.
- Veinot JP: Fibroelastoma and embolic stroke. *Circulation* 1999;99:2709–2712.
- Muir KW, McNeish I, Grosset DG, Metcalfe M: Visualization of cardiac emboli from mitral valve papillary fibroelastoma. *Stroke* 1996;27:1133–1134.
- Nighoghossian N, Derex L, Loire R, Perinetti M, Honnorat J, Riche G, Barthelet M, Ninet J, Chazot G, Chassignolle J, Trouillas P: Giant lambl excrescences: an unusual source of cerebral embolism. *Arch Neurol* 1997;54:41–44.

Dr. Rubens José Gagliardi
Rua Dr. Cezário Motta Jr. 112
Vila Buarque
São Paulo, SP 01221-020 (Brazil)
Tel. +55 11 3367 7834, Fax +55 11 3826 1288,
E-Mail rubensjg@apm.org.br

Cerebrovasc Dis 2008;25:187–189
DOI: 10.1159/000113737

A Caudal Mesencephalic Infarct Presenting Only with Tetra-Ataxia and Tremor

Shoichiro Sato, Kazunori Toyoda, Kayoko Kawase, Junji Kasuya, Kazuo Minematsu

Cerebrovascular Division, Department of Medicine,
National Cardiovascular Center, Osaka, Japan

Introduction

Midbrain lesions cause various clinical syndromes, including oculomotor disorders, ataxia, hemiplegia, and sensory disturbances [1–5]. Cerebellar ataxia can occur bilaterally with lesions located at the decussation of the superior cerebellar peduncles at the level of the caudal midbrain; cerebellar ataxia is almost always present with other mesencephalic syndromes, such as ophthalmoplegia [1–4]. We describe a patient with a small infarct located

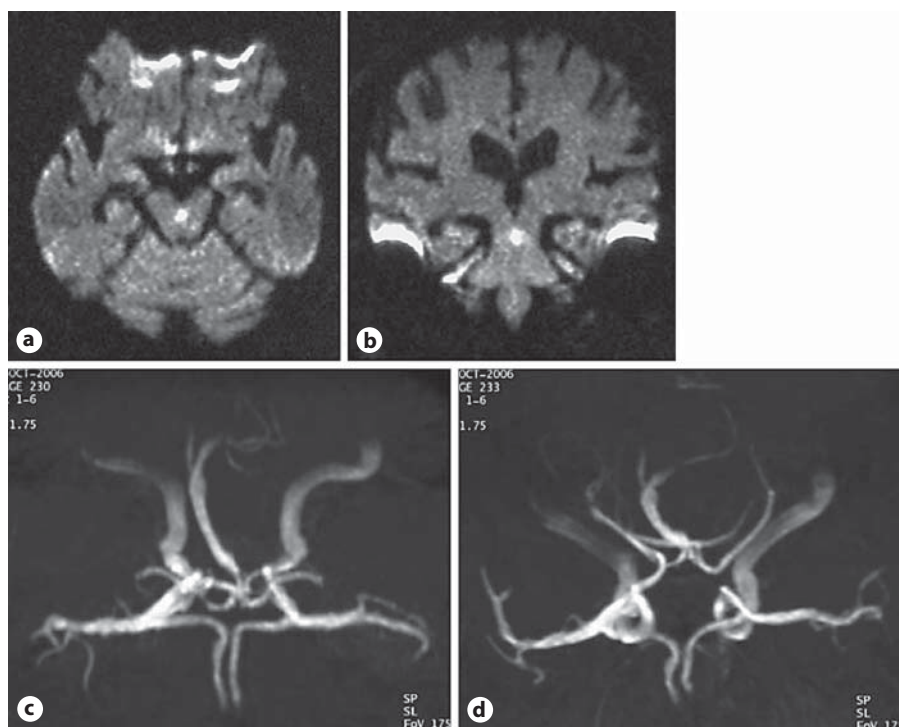


Fig. 1. Axial (a) and coronal (b) diffusion-weighted images ($b = 1,000 \text{ s/mm}^3$) show a small infarct located in the midline of the caudal midbrain. MR angiography (c, d) reveals stenosis of the distal basilar artery and narrow P1-segment of the right posterior cerebral artery, which was compensated by the development of the right posterior communicating artery.

in the caudal paramedian midbrain who presented only with tetra-ataxia and tremor.

Case Report

An 80-year-old man with a history of hypertension was transferred to our stroke care unit due to sudden onset of gait disturbance and tremor. On admission, his blood pressure was 166/82 mm Hg, his pulse was regular, and the patient was alert. Ataxia was prominent in both upper extremities, and it was also present in both lower extremities. The patient's lack of coordination was not lateralized. His speech was markedly dysarthric. He had no extraocular disorders or ptosis. His muscle tone and strength as well as reflexes were normal. The patient had a resting tremor of both upper extremities which had never been observed before the stroke onset; the frequency of the tremor was 4 Hz and the amplitude increased with postural changes and voluntary movements. The patient's sensation was normal. Diffusion-weighted magnetic resonance images showed a small, fresh infarct located in the midline of the caudal midbrain (fig. 1a, b). MR angiography, as well as conventional angiography, showed moderate stenosis of the distal basilar artery (fig. 1c). The P1-segment of the right posterior cerebral artery was narrow, and was compensated by the development of the right posterior communicating artery (fig. 1d). Blood tests, including hemostatic and autoimmune markers, were normal. On examination of the cerebrospinal fluid, there was no sonography, transthoracic echocardiography, 12-lead electrocardiography, and 72-hour ECG monitoring. Electroencephalography and brain stem auditory evoked potentials were unremarkable.

Given the diagnosis of ischemic stroke due to damage of the paramedian perforating artery associated with atherosclerosis in the basilar artery, the patient was treated with aspirin and arg-

atroban. His symptoms gradually improved within a couple of weeks; the patient was left with mild dysarthria and limb incoordination.

Discussion

The major finding of this report is that small ischemic damage in the caudal midbrain causes only tetra-ataxia and tremor without the classical mesencephalic syndrome. Hemiataxia is a common mesencephalic symptom, while tetra-ataxia is rare. Of 74 patients with isolated midbrain infarction reported in four clinical studies [1–4], 26 (35%) developed hemiataxia, and 6 (8%) had tetra-ataxia during the acute phase. Five of these 6 patients with tetra-ataxia had culprit lesions in the paramedian area [1–4]. A caudal paramedian midbrain lesion causes a bilateral cerebellar syndrome by damaging both efferent cerebellar fibers before and after decussation of the superior cerebellar peduncles, where the infarct was located in the present patient. This syndrome is called 'the Wernekinck commissure syndrome' [5, 6]. Lesions in the rostral pons also appear to be associated with this syndrome [7].

Our patient's tremor generally meets the criteria of Holmes tremor; it has a rest, intention, and postural component, with a slow frequency of $<4.5 \text{ Hz}$ [8]. However, his tremor is unique in that it appeared together with other stroke symptoms; Holmes tremor usually presents 4 weeks to 2 years later than the lesion onset. Holmes tremor appears to result from interruption of the dentato-rubro-olivary and nigrostriatal pathways, which was pleocytosis. No embolic sources were detected on carotid duplex demonstrated using positron emission tomography [8]. In particular, the rest component of tremor seems to be associated with impairments in the nigrostriatal pathway. Although our patient had a caudal midbrain lesion, nigrostriatal fibers might have been

partially interrupted. To the best of our knowledge, 2 cases with an infarct located at the paramedian midbrain presented with tetra-ataxia and ophthalmoplegia during the acute phase of the stroke and developed tremor during the acute or chronic phase [9, 10]. The concomitant occurrence of tetra-ataxia and skeletal tremor without oculomotor disorders due to mesencephalic stroke can occur, but it seems to be very rare.

A recent study examining 40 patients with isolated midbrain infarction proposed the existence of a branch atheromatous disease as the operative pathogenic mechanism in more than half of their patients [4]. Our patient's stenosis of the distal basilar artery also suggests that the occlusion of penetrating branches originating from the basilar artery could cause stroke. Spengos et al. [10] highlighted the vascular variation in the uncommon 'top of the basilar' syndrome with both posterior cerebral arteries arising from the corresponding internal carotid arteries as an etiological mechanism of the small bilateral paramedian midbrain infarction with tremor and tetra-ataxia. The fact that the P1-segment of the right posterior cerebral artery was narrow in our patient might also have contributed to the unusual configuration of isolated midbrain infarction.

Acknowledgements

This study was partially supported by research grants for cardiovascular diseases (18C-5) from the Japanese Ministry of Health, Labour and Welfare.

References

- 1 Bogousslavsky J, Maeder P, Regli F, Meuli R: Pure midbrain infarction: clinical syndromes, MRI, and etiologic patterns. *Neurology* 1994;44: 2032–2040.
- 2 Martin PJ, Chang HM, Wityk R: Midbrain infarction: associations and aetiologies in the New England Medical Center Posterior Circulation Registry. *J Neurol Neurosurg Psychiatry* 1998;64:392–395.
- 3 Kumral E, Bayulkem G, Akyol A, Yuntun N, Sirin H, Sagduyu A: Mesencephalic and associated posterior circulation infarcts. *Stroke* 2002; 33:2224–2231.
- 4 Kim JS, Kim J: Pure midbrain infarction. Clinical, radiologic and pathophysiologic findings. *Neurology* 2005;64:1227–1232.
- 5 Mossuto-Agatiello L: Caudal paramedian midbrain syndrome. *Neurology* 2006;66:1668–1671.
- 6 Dai AI, Wasay M: Werneck comissure syndrome: a rare midbrain syndrome secondary to stroke. *J Pak Med Assoc* 2006;56:289–290.
- 7 Lee H, Cho YW: Tetra-ataxia as the sole manifestation of a unilateral rostral pontine tegmental infarct. *J Neurol Neurosurg Psychiatry* 2003; 74:1445.
- 8 Deuschl G, Bain P, Brin M: Consensus statement of the Movement Disorder Society on Tremor. *Ad Hoc Scientific Committee. Mov Disord* 1998;13(suppl 3):2–23.
- 9 Okuda B, Tachibana H, Sugita M, Maeda Y: Bilateral internuclear ophthalmoplegia, ataxia, and tremor from a midbrain infarction. *Stroke* 1993;24:481–482.
- 10 Spengos K, Wöhrle JC, Tsvigoulis G, Stouraitis G, Vemmos K, Zis V: Bilateral paramedian midbrain infarct: an uncommon variant of the 'top of the basilar' syndrome. *J Neurol Neurosurg Psychiatry* 2005;76: 742–743.

Shoichiro Sato
Cerebrovascular Division, Department of Medicine
National Cardiovascular Center
5-7-1 Fujishirodai, Suita, Osaka 565-8565 (Japan)
Tel. +81 6 6833 5012, Fax +81 6 6872 7486
E-Mail shou-310@d6.dion.ne.jp

Cerebrovasc Dis 2008;25:189–191
DOI: 10.1159/000113739

Kurashiki Prehospital Stroke Scale

Kazumi Kimura, Takeshi Inoue, Yasuyuki Iguchi, Kensaku Shibazaki
Department of Stroke Medicine, Kawasaki Medical School,
Okayama, Japan

A prehospital stroke scale should identify stroke patients and measure stroke severity. Our stroke center is located in Kurashiki City, a Japanese city with a population of 460,869. The Kurashiki prehospital stroke scale (KPSS) was developed to assist emergency medical service (EMS) paramedics (table 1). The KPSS was constructed using 4 items, including consciousness level, consciousness disturbance, motor weakness and language. These 4 items were chosen and modified based on the 15 neurological examination test items of the National Institutes of Health Stroke Scale (NIHSS) score. We prospectively studied the correlation between the KPSS as determined by EMS paramedics at the place of stroke onset and the NIHSS score determined by neurologists at the time of the patient's hospital arrival.

Subjects and Methods

Consecutive patients transferred to our stroke center who were evaluated by EMS paramedics using the KPSS from September 2005 to March 2007 were enrolled prospectively. The following clinical data were collected for all patients: (1) patient age and gender; (2) KPSS score evaluated by paramedics; (3) NIHSS score evaluated by neurologists at the time of hospital arrival, and (4) diagnosis (stroke or nonstroke).

Paramedics arrived at the patients' location, and patients suspected of having a stroke were immediately evaluated using the KPSS. Before the patients were transferred to our stroke center, the paramedics called the stroke center's stroke hotline to provide the KPSS score. The NIHSS score was determined by the neurologists when the patients arrived at the hospital. Subsequently, the patients had diagnostic CT or MRI.

Statistical analysis was done using the Statview (version 5) statistical package to establish a correlation between the KPSS score and the NIHSS score using the Spearman rank correlation test. A p value of <0.05 was considered significant.

Results

A total of 90 consecutive patients (24 men, 20 women; mean age 71.8 ± 11.0 years) were enrolled in the present study. There were 71 (79%) stroke patients (46 ischemic strokes and 25 hemorrhagic strokes); 19 (21%) patients did not have a stroke. Figure 1 shows the excellent correlation between the KPSS score and the NIHSS score for all patients ($R = 0.827$; $p < 0.0001$) and for the 46 ischemic stroke patients ($R = 0.827$; $p < 0.0001$). Furthermore, if patients with an NIHSS score of 5–22 were considered to be candidates for tissue plasminogen activator therapy, a KPSS score of 3–9 could identify such patients with a sensitivity of 84% and a specificity of 93%.