

Vascular

# Progressive moyamoya syndrome associated with de novo formation of the ipsilateral venous and contralateral cavernous malformations: case report

Elke Januschek, MD<sup>a,c</sup>, Miki Fujimura, MD<sup>a,\*</sup>, Shunji Mugikura, MD<sup>b</sup>, Teiji Tominaga, MD<sup>a</sup>

Departments of <sup>a</sup>Neurosurgery and <sup>b</sup>Radiology, Tohoku University School of Medicine, Sendai 980-8574, Japan

<sup>c</sup>Department of Neurosurgery, Klinikum Offenbach GmbH, 63069 Offenbach, Germany

Received 9 November 2006; accepted 30 January 2007

## Abstract

**Background:** Association of moyamoya disease with multiple vascular malformations is extremely rare.

**Case Presentation:** A 33-year-old man, who had been affected with moyamoya syndrome with TIA during the past 3 years, was admitted to our hospital because of crescendo TIAs with numbness in his right hand and dysarthria. Magnetic resonance angiography showed apparent progression of the steno-occlusive changes bilaterally. We then planned surgical revascularization on the symptomatic side. At the time of readmission for surgery, an asymptomatic small intracerebral hemorrhage in the right frontal cortex was found, which presented on MRI as a CCM. Cerebral angiogram showed avascular lesion corresponding to the location of CCM as well as a newly formed venous malformation on the left side. One month later, STA-MCA anastomosis with pial synangiosis was performed without complications. Significant improvement in CBF on the left hemisphere was confirmed by postoperative single-photon emission CT. There were no ischemic changes on a postoperative MRI, and STA-MCA bypass was apparently patent by MRA. The TIA completely disappeared after surgery, and the patient was discharged without neurologic deficit. Persistence of the CCM and venous malformation were confirmed by T2\*-weighted image and 3-dimensional contrast-enhanced gradient echo/SWI 4 months after surgery, respectively.

**Conclusion:** The association of moyamoya syndrome with CCM and venous malformation is extremely rare. The coincidence of the progressive moyamoya syndrome with these newly formed vascular malformations may give a clue to the underlying mechanism of the progression of this rare entity.

© 2008 Elsevier Inc. All rights reserved.

## Keywords:

Moyamoya disease; Cerebral cavernous malformation; Venous malformation

*Abbreviations:* <sup>133</sup>Xe SPECT, Xenon 133-inhalation single-photon emission computed tomography; CBF, cerebral blood flow; CCM, cerebral cavernous malformation; CT, computed tomography; CVRC, cerebrovascular reserve capacity; DSA, digital subtraction angiography; MCA, middle cerebral artery; MIP, maximum intensity projection; MRA, magnetic resonance angiography; MRI, magnetic resonance imaging; MPRAGE, magnetization prepared rapid acquisition gradient-echo; PCA, posterior cerebral artery; STA, superficial temporal artery; SWI, susceptibility-weighted imaging; TIA, transient ischemic attack.

\* Corresponding author. Tel.: +81 22 717 7230; fax: +81 22 717 7233.

E-mail address: [fujimur@nsg.med.tohoku.ac.jp](mailto:fujimur@nsg.med.tohoku.ac.jp) (M. Fujimura).

## 1. Introduction

Moyamoya disease is a chronic, occlusive cerebrovascular disease with unknown etiology characterized by bilateral steno-occlusive changes at the terminal portion of the internal carotid artery and an abnormal vascular network at the base of the brain [13]. The association of moyamoya disease with further cerebrovascular diseases, such as aneurysms, has been described in the literature repeatedly [1,4,6,8], but simultaneous occurrence of moyamoya, CCM, and venous malformation has not been reported previously.

## 2. Case report

A 33-year-old man presented with transient weakness in his right limbs in June and September 2003 as well as in February 2004. These attacks recurred 1 to 3 times per month starting June 2004, and the patient was admitted to another hospital in July 2004. The MRA showed stenocclusive changes in the M1 portion of the left MCA. At the end of October 2004, the patient was readmitted to the hospital because of repeated TIAs. Therapy with aspirin was started with only a temporary effect. The DSA on November 11, 2004 (Fig. 1A–C), showed an occlusion of the left M1 and a slight stenosis of the right MCA with no further pathology. In addition, CVRC was reduced in the left hemisphere, so surgery was recommended, but the patient refused at that time. The follow-up MRI in November 2005 showed an asymptomatic infarction in the left basal ganglia. In February 2006, the patient presented with dysarthria and numbness in his right hand. Four months later, the repeated  $^{133}\text{Xe}$  SPECT indicated a process of decreasing CBF (right MCA,  $56.9 \text{ mL} \cdot 100 \text{ g}^{-1} \cdot \text{min}^{-1}$ ; left MCA,  $41.7 \text{ mL} \cdot$

$100 \text{ g}^{-1} \cdot \text{min}^{-1}$ ) as well as CVRC. Astonishingly, the CT showed an asymptomatic small intracerebral hemorrhage in the right frontal cortex, which resembled a CCM on T2\*-weighted imaging of MRI (Fig. 2B, arrow). So the planned surgery had to be postponed again. On August 2, 2006, one day after readmission to the hospital, the DSA on the left side demonstrated severe stenocclusion in the M1 portion with moyamoya vessels (Fig. 1E); subtotal occlusion in the PCA as well as a venous malformation (Fig. 1F), which had never been seen on DSA before; and progressive stenosis of the right M1 portion (Fig. 1D). The MRI with contrast-enhanced 3-dimensional fast spoiled gradient-echo confirmed the diagnosis of venous malformation (Fig. 2D, arrow). A fresh infarction or hemorrhage was excluded by MRI. Because there were no arteriovenous shunts, a left STA-MCA anastomosis with pial synangiosis was performed on August 8 without complications [2,3]. Significant improvement in CBF on the left hemisphere was confirmed by postoperative single-photon emission CT. There were no ischemic changes on a postoperative MRI (Fig. 3A and B), and

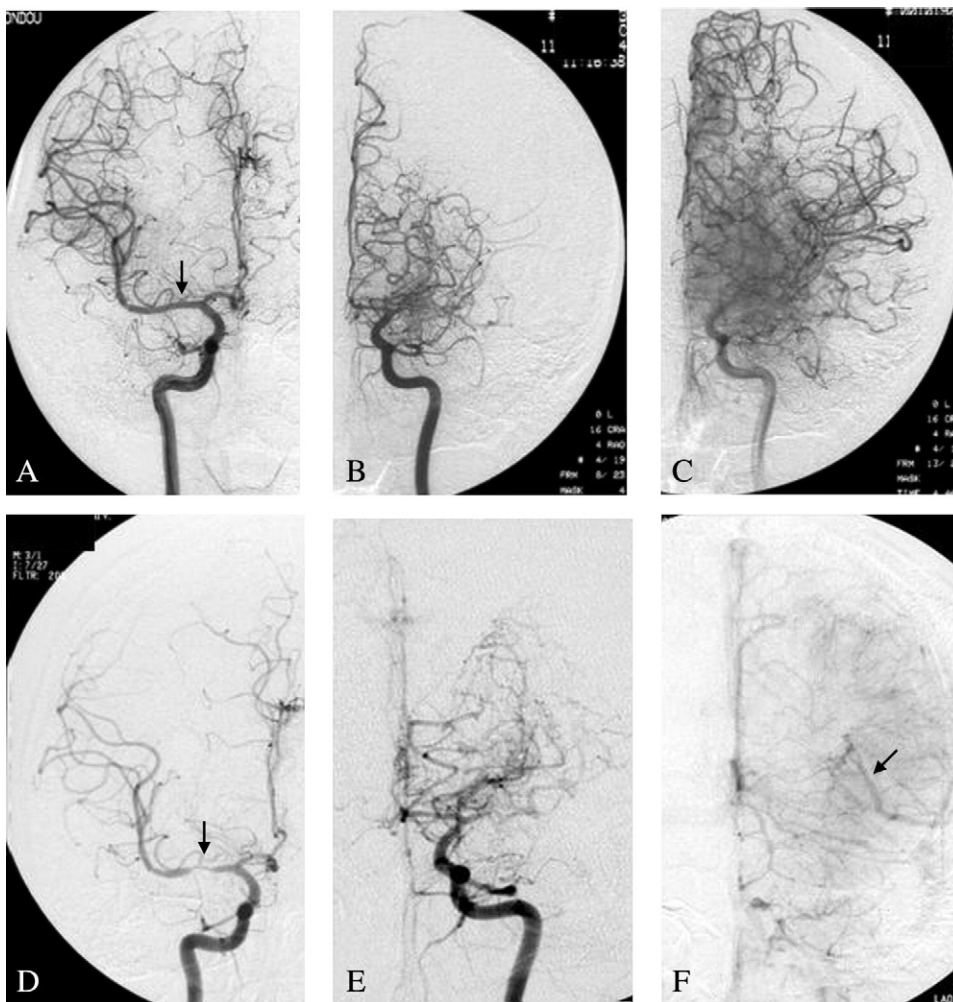


Fig. 1. In the DSA from November 11, 2004 (A–C), and August 2, 2006 (D–F), the progression of stenosis in the right MCA (A and D, arrow), the occlusion of the left MCA with moyamoya vessels (B and E), and the newly formed left venous malformation (F, arrow) were shown.

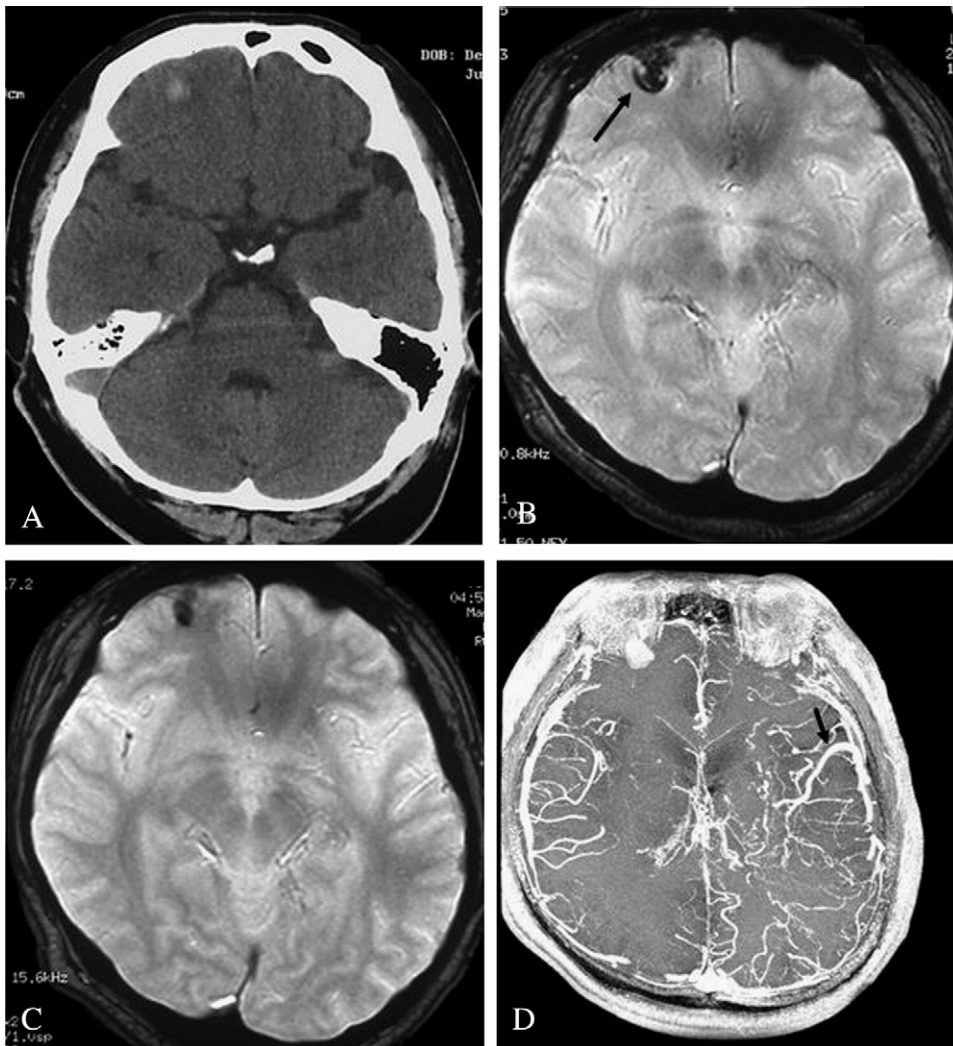


Fig. 2. The right frontal hemorrhage was found during the preoperative routinely diagnostic investigations. A: Native cranial CT: a small right frontal cortical hemorrhage is visually without mass effect. B: T2\*-weighted MRI shows the hypointense right frontal lesion. The signal and configuration suggest a CCM (arrow). C: T2\*-weighted imaging in time-dependent course. D: A partially collapsed MIP image of contrast-enhanced 3-dimensional fast spoiled gradient-echo demonstrates the characteristic caput medusae appearance of the venous malformation with enlarged medullary veins at the posterior part of the left insula. These veins finally converge to one large vein in the left sylvian fissure (arrow). The diagnosis of the venous malformation is made. Multiple curvilinear contrast enhancements corresponding to the moyamoya vessels are also shown at the left basal ganglia, and hyperintense mass corresponding to the CCN is also demonstrated in the right frontal region.

STA-MCA bypass was apparently patent by MRA (Fig. 3C, arrow). The TIA completely disappeared after surgery, and the patient was discharged without neurologic deficit. The patient did not experience TIA during the follow-up period, and MRI with contrast-enhanced 3-dimensional MPRAGE and SWI 4 months after surgery delineated the persistence of venous malformation (Fig. 4A and B, arrows). The persistence of CCM was also confirmed by T2\*-weighted imaging (Fig. 4C, arrow).

### 3. Discussion

At 1 case per million per year, the incidence of moyamoya disease in Japan is higher than in other countries [5]. In Europe, for example, there are only one tenth as

many cases per year [7,12]. On the other hand, familial moyamoya disease with autosomal-dominant inheritance and incomplete penetrance occurs in 9% of all cases in Japan [11,15]. Although moyamoya disease is characterized as progressive, this circumstance was believed to be very rare in adult patients. However, Kuroda and colleagues [9] established in their study a progression in 15 (23.8%) of 63 patients during the follow-up period. In our case, a follow-up over 2 years was done and showed the development of the stenosis in the right MCA as well as a venous malformation on the left side, which had never been seen on DSA before. We therefore confirm the allegation of Kuroda and colleagues [9] that disease progression in adult moyamoya disease might be more common than previously assumed [10].



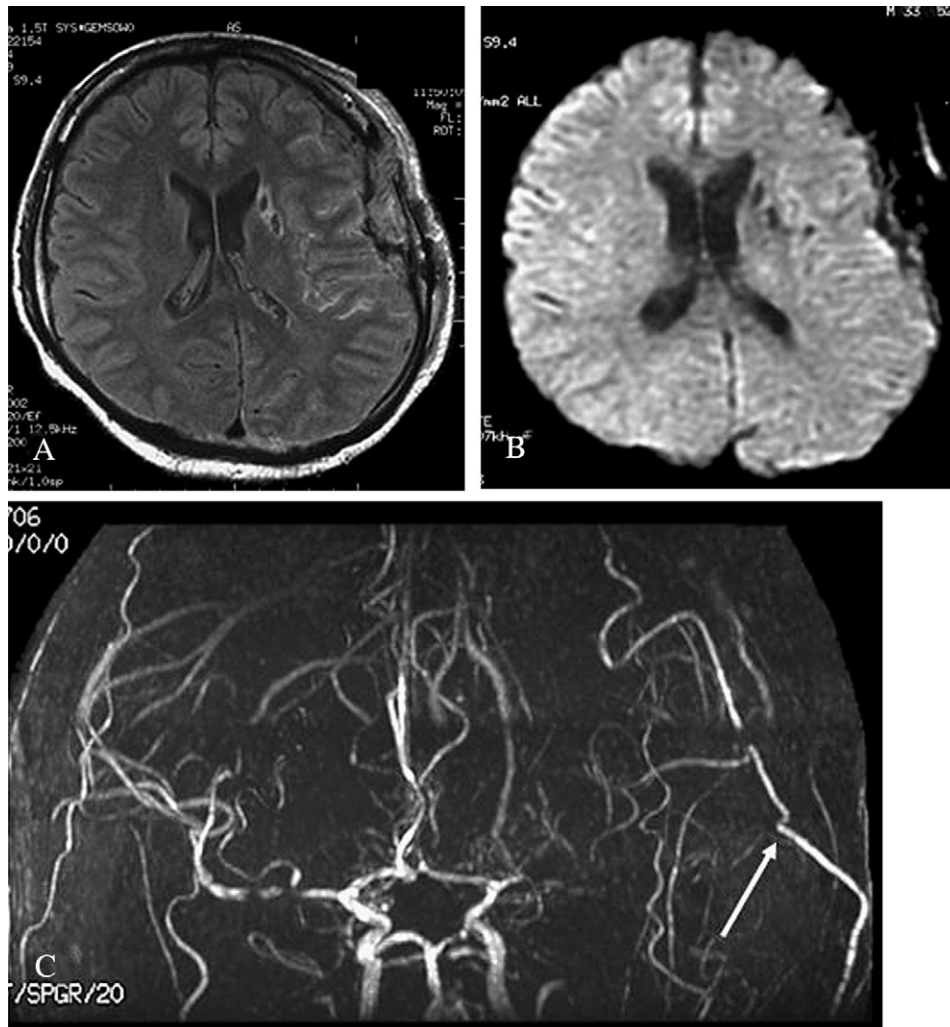


Fig. 3. Postoperative MRI and MRA. A: The fluid attenuated inversion recovery, revealing a slight laminar high-intensity sign. Left temporal as well as the residual defect in the area of the left basal ganglia after infarction in 2005. B: No ischemic change was detected by diffuse-weighted imaging. C: Superficial temporal artery-MCA bypass on the left side (arrow) is conspicuous on MRA.

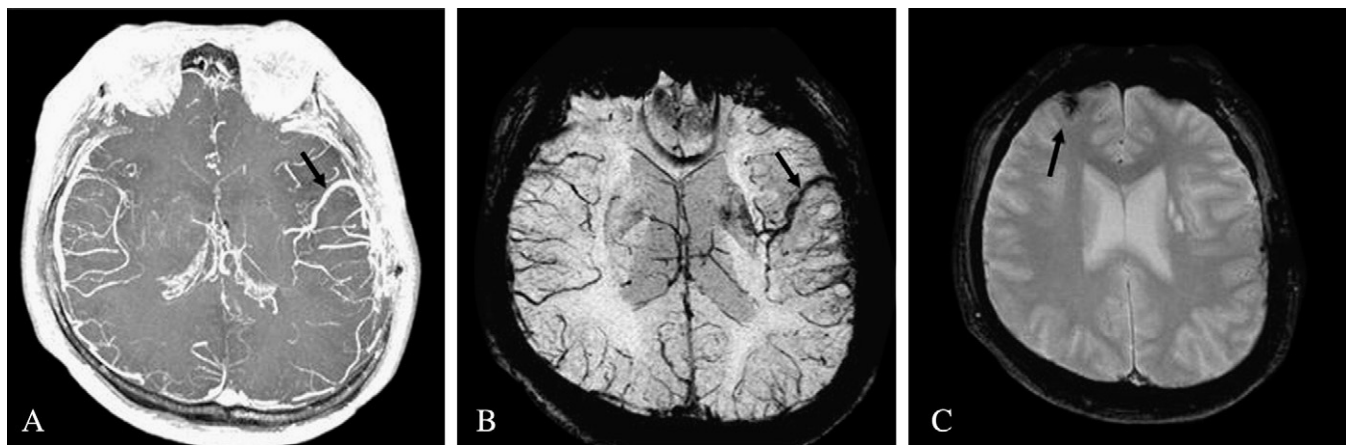


Fig. 4. Postoperative MRI 4 months after surgery. On a partially collapsed MIP image of contrast-enhanced 3-dimensional MPRAGE (A), curvilinear enhancements at the left basal ganglia decrease compared with the preoperative examination; however, the enlarged vascular structure representing the venous malformation remains almost unchanged (arrow). A susceptibility-weighted minimal-intensity projection image also shows the characteristic caput medusae appearance of the venous malformation with enlarged medullary veins and dilated veins in the sylvian fissure (B, arrow). Cerebral cavernous malformation at the right frontal region showing hypointensity remains unchanged on a T2\*-weighted image (C, arrow).

It is well known that moyamoya disease is frequently associated with intracranial aneurysms located within the abnormal basal network or the circle of Willis [4,8]. After performing STA-MCA bypass, not only were the TIA attacks reduced, but also in some cases, disappearance or reduction in size of the aneurysm was noticed. This may be a result of decreasing hemodynamic stress in the abnormal basal vascular network [14]. Regarding its association with vascular malformations, Kerchner and colleagues [6] reported a case of a young woman with co-occurrence of a CCM and contralateral moyamoya-like occlusion of the right MCA. In our case, we also found an occlusion of MCA with associated contralateral de novo CCM [10]. The right frontal CCM in our patient bled only once and was asymptomatic; thus, we decided not to remove it and to postpone the STA-MCA surgery. In addition to de novo CCM formation, the DSA showed a newly developed venous malformation on the left side. There were no angiographic hints of arteriovenous malformation; thus, we assumed only a minimum risk for bleeding by postoperative increase in CBF after ipsilateral bypass surgery. In fact, a left STA-MCA anastomosis with indirect bypass was performed without complications, and the TIAs completely disappeared after surgery.

#### 4. Conclusion

We reported, for the first time, a case of progressive moyamoya syndrome associated with various vascular abnormalities such as the de novo CCM and venous malformation. The T2\*-weighted imaging, contrast-enhanced 3-dimensional gradient echo, and SWI were useful for evaluating the association between CCM and venous malformation. The STA-MCA anastomosis with pial synangiosis was performed on the symptomatic side without complications, which completely relieved TIAs postoperatively. We suggest that surgical revascularization can be performed even on the side of the venous malformation as long as the patients have ischemic symptoms and present flow compromise on the symptomatic side.

#### References

- [1] Adams Jr HP, Kassell NF, Wisoff HS, Drake CG. Intracranial saccular aneurysm and moyamoya disease. *Stroke* 1979;10:174-9.
- [2] Fujimura M, Mugikura S, Shimizu H, Tominaga T. Diagnostic value of perfusion-weighted MRI for postoperative alteration of cerebral hemodynamics following STA-MCA anastomosis in patients with moyamoya disease. *No Shinkei Geka* 2006;34:801-9.
- [3] Fujimura M, Kaneta T, Mugikura S, Shimizu H, Tominaga T. Temporary neurological deterioration due to cerebral hyperperfusion after superficial temporal artery–middle cerebral artery anastomosis in patients with adult-onset moyamoya disease. *Surg Neurol* 2007;67:273-82.
- [4] Furuse S, Matsumoto S, Tanaka Y, Ando S, Sawa H, Ishikawa S. Moyamoya disease associated with a false aneurysm—case report and review of the literature. *No Shinkei Geka* 1982;10:1005-12.
- [5] Ikeda K, Iwasaki Y, Kashiwara H, Hosozawa K, Anan K, Tamura M, Satoyoshi E, Ikeda H. Adult moyamoya disease in the asymptomatic Japanese population. *J Clin Neurosci* 2006;13:334-8.
- [6] Kerchner GA, Smith W, Lawton MT, Singh V. Co-occurrence of a cavernous malformation and contralateral moyamoya. *Neurology* 2006;66:1601-2.
- [7] Khan N, Yonekawa Y. Moyamoya angiopathy in Europe. *Acta Neurochir Suppl* 2005;94:149-52.
- [8] Konishi Y, Kadowaki C, Hara M, Takeuchi K. Aneurysm associated with moyamoya disease. *Neurosurgery* 1985;16:484-91.
- [9] Kuroda S, Ishikawa T, Houkin K, Nanba R. Incidence and clinical features of disease progression in adult moyamoya disease. *Stroke* 2005;36:2148-53.
- [10] Ludemann W, Ellerkamp V, Stan AC, Hussein S. De novo development of a cavernous malformation of the brain: significance of factors with paracrine and endocrine activity: case report. *Neurosurgery* 2002;50:646-9.
- [11] Mineharu Y, Takenaka K, Yamakawa H, Inoue K, Ikeda H, Kikuta K, Nozaki K, Hashimoto N, Koizumi A. Inheritance pattern of familial moyamoya disease: autosomal dominant mode and genomic imprinting. *J Neurol Neurosurg Psychiatry* 2006;77:1025-9.
- [12] Reis CV, Safavi-Abbasi S, Zabramski JM, Gusmao SN, Spetzler RF, Preul MC. The history of neurosurgical procedures for moyamoya disease. *Neurosurg Focus* 2006;20:E7.
- [13] Suzuki J, Takaku A. Cerebrovascular ‘moyamoya’ disease. Disease showing abnormal net-like vessels in base of brain. *Arch Neurol* 1969;20:288-99.
- [14] Takahashi M, Fujimoto T, Suzuki R, Asai J, Miyo T, Hokaku H. A case of spontaneous middle cerebral artery occlusion associated with a cerebral aneurysm angiographically disappearing after STA-MCA anastomosis. *No Shinkei Geka* 1997;25:727-32.
- [15] Yamauchi T, Tada M, Houkin K, Tanaka T, Nakamura Y, Kuroda S, Abe H, Inoue T, Ikezaki K, Matsushima T, Fukui M. Linkage of familial moyamoya disease (spontaneous occlusion of the circle of Willis) to chromosome 17q25. *Stroke* 2000;31:930-5.