

## Stent placement for management of a small parasagittal meningioma

### Technical note

DHARMENDRA GANESAN, M.S., F.R.C.S.,<sup>1</sup> J. NICHOLAS P. HIGGINS, F.R.C.P., F.R.C.R.,<sup>2</sup> TIMOTHY HARROWER, PH.D., M.R.C.P.,<sup>1</sup> NEIL G. BURNET, F.R.C.S., F.R.C.R., M.D.,<sup>3</sup> NICHOLAS J. C. SARKIES, M.A., M.R.C.P., F.R.C.OPTH.,<sup>4</sup> MARK MANFORD, M.D., F.R.C.P.,<sup>1</sup> AND JOHN D. PICKARD, M.CHIR., F.R.C.S., F.MED.SCI.<sup>1</sup>

<sup>1</sup>Academic Neurosurgical Unit and Neurology Unit, Department of Neurosciences, and <sup>2</sup>Department of Radiology, University of Cambridge; and Departments of <sup>3</sup>Oncology and <sup>4</sup>Ophthalmology, Addenbrooke's Hospital, Cambridge, United Kingdom

✓The patient in this report had a parasagittal meningioma with an intrasinus extension that presented with features of benign intracranial hypertension and no focal neurological deficit or seizure. The meningioma was managed with a combination of endovascular stent placement and radiotherapy. The authors describe the investigation and technical aspects of stent placement for the stenosed sinus. Good symptomatic relief in the patient was achieved. (DOI: 10.3171/JNS/2008/108/2/0377)

**KEY WORDS** • endovascular surgery • intracranial hypertension • parasagittal meningioma • radiotherapy • stent placement

THE management of a parasagittal meningioma has always been a challenge for the neurosurgeon, especially when the meningioma is located in the posterior two thirds of the SSS. We present a novel approach that combines endovascular stent placement and radiotherapy in the management of a small parasagittal meningioma with an intrasinus extension.

### Illustrative Case

This 46-year-old hypertensive male presented with a history of intermittent headaches of 2 years' duration and progressive deterioration of visual acuity for 1 year. At presentation, his visual acuity with correction was 6/18 on the right and 6/36 on the left. Marked bilateral papilledema with hemorrhages of the left disc margin was observed. Visual field assessment in the patient showed a constricted visual field and an enlarged blind spot. An MR image of the brain revealed an intracranial mass with features consistent

with a parasagittal meningioma (widest axial diameter = 17 mm) arising from the posterior third of the SSS with a significant intraluminal component (Fig. 1). Magnetic resonance venography revealed a significant stenosis of the posterior SSS that was confirmed by the venous phase of the formal angiogram (Fig. 2). An opening CSF pressure of 41 cm H<sub>2</sub>O was recorded at the lumbar puncture.

The patient underwent endovascular stent placement in the stenotic segment. Three months after stent placement, his headache had resolved and his visual acuity had improved to 6/9 on the right and 6/24 on the left. The visual fields improved but the papilledema and choroidal folds persisted, albeit less severely compared with that observed at presentation. He subsequently underwent radiotherapy, receiving 55 Gy in 33 fractions over 6.5 weeks. At 6 months after stent placement his visual acuity had improved to 6/6 on the right and 6/18 on the left with persistence of papilledema and choroidal folds. At the 8-month follow-up, he remains without headaches, with visual acuity of 6/6 on the right and 6/36 on the left, with atrophic discs and left choroidal folds. The atrophic discs could be the consequence of chronic papilledema.

Abbreviations used in this paper: CSF = cerebrospinal fluid; MR = magnetic resonance; SSS = superior sagittal sinus.

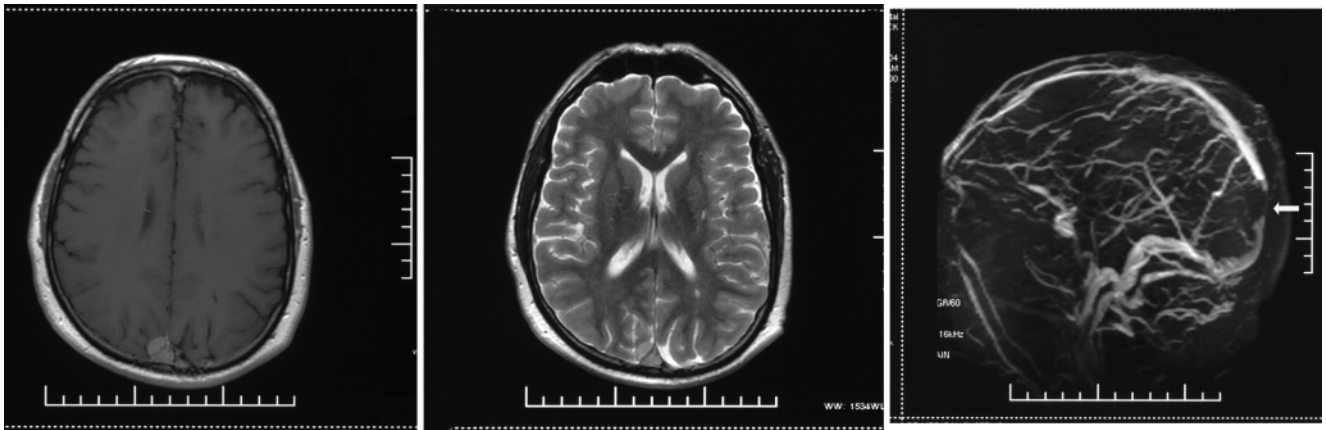


FIG. 1. Preoperative images of the tumor in the SSS. Axial T1-weighted MR image after contrast administration (*left*) and a T2-weighted MR image (*center*) show the parasagittal tumor involving the SSS. An MR venogram (*right*) shows loss of signal in the posterior segment of the SSS at the site of the tumor (*arrow*).

### Operative Technique

To confirm the site and significance of the stenosis noted on the MR venogram and conventional angiography, direct venography was first performed after induction of local anesthesia. In this procedure, a Rebar-27 microcatheter (MTI Corporation) supported by a 4-F catheter in the right internal jugular vein (from femoral puncture) was passed over a guidewire into the lateral sinus and then across the stenosis into the sagittal sinus. Sagittal sinus pressure upstream of the stenosis was 43 mm Hg and downstream was 14 mm Hg, with a jugular bulb pressure of 12 mm Hg.

Following induction of anesthesia, an 8-F sheath was inserted through the left internal jugular vein and used to pass a Guider 8-F guide catheter (Boston Scientific) into the SSS. This catheter was used to direct an Omnilink.018 balloon-mounted stent (Guidant) across the stenosis over a

guide wire. The stent was deployed by balloon inflation and the delivery system was withdrawn. Immediately after stent placement, venography showed good flow in the SSS (Fig. 3). The patient received heparin during the procedure, which was subsequently converted to warfarin, and then to low-dose aspirin after 8 weeks. At 6 months, the venography appearances were unchanged from the immediate post-operative results, with an upstream pressure of 9 mm Hg and a downstream and jugular bulb pressure of 7 mm Hg. The opening CSF pressure via lumbar puncture was 18 cm H<sub>2</sub>O. The patient also underwent computed tomography venography at the same time as part of this assessment, which incidentally showed that the tumor was unchanged. An MR image, obtained 9 months after radiotherapy, showed a stable appearance of the meningioma. Catheter venography at 14 months showed that the stent was widely patent with a 1 mm Hg pressure gradient (Fig. 4).

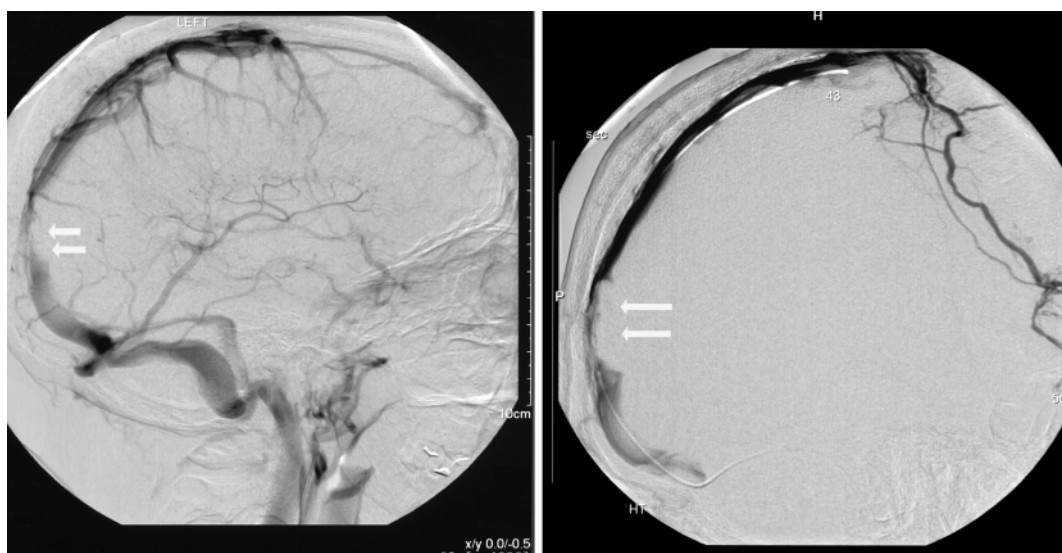


FIG. 2. Preoperative images of the SSS. *Left*: A cerebral arteriogram (lateral view) shows the stenosed segment of the SSS (*arrows*). *Right*: A retrograde venogram (lateral view) shows the SSS opacified directly by the venous catheter (*arrows*).

## Stent placement for a parasagittal meningioma

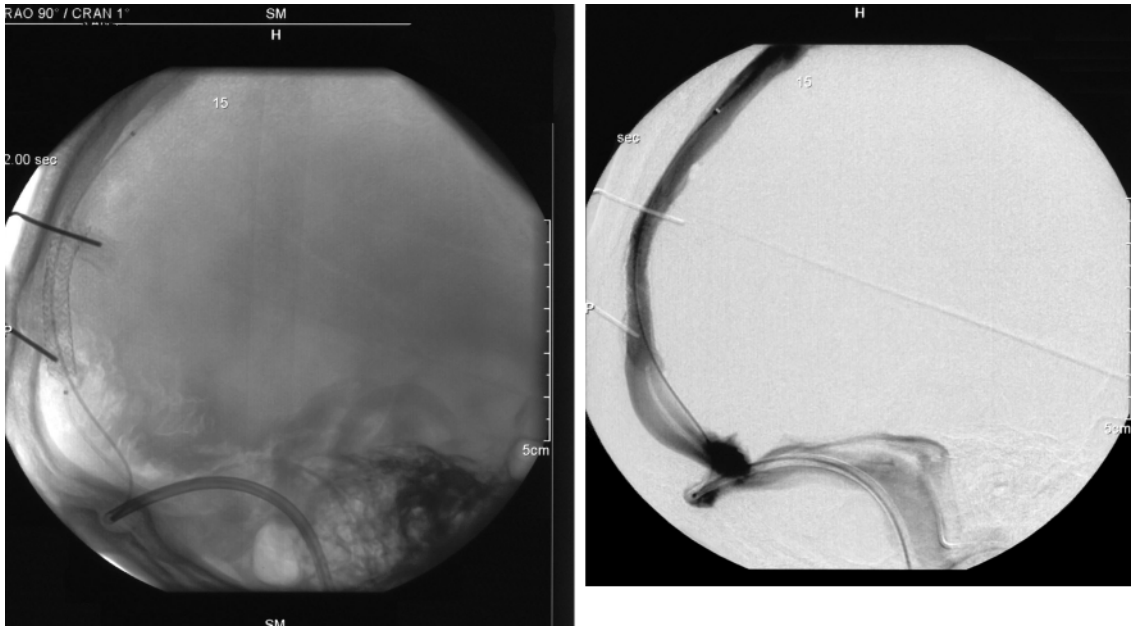


FIG. 3. Intraoperative retrograde venograms showing the placement of the fully expanded stent within the stenosis (*left*) and good flow of contrast material across the patent sinus after the stenting procedure (*right*).

### Discussion

Parasagittal meningiomas arise adjacent to the SSS and frequently occur in the middle-third of this area. The presentation of these tumors varies from headaches, to seizures, to monoplegia, to cognitive changes. The particular problem posed by this type of meningioma is its intimate involvement with the sinus and sometimes with the draining cortical veins.

The degree of invasion by the parasagittal meningioma of the sinus was classified by Sindou<sup>17</sup> and Auque<sup>18</sup> into 6 types (Fig. 5), which is a simplified classification derived from Merrem<sup>10</sup> and Bonnal and Brotchi.<sup>2</sup> The preferred option in the treatment of such a meningioma has always been complete excision leaving a cuff of normal dura mater when feasible. This procedure can be a formidable task in these cases, however, depending on the extent of sinus invasion. Advances in microsurgical technique have allowed difficult excisions to be attempted more safely, but there is still a risk that damage to the venous drainage may lead to venous infarction. This risk may be reduced by venous reconstruction after excision.<sup>1-3,9,17,18</sup> Tumor recurrence rates after excision vary from 2.5 to 24%.<sup>17,18</sup>

Endovascular treatment has emerged as a minimally invasive approach to many intracranial lesions, with cerebrovascular disease the likeliest target of this type of treatment.<sup>15</sup> Stent placement in the venous sinus has been suggested as an alternative approach to the neurosurgical treatment of idiopathic intracranial hypertension with coexisting focal venous sinus stenosis.<sup>5,6</sup> Hunt and associates<sup>7</sup> reported the utilization of angioplasty and endovascular stent placement across a thrombosed venous sinus in 2 patients with papilledema and visual loss, which resulted in improvement in optic disc edema and visual function.<sup>7</sup>

Our report describes a patient harboring a small parasagittal meningioma with an intrasinus component that

presented with features of idiopathic intracranial hypertension. These features manifested as persistent headaches with visual disturbances, without other focal neurological symptoms or seizures. The meningioma could be classified as Type IV or V according to the classification system of Sindou<sup>17</sup> and Auque.<sup>18</sup>

The standard surgical approach to this problem would be a CSF diversion procedure to relieve the raised intracranial

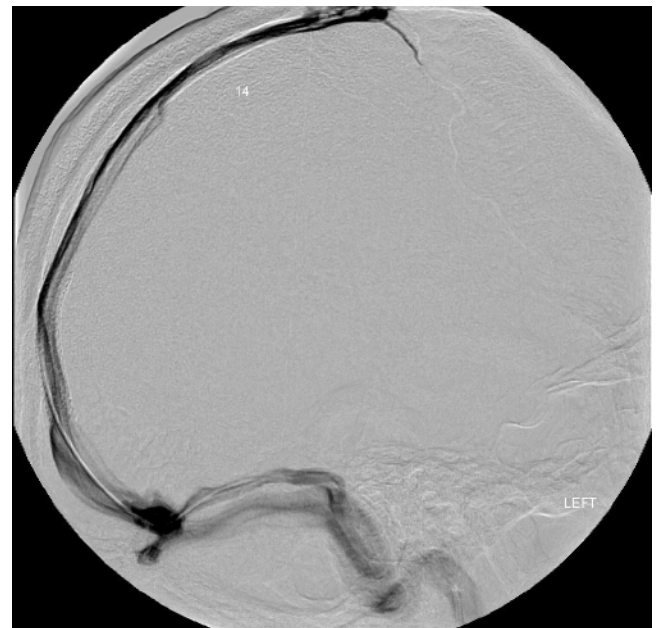


FIG. 4. Retrograde venogram (lateral view) at 14 months shows good flow of blood through the SSS and stent.

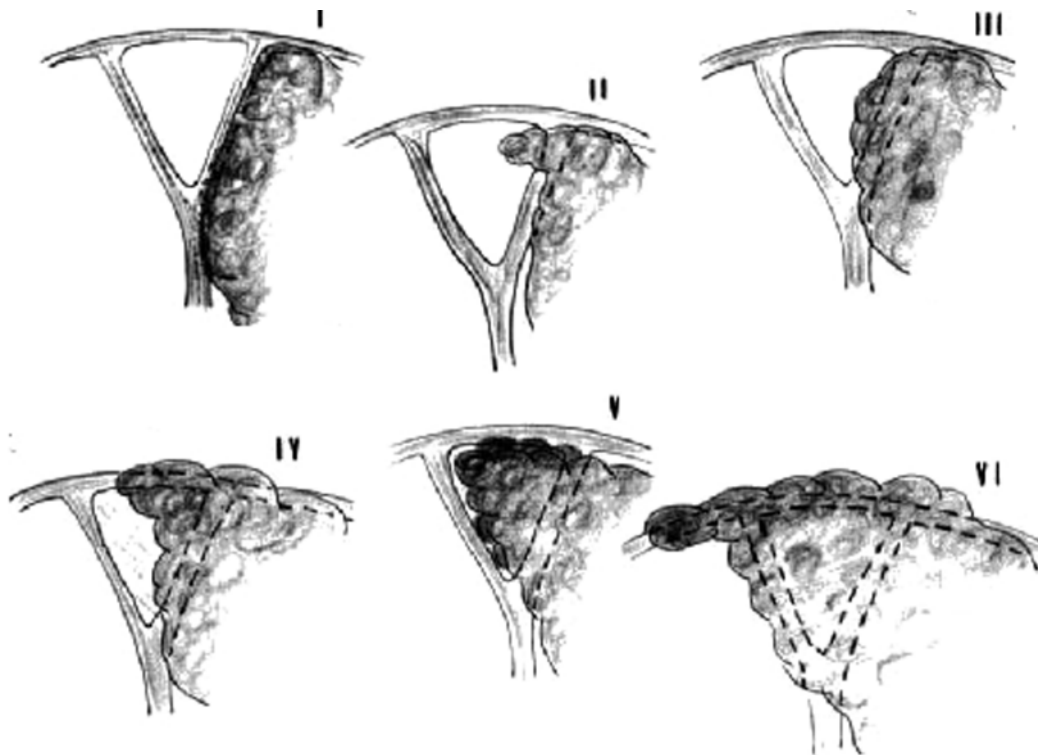


FIG. 5. Illustrations of the different types and classifications of meningioma (I–VI) according to the degree of dural venous sinus involvement. Type I: Meningioma attached to outer surface of the sinus wall. Type II: Invasion of the lateral recess. Type III: Invasion of the lateral wall. Type IV: Invasion of both the entire lateral wall and roof of the sinus. Types V and VI: Sinus totally occluded, one wall free of tumor in Type V. This classification is simplified from those of Krause and Mermer and Bonnal and Brotchi. Reprinted with permission from Sindou and Auque, *Advances and Technical Standards in Neurosurgery*, SpringerWien, 2000.

pressure, which would be expected to give good palliation. A case with a similar presentation and tumor location was reported in Japan. In that case, the investigators treated the patient by excising only the extraluminal component of the tumor and inserting a ventriculoperitoneal shunt that resolved the headache and visual symptoms.<sup>19</sup>

The insertion of a shunt, however, has a recognized complication rate and is especially difficult when the ventricles are small. Use of an endovascular approach offered the opportunity to directly address the cause of raised intracranial pressure, and alleviation of the venous outflow obstruction resulted in an immediate decrease in intrasinus pressure to the normal range. Stent placement was successful perhaps because the intrasinus lesion was small and perhaps because it involved only one wall of the sinus. It is interesting to observe that despite the presence of a tumor, the stent was able to expand uniformly and thus produce a good lumen for blood flow, completely relieving the vascular obstruction.

Similar to shunting procedures, stent placement does not by itself allow a definitive histopathological diagnosis, which precludes a definition of the precise type of meningioma, the mitotic index, and, therefore, an indication of prognosis and recurrence rate. Our patient subsequently received radiotherapy, with the empirical aim of stabilizing the disease process and possibly promoting tumor regression.

Another aspect to consider is how the stent might affect future treatment if the tumor progresses. If the sinus becomes occluded, then the surgical problems are familiar. If the sinus remains patent, then excision of the tumor might even be facilitated because the continuity of the sinus would be maintained by the stent. Therefore, the lumen of the sinus might not be exposed directly, thereby minimizing blood loss and the need to restore sinus continuity, as well as reducing the risk of venous infarction.

The recent trend in the management of meningiomas is to employ a multidisciplinary approach. Radiosurgery has been shown to be an effective management strategy for many patients with meningioma.<sup>4,13,20</sup> Pollock and associates<sup>14</sup> demonstrated in their patient series that use of stereotactic radiosurgery for small-to-medium benign intracranial meningiomas (average diameter < 35 mm) facilitated progression-free survival equivalent to that after a Simpson Grade I resection of a tumor at a mean follow-up of 64 months. Fractionated stereotactic radiotherapy is also highly effective in the control of meningiomas with low toxicity.<sup>11</sup> Nonsurgical methods such as embolization of the tumor and hormonal manipulation have proven to be beneficial as well.<sup>12,16</sup> Other medical treatments, such as the use of hydroxyurea and interferon, have also been shown to stabilize tumor size in recurrent and unresectable tumors,<sup>8</sup> but randomized controlled trials are required to define the role of these treatments. This case illustrates the combined

## Stent placement for a parasagittal meningioma

approach of endovascular therapy and radiotherapy in the management of a parasagittal meningioma.

### Conclusions

We describe stent placement in the initial management of an intraluminal SSS meningioma. Along with adjuvant radiotherapy, the operative technique provided the patient with symptomatic relief that has been sustained over a 14-month follow-up period. The long-term outcome will need to be monitored with regard to tumor growth and sinus patency.

### References

1. Bederson JB, Eisenberg MB: Resection and replacement of the superior sagittal sinus for treatment of a parasagittal meningioma: technical case report. **Neurosurgery** **37**:1015–1019, 1995
2. Bonnal J, Brotchi J: Surgery of the superior sagittal sinus in parasagittal meningiomas. **J Neurosurg** **48**:935–945, 1978
3. Hakuba A, Huh CW, Tsujikawa S, Nishimura S: Total removal of a parasagittal meningioma of the posterior third of the sagittal sinus and its repair by autogenous vein graft. Case report. **J Neurosurg** **51**:379–382, 1979
4. Harris AE, Lee JY, Omalu B, Flickinger JC, Kondziolka D, Lunsford LD: The effect of radiosurgery during management of aggressive meningiomas. **Surg Neurol** **60**:298–305, 2003
5. Higgins JN, Cousins C, Owler BK, Sarkies N, Pickard JD: Idiopathic intracranial hypertension: 12 cases treated by venous sinus stenting. **J Neurol Neurosurg Psychiatry** **74**:1662–1666, 2003
6. Higgins JN, Owler BK, Cousins C, Pickard JD: Venous sinus stenting for refractory benign intracranial hypertension. **Lancet** **359**:228–230, 2002
7. Hunt MG, Lee AG, Kardon RH, Lesley WS, Chaloupka JC: Improvement in papilledema and visual loss after endovascular stent placement in dural sinus thrombosis. **Neuroophthalmology** **26**:85–92, 2001
8. Mason WP, Gentili F, Macdonald DR, Hariharan S, Cruz CR, Abrey LE: Stabilization of disease progression by hydroxyurea in patients with recurrent and unresectable meningioma. **J Neurosurg** **97**:341–346, 2002
9. Menovsky T, De Vries J: Cortical vein end-to-end anastomosis after removal of a parasagittal meningioma. **Microsurgery** **22**:27–29, 2002
10. Merrem G: [Parasagittal meningiomas. Fedor Krause memorial lecture.] **Acta Neurochir (Wien)** **23**:203–216, 1970 (Ger)
11. Milker-Zabel S, Zabel A, Schulz-Ertner D, Schlegel W, Wannenmacher M, Debus J: Fractionated stereotactic radiotherapy in patients with benign or atypical intracranial meningioma: long-term experience and prognostic factors. **Int J Radiat Oncol Biol Phys** **61**:809–816, 2005
12. Nelson PK, Setton A, Choi IS, Ransohoff J, Berenstein A: Current status of interventional neuroradiology in the management of meningiomas. **Neurosurg Clin N Am** **5**:235–259, 1994
13. Ojemann SG, Sneed PK, Larson DA, Gutin PH, Berger MS, Verhey L, et al: Radiosurgery for malignant meningioma: results in 22 patients. **J Neurosurg** **93** (3 Suppl):62–67, 2000
14. Pollock BE, Stafford SL, Utter A, Giannini C, Schreiner SA: Stereotactic radiosurgery provides equivalent tumor control to Simpson Grade I resection for patients with small- to medium-size meningiomas. **Int J Radiat Oncol Biol Phys** **55**:1000–1005, 2003
15. Qureshi AI: Endovascular treatment of cerebrovascular diseases and intracranial neoplasms. **Lancet** **363**:804–813, 2004
16. Sharif S, Brennan P, Rawluk D: Non-surgical treatment of meningioma: case report and review. **Br J Neurosurg** **12**:369–372, 1998
17. Sindou M: Meningioma invading the sagittal or transverse sinuses, resection with venous reconstruction. **J Clin Neurosci** **8** (1 Suppl):8–11, 2001
18. Sindou M, Auque J: The intracranial venous system as a neurosurgeon's perspective, in Cohadon F, Dolenc VV, Antunes JL, et al: **Advances and Technical Standards in Neurosurgery**. New York: SpringerWien, 2000, Vol 26, pp 131–218
19. Soma M, Munemoto S, Kuroda E, Hamada Y, Mouri M: [Parasagittal meningioma growing in the superior sagittal sinus presenting intracranial hypertension: a case report.] **No Shinkei Geka** **24**:165–168, 1996 (Jpn)
20. Stafford SL, Pollock BE, Foote RL, Link MJ, Gorman DA, Schomberg PJ, et al: Meningioma radiosurgery: tumor control, outcomes, and complications among 190 consecutive patients. **Neurosurgery** **49**:1029–1039, 2001

Manuscript submitted May 30, 2006.

Accepted March 28, 2007.

Address correspondence to: J. Nicholas P. Higgins, F.R.C.P., F.R.C.R., Box 218, Department of Radiology, Addenbrooke's NHS Trust, Hills Road, Cambridge CB2 2QQ, United Kingdom. email: nick.higgins@addenbrookes.nhs.uk.