

Hyperostosis frontalis interna in a patient with giant cell arteritis

Hilal Kocabas · Ilhan Sezer · Meltem Alkan Melikoglu ·
Ulku Gurbuz · Ozge Illeez · Irem Hicran Ozbudak ·
Bulent Butun

Received: 26 March 2007 / Accepted: 7 October 2007 / Published online: 6 February 2008
© Japan College of Rheumatology 2008

Abstract Hyperostosis frontalis interna (HFI) is a disorder characterized by progressive symmetric thickening of the inner table of the frontal bone of the human skull. HFI may be accompanied by headache and some neuropsychiatric diseases such as epilepsy and dementia. Giant cell arteritis (GCA), also called temporal arteritis, is a systemic inflammatory vasculitis of unknown etiology that affects medium- and large-sized arteries. It affects elderly people and may result in a wide variety of systemic, neurologic and ophthalmologic complications. As no association of HFI and GCA was encountered in the literature, we found it interesting to report a case with both of these clinical entities.

Keywords Headache · Hyperostosis frontalis interna · Giant cell arteritis

Introduction

Hyperostosis frontalis interna (HFI) is a disorder characterized by progressive symmetric thickening of the inner table of the frontal bone of the human skull [1]. HFI was first described by Morgagni more than 200 years ago [2]. It has been reported in high frequency among

postmenopausal elderly women. It was initially found in association with virilism and obesity, but now is considered as an independent entity [3]. HFI may accompany headache and some neuropsychiatric diseases such as epilepsy and dementia [4].

Giant cell arteritis (GCA), also called temporal arteritis, cranial arteritis, and granulomatous arteritis, is a systemic inflammatory vasculitis of unknown etiology that affects medium- and large-sized arteries. It is a disease of elderly people and may result in a wide variety of systemic, neurologic, and ophthalmologic manifestations such as headaches, arthralgias and myalgias, scalp or temporal tenderness, swollen, nodular or tender temporal arteries, fever, anorexia, malaise, weight loss, loss of vision, and jaw claudication [5–9].

As no association of HFI and GCA was encountered in the literature, we found it interesting to report a case with both of these clinical entities.

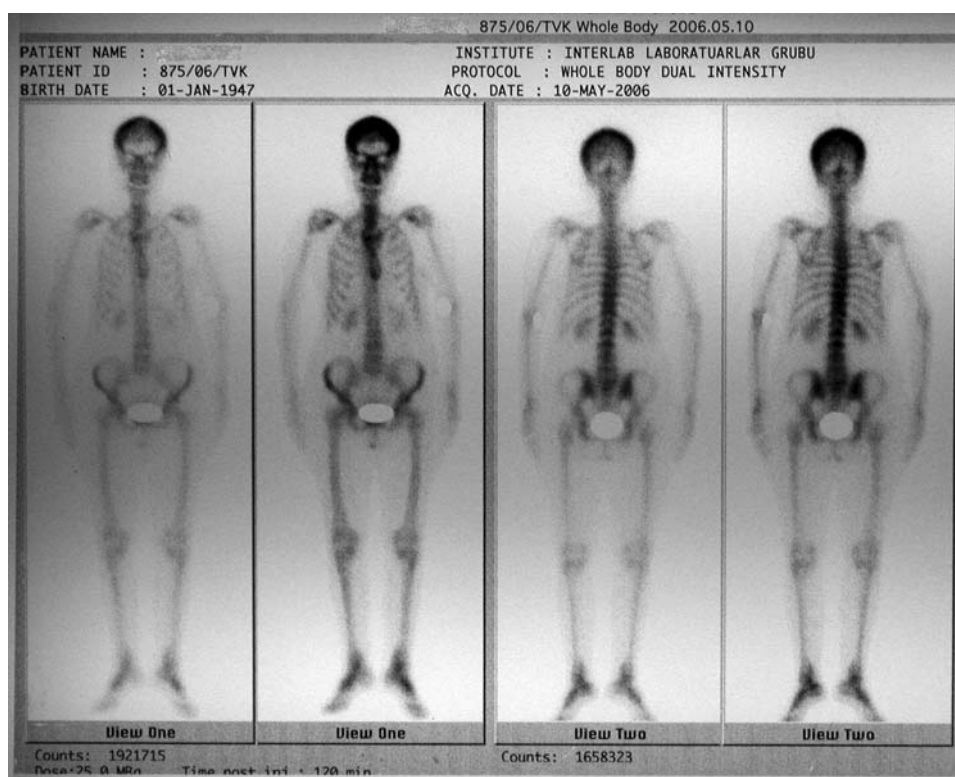
Case report

A 58-year-old woman with a history of generalized headache and scalp tenderness over the temporal area was referred to our department for further investigation. Initially she was admitted to another hospital with the same complaints, and in the evaluations her headache was attributed to frontal thickening on her skull X-rays. Her symptoms and radiographic findings prompted us to further investigations, and bone scintigraphy was revealed. It showed increased uptake in the skull bone, shoulder, sternal bone, sacroiliac joints, and both foot joints (Fig. 1). She had no complaint about the shoulders, sternum and sacroiliac joints. The scintigram was consistent with HFI, and her headache was attributed to this diagnosis. She was

H. Kocabas (✉) · I. Sezer · M. A. Melikoglu · U. Gurbuz ·
O. Illeez · B. Butun
Department of Physical Medicine and Rehabilitation,
School of Medicine, Akdeniz University,
07058 Antalya, Turkey
e-mail: hllkocabas@yahoo.com

I. H. Ozbudak
Department of Pathology, School of Medicine,
Akdeniz University, Antalya, Turkey

Fig. 1 Bone scintigram of our patient shows positive uptake in the shoulder, sternum, sacroiliac joints, both foot joints, and inner table of the skull



treated with paracetamol 1,000 mg per day. In her control 1 month later at this administration, she reported the remaining complaint of headache. A detailed history revealed temporary vision loss and jaw claudication, especially while chewing food. Ten years ago she had had a myocardial infarction. The laboratory examination showed an erythrocyte sedimentation rate (ESR) of 117 mm/h and C-reactive protein (CRP) of 3.84 mg/dl. No focus of infection was found. A gynecologic examination did not reveal any pathological finding. The presence of temporal tenderness, jaw claudication, temporary vision loss, elevated ESR and CRP led us to the suspicion of GCA, and a temporal artery biopsy was taken. Histopathological examination showed multinucleated giant cells, which were consistent with GCA (Fig. 2a, b). She was diagnosed as having GCA and treated with prednisolone 40 mg per day, p.o. She became asymptomatic at the end of the 1st month of the treatment.

Discussion

HFI has been reported in 5–12% of the general population [10], but is far more common in women than men [11]. An association between HFI and elderly postmenopausal women has been shown in previous studies; the incidence in this population has been defined to be 40–60% [10]. HFI has been associated with many conditions, including

frontal headaches, psycho-neurosis, obesity, pregnancy, acromegaly, virilism, hypertrichosis, and diabetes [12–15]. Our patient was a 58-year-old postmenopausal woman, complaining of headache.

GCA is the most common form of systemic vasculitis in the elderly. The most encountered symptoms are: new onset and unaccustomed headache, jaw claudication, proximal myalgia, weight loss, and fever. Because of the permanent vision loss possibility, the most important involvement of the disease is ophthalmologic involvement. A number of laboratory values (increased levels of ESR, CRP, fibrinogen, cardiolipin antibodies, and thrombocyte count), although none of them is diagnostic, may support the diagnosis of GCA. Temporal artery biopsy is the gold standard for diagnosis of GCA. In our patient's history she had temporary vision loss and jaw claudication. Also ESR and CRP levels were found to be elevated. Finally, her temporal artery biopsy demonstrated the diagnosis of temporal arteritis.

Bone scintigram of our patient showed the positive uptake in the bone of the skull, shoulder, and sternum in addition to the involvement of both foot and sacroiliac joints. This form of the uptake may have evoked SAPHO syndrome in our patient. Synovitis, acne, pustulosis, hyperostosis, and osteitis (SAPHO) syndrome is a chronic disorder combining skin, bone, and joint manifestations [16]. Bone lesions most commonly affect the anterior chest wall, sternum, clavicles, and ribs. The axial skeleton (spine

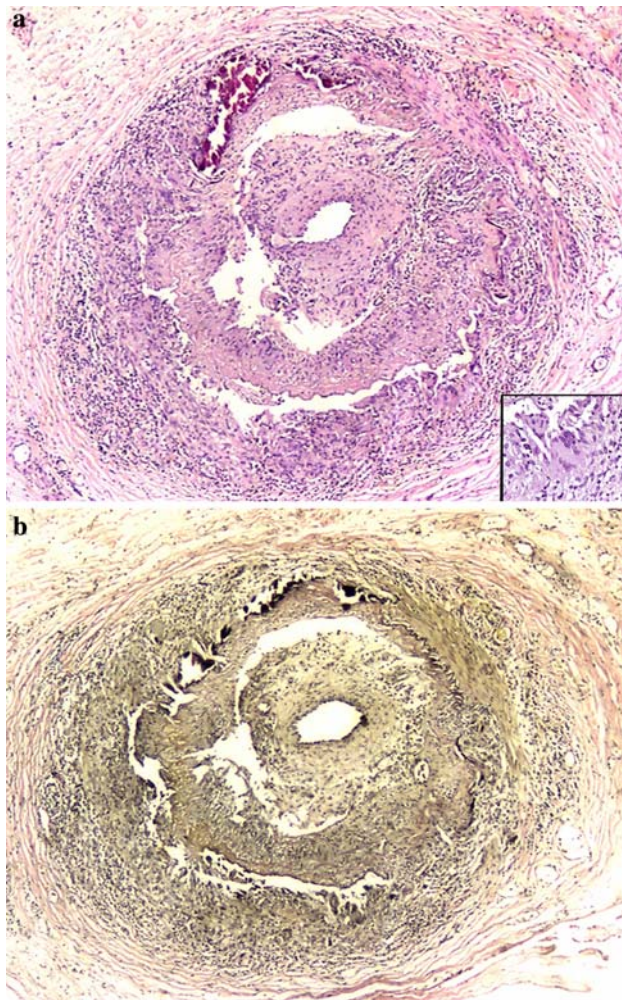


Fig. 2 Low-power view of a cross-section of the artery shows medial calcinosis, an inflammatory infiltrate with lymphocyte predominance in the media and intimal fibrosis, which causes the luminal narrowing. There is an irregular disruption of the media at the level of the internal elastic lamina, and multinucleated giant cells (*inset*) are seen in this area. **a** H&E, **b** Elastic Von Gieson

and sacroiliac joints) and peripheral bones can also be involved. Skin involvement includes palmoplantar pustulosis, pustular psoriasis, acne conglobata or fulminans, and hidradenitis suppurativa. However, our patient had no skin lesion either in her history or during follow-up. Indeed, the symptoms and the findings of our patient were consistent with the GCA that could be associated with polyarthritis and sacroiliitis [17]. In the absence of dermatological involvement, the abnormal uptake in the bone scintigram was attributed to the GCA diagnosis that was confirmed histopathologically. Therefore, SAPHO syndrome as a diagnostic possibility was ruled out.

Since HFI is so common among postmenopausal women, the co-presence of HFI and GCA in our patient was considered not to be an association, but a coincidence

of these diseases (40–60%). The reasons for the delay in the accurate diagnosis were the attribution of the headache as the first complaint of the patient to HFI depending on the roentgenograms and the possible presentation of both HFI and GCA with this same complaint.

Conclusion

To our knowledge, there is no report in the literature regarding the association of HFI and GCA. According to us the association of the two diseases in our patient is a coincidence. But since both disorders may present with headache and are prevalent in the elderly population, the presence of persistent headache in a patient with HFI does not rule out the co-existence of GCA.

References

1. Armelagos G, Chrisman OD. Hyperostosis frontalis interna: a Nubian case. *Am J Phys Anthropol.* 1988;76:25–8.
2. Morgagni GB. *Adversaria anatomica.* Padua, 1719. (Francis A Coutway Library of Medicine, 1984).
3. She R, Szakacs J. Hyperostosis frontalis interna: case report and review of literature. *Ann Clin Lab Sci.* 2004;34:206–8.
4. Sohmiya M, Tanaka M, Sotomatsu A, Aihara Y, Okamoto K. Three elderly cases of hyperostosis cranii with various clinical symptoms (Japanese) *Nippon Ronen Igakkai Zasshi.* 2001;38:218–23.
5. Keltner JL. Giant cell arteritis: signs and symptoms. *Ophthalmology.* 1982;89:1101–10.
6. Horton BT. Headache and intermittent claudication of the jaw in temporal arteritis. *Headache.* 1962;2:29–40.
7. Goodman BW. Temporal arteritis. *Am J Med.* 1979;67:839–52.
8. Selsky II, Nirankari VS. Temporomandibular joint pain as a manifestation of temporal arteritis. *South Med J.* 1985;78:1249–51.
9. Hollenhorst RW, Brown JR, Wagener HP, Shick RM. Neurologic aspects of temporal arteritis. *Neurology.* 1960;10:490–8.
10. Jaffe HL. *Metabolic, degenerative, and inflammatory disease of bones and joints.* London: Henry Kimpton Pub; 1972. pp 272–7.
11. Gershon-Cohen J, Schraer H, Blumberg N. Hyperostosis frontalis interna among the aged. *Am J Roentgenol.* 1955;73:396–7.
12. Dann S. Metabolic craniopathy: a review of the literature with report of a case with diabetes mellitus. *Ann Intern Med.* 1951;34:163–202.
13. Moore MT. Metabolic craniopathy. *Am J Roentgenol.* 1944;35:30–9.
14. Salmi A, Voutilainen A, Holisti LR, Unnerus CE. Hyperostosis cranii in a normal population. *Am J Roentgenol.* 1962;87:1032–40.
15. Crispin JC, Alcocer-Varela J. Rheumatologic manifestations of diabetes mellitus. *Am J Med.* 2003;114:753–7.
16. Kahn MF, Kahn MA. The SAPHO syndrome. *Bailliers Clin Rheumatol.* 1994;8:333–62.
17. Carter JD, Vasey FB, Kanik KS, Valeriano-Marcet J. Polymyalgia rheumatica and temporal arteritis with sacroiliitis and osteitis pubis. *J Clin Rheumatol.* 2001;7:261–4.